

Original Research Article

Positive predictive value of pulse oximetry in the screening of critical congenital heart defects in term neonates

Krithika Damodar Shenoy*, Suchetha S. Rao

Department of Pediatrics, Kasturba Medical College, Manipal University Mangalore, India

Received: 29 March 2017

Accepted: 03 April 2017

*Correspondence:

Dr. Krithika Damodar Shenoy,
E-mail: krithi1993@gmail.com

Copyright: © the author(s), publisher and licensee Medip Academy. This is an open-access article distributed under the terms of the Creative Commons Attribution Non-Commercial License, which permits unrestricted non-commercial use, distribution, and reproduction in any medium, provided the original work is properly cited.

ABSTRACT

Background: Critical congenital heart defects (CCHD) are associated with poor patient outcome due to delay in diagnosis. Clinical examination alone has low positive predictive value (PPV). Pulse oximetry examination is suggested as supplemental screening tool. Aim of this study was to screen term neonates for CCHD by clinical and pulse oximetry evaluations and estimate their PPV separately and combined.

Methods: Cross-sectional study of 278 term neonates weighing ≥ 2500 g excluding those with antenatal diagnosis of congenital heart defects and/or requiring intensive care. Sample size calculated using EpiInfo version 7 taking 20,000 as population size, 7% expected frequency, 5% confidence limits and 99.9% confidence level. Ethical clearance and informed consent obtained. Clinical examination was performed within 24 hours of life followed by pre-ductal and post-ductal oxygen saturation (SpO₂) recording, using standardized hand-held probe, between 24-48 hours. Neonates categorized as screen positive or negative based on an adapted algorithm. Screen positives were confirmed by echocardiography. SPSS version 16 was used for statistical analysis.

Results: Mean age at clinical examination was 7.72 ± 0.32 hours during which none screened positive. Mean age at SpO₂ screening was 31.93 ± 0.32 hours and a single non-syndromic, acyanotic male newborn, weighing 2550g screened positive. He was found to have severe pulmonary outflow obstruction, with ductus-dependent flow on echocardiography. PPV for pulse oximetry screening alone was 100%.

Conclusions: Ductus dependent lesions missed on clinical examination may be picked up by pulse oximetry screening. Echocardiography may be used selectively to confirm diagnosis on screen positive.

Keywords: Ductus dependent flow, Echocardiogram, Pulmonary outflow obstruction

INTRODUCTION

Critical congenital heart defects (CCHD) are structural anomalies of the heart and its blood vessels that are present since birth and require surgical or transcatheter interventions in the first year of life for survival.¹ Advancements in screening and diagnostics has probably led to an increase in global prevalence from 0.6 per 1000 live births in the early 1930s to 9.1 per 1000 live births in 1995.² In India, the reported prevalence varies between 2.25 to 5.2 per 1000 live births and contributes to 10% of the present infant mortality rate.³ These defects are

associated with a rapid deterioration of clinical condition within the first few days to weeks of life when the normal physiological changes in pulmonary vascular resistance and closure of ductus arteriosus take place. Delay in diagnosis results in poor pre-operative condition due to cardiovascular compromise, multiple end-organ dysfunction or even death.⁴

Most neonates however are asymptomatic at birth and show no signs of disease till discharge from the hospital. Routine clinical examination at birth picks up <50% of the total number cases and has low sensitivity.⁵⁻⁸ Echocardiography, the gold standard, cannot be used as a

universal screening tool as it is expensive, yields high false-positive results and requires expertise for operation. Foetal echocardiography requires advanced skill and knowledge and is not routinely recommended to all expectant mothers at present.¹

In 2011, pulse oximetry screening for CCHD was included in the recommended uniform screening panel by the US Secretary of Health and Human Services.¹ It is still not recommended in the neonatal screening programme in our country.⁹ Hypoxemia is a common presentation of CCHD due to mixing of systemic and pulmonary circulations. Examination of arterial saturation of neonates performed 24 hours after birth has been shown to have a lower false positive rate for screening of CCHD, than when done before.¹⁰ A study in South India, reported high specificity of 88% for clinical examination and pulse oximetry combined but had a high false positive rate.⁶ The aim of this study was to screen term neonates for CCHD using postnatal clinical examination and pulse oximetry recording and calculate the positive predictive value (PPV) of each separately and combined.

METHODS

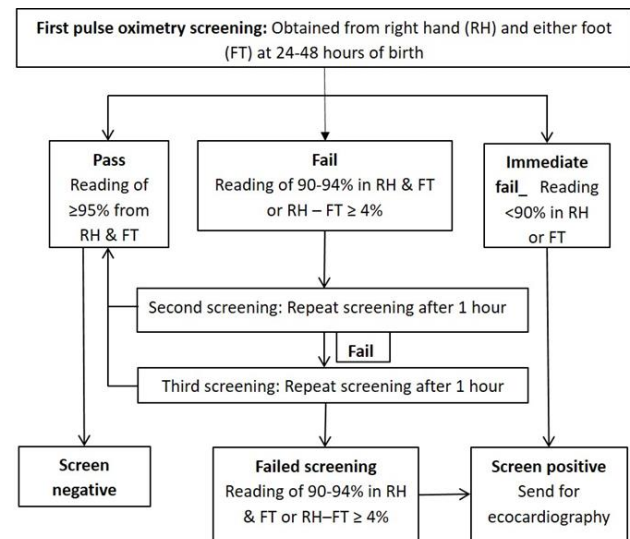
This cross-sectional study was carried out at the constituent hospitals of our medical college over a two-month period extending from 15 May-14 July 2015. The study included 278 term newborns weighing ≥ 2500 g at birth excluding those who were sick, requiring intensive care and/or with an antenatal diagnosis of congenital heart defects (CHD). Institutional Ethics Committee approval was obtained prior to commencement of the study. An informed consent was sought from either parent of all neonates who were included in the study.

Postnatal clinical examination and pulse oximetry screening

All neonates were clinically examined with the help of an on-site pediatrician within 24 hours of birth. The following clinical examination parameters were recorded in a structured proforma: heart rate, femoral and other peripheral pulses, apical impulse, thrills, heart sounds and murmurs. Oxygen saturation (SpO₂) reading from the right hand (pre-ductal) and either foot (post-ductal) were recorded in a calm, breastfed neonate in sequence using bedside SpO₂ Patient Monitoring System, PM100N, Nellcor™ between 24-48 hours after birth. The probe was cleaned with a cloth dampened with 70% isopropyl alcohol before each reading. The results were interpreted as per the algorithm adapted from the hospital guidelines for implementing pulse oximetry screening for congenital heart disease. Alabama Department of Public Health.¹¹ (Figure 1).

Neonates who had findings consistent with CHD on clinical examination and/or who screened positive on pulse oximetry examination were subjected to

echocardiography (8MHz, HD 7; Phillips) to confirm the diagnosis.



*Adapted from Hospital guidelines for implementing pulse oximetry screening for congenital heart disease. Alabama Department of Public Health. 2012:1-44.11

Figure 1: Algorithm for pulse oximetry screening in term newborns.

Sample size and statistical analysis

Sample size was calculated using EpiInfo version 7 taking 20,000 as population size, 7% expected frequency, 5% confidence limits and 99.9% confidence level. Software package SPSS version 16 was used for analysis. For non-parametric data, proportions were calculated and Chi-square was applied for significance; for parametric data mean was used and the values were expressed as 95% Confidence Interval (CI). The PPV of pulse oximetry and clinical examination for detection of CCHD was calculated using the formula,

$$\text{PPV (\%)} = \frac{\text{TP}}{\text{TP} + \text{FP}} \times 100$$

TP- True positive; FP- False positive.

RESULTS

Among those who were screened, 154 (55.4%) were male newborns. The mean gestational age of the study population was 38.36 ± 0.072 weeks and 117 (42.1%) were first born. None had a family history of congenital heart disease (CHD). Eight were born out of a consanguineous marriage. There were 29 (10.4%) mothers with associated illnesses during pregnancy with gestational diabetes mellitus (10; 34.48%), pre-eclampsia (10; 34.48%) and anemia (4; 13.79%) being the commonest. Mean age at first clinical examination was

7.72 \pm 0.32 hours after birth. The mean birth weight, length and head circumference were 2810 \pm 220 g, 48.38 \pm 0.12 cm and 32.80 \pm 0.13 cm with a standard deviation of 360 g, 1.79 cm and 2.14 cm respectively.

Postnatal clinical examination of all neonates in the study was unremarkable. The mean heart rate was 134.99 \pm 0.68 beats per minute. Femoral and other peripheral pulses were normal in all. None of the babies were cyanosed. The cardiovascular system examination showed no abnormalities. The mean age at first pulse oximetry screening was 31.93 \pm 0.32 hours during which 274 (98.6%) screened negative for disease. Pulse oximetry measurements were taken from the right hand and either foot of all the newborns in the study. Mean and standard deviations of pulse oximetry readings during the screening are shown in (Table 1).

Table 1: Mean and standard deviations (SD) of pulse oximetry screening.

	SpO ₂	Mean \pm SEM (%)	SD (%)
First Screening n = 278	Right hand	97.08 \pm 0.07	1.18
	Foot	97.03 \pm 0.075	1.24
Second Screening n = 3	Right hand	96 \pm 0.57	1.00
	Foot	94.67 \pm 1.86	3.22
Third Screening n = 1	Right hand	96	
	Foot	96	

Two infants (Baby A, Baby B) passed the second screening performed one hour after the first and one (baby C) passed the third screening performed two hours after the first. One newborn (baby X) immediately failed the first oximetry screening. The SpO₂ of neonates who did not pass the first recording has been tabulated (Table 2).

Table 2: SpO₂ recordings of babies who failed first pulse oximeter screening.

	Clinical parameters		
	First screening (%)	Second screening (%)	Third screening (%)
Baby A	93	96	
Baby B	93	97	
Baby C	92	RH – F = 4	96

RH: right hand; F: foot

Screen positive case

Baby X, a male newborn of birth order two, born out of a non-consanguineous marriage at 37 weeks' period of gestation with a birth weight of 2550 g. There was no history of maternal illness or teratogenic drug exposure during pregnancy or family history of CHD. On clinical examination at 7 hours after birth the heart rate was 126

beats per minute and respiratory rate of 56 breaths per minute. There was no cyanosis. Femoral and other peripheral pulses were well felt and equal on both sides. He did not show any features of dysmorphism. There were no thrills or cardiac murmurs. Pulse oximetry measurements at 28 hours of birth showed a reading of 87% in both right hand and either foot.

As per the screening algorithm the neonate immediately failed the pulse oximetry screening. He was shifted to the neonatal intensive care unit for observation and was subsequently diagnosed to have a common atrioventricular canal defect with severe pulmonary outflow obstruction, almost pulmonary atresia, with a ductus dependent flow on echocardiograph. The positive predictive value of pulse oximetry as a screening tool in our study was 100%.

DISCUSSION

In this study only term newborns were screened for CCHD by clinical examination at a mean duration of 7.72 \pm 0.32 hours combined with pulse oximeter screening at a mean age of 31.93 \pm 0.32 hours. Clinical examination for cyanosis, peripheral pulses, cardiomegaly, thrills and heart murmurs was unremarkable in all those who were screened. In a study by Vaidyanathan et al, 5487 neonates (term and pre-term) were screened, of which 425 (7.75%) were found to have a CHD. Major CHD was found in 17 (0.31%). Clinical examination was abnormal in 157 (2.9%), the most common abnormality being a cardiac murmur (84 patients, 1.6%).

However only 3 newborns with major and 32 with minor CHD had a positive clinical examination yielding a sensitivity of 13.3% and PPV of 1.1% for screening.⁸ Murmurs are not a feature of conditions such as tricuspid atresia and transposition of great vessels. On the other hand, flow murmurs, due to transitional circulation, may be a prominent feature of trivial tricuspid regurgitation and small ventricular septal defect. Ainsworth et al, in their study, concluded that detection of a murmur had a sensitivity of 44% with a positive predictive value of 54% for diagnosis.⁶

The neonate who failed the SpO₂ screening in our study and subsequently confirmed to have a common atrioventricular canal defect with pulmonary atresia, (with a ductus dependent flow) was not recognized by clinical examination. In newborns with right sided obstructive lesion, the ductus arteriosus is usually the only means by which blood reaches the lungs for oxygenation while in those with left sided obstructive lesion it may be the only means by which blood enters the systemic circulation.

Normally, the ductus arteriosus functionally closes at 10 to 15 hours after birth and pulmonary arterial pressure drops, while systemic arterial pressure rises. Clinical features largely depend on the relationship between

systemic and pulmonary vascular resistances. The ductus arteriosus is therefore extremely important in providing adequate systemic blood flow in several congenital cardiac anomalies.^{12,13} In a retrospective study by Mallender M and Sunnegardh J out of 259 term infants with CCHD, 235 had duct dependent lesion. Infants with duct dependent systemic circulation were more often missed by neonatal screening than those with duct dependent pulmonary circulation.¹⁴ In another study conducted in Sweden, 19/29 asymptomatic neonates with a duct dependent CCHD screened positive for disease by pulse oximetry alone. The screen negatives had mostly left sided obstructive lesions like coarctation of the aorta (with/without intact septum), interrupted aortic arch and aortic atresia.¹⁵

A study from a tertiary center in Boston screened 6838 term neonates and 99.5% passed the first SpO₂ screening. One infant who failed the test had persistent pulmonary hypertension on echocardiogram. There was one false-negative screening subsequently diagnosed as interrupted aortic arch.¹⁶

Early diagnosis is important especially in a ductus dependent cardiac condition as most of the peripheral centers in our country are not equipped to manage these neonates and require transport to a tertiary care center. A low SpO₂ at 24-48 hours of birth would promote an extensive clinical re-examination of the neonate and that, with follow up would help in deciding whether an echocardiogram is required in centers where it is not easily available. Ansari A in his review concludes that SpO₂ could be used to pick up a secondary target that is screening for non-cardiac conditions.¹⁷

Limitations

Limitations of the study was Sensitivity, specificity and negative predictive value could not be calculated since echocardiography could not be done for screen negatives.

CONCLUSION

- Diagnosis of certain congenital heart defects, predominantly ductus dependent lesions may be missed on newborn clinical examination or pulse oximetry screening when used alone.
- Pulse oximetry screening between 24 to 48 hours of birth may be used to supplement clinical examination.
- Echocardiography can be selectively performed on those who screen positive for disease on clinical examination and/or pulse oximetry to confirm the diagnosis.

ACKNOWLEDGEMENTS

Author would like to thank the Indian Council of Medical Research-Short Term Studentship Program 2015 for funding this study.

Funding: This study was funded by the Indian Council of Medical Research-Short Term Studentship 2015 (ICMR-STs 2015)

Conflict of interest: None declared

Ethical approval: The study was approved by the Institutional Ethics Committee

REFERENCES

1. Mahle WT, Newburger JW, Matheme GP, Smith FC, Hoke TR, Koppel R, et al. Role of pulse oximetry in examining newborns for congenital heart disease: a scientific statement from the AHA and AAP. *Circulation.* 2009;120:447-58.
2. Linde D, Konings EEM, Slager MA, Witsenburg M, Helbing WA, Takkenberg JJM, et al. Birth prevalence of congenital heart disease worldwide. A systematic review and meta-analysis. *J Am Coll Cardiol.* 2011;58(21):2241-7.
3. Saxena A. Congenital heart disease in India: A status report. *Indian J Pediatr.* 2005;72(7):595-8.
4. Swenson AK, Brown D, Stevermer JJ. Pulse oximetry for newborns: should it be routine? *J Fam Practice.* 2012;61(5):283-6.
5. Cartledge PHT. Routine discharge examination of babies: is it necessary? *Arch Dis Child.* 1992;67(12):1421-2.
6. Ainsworth SB, Wyllie JP, Wren C. Prevalence and clinical significance of cardiac murmurs in neonates. *Arch Dis Child Fetal Neonatal Ed.* 1999;80(1):43-5.
7. Richmond S, Reay G, Harb MA. Routine pulse oximetry in the asymptomatic newborn. *Arch Dis Child Fetal Neonatal Ed.* 2002;87:83-8.
8. Vaidyanathan B, Sathish G, Mohanan ST, Sundaram KR, Warriar KKR, Kumar RK. Clinical screening for congenital heart disease at birth: A prospective study in a community hospital in Kerala. *Indian Pediatr.* 2010;49:25-30.
9. Kumar RK. Screening for congenital heart disease in India: Rationale, practical challenges, and pragmatic strategies. *Ann Pediatr Cardiol.* 2016;9(2):111-4.
10. Thangaratinam S, Brown K, Zamora J, Khan KS, Ewer AK. Pulse oximetry screening for critical congenital heart defects in asymptomatic newborn babies: A systematic review and meta-analysis. *Lancet.* 2012;379:2459-64.
11. Hospital guidelines for implementing pulse oximetry screening for congenital heart disease. Alabama Department of Public Health; 2015.
12. Rudolph AM. The changes in the circulation after birth: Their importance in congenital heart disease. *Circulation.* 1970;41(2):343-59.
13. Yun SW. Congenital heart disease in the newborn requiring early intervention. *Korean J Pediatr.* 2011;54(5):183-91.
14. Mallender M, Sunnegardh J. Failure to diagnose critical heart malformations in newborns before

- discharge- an increasing problem? *Acta Paediatr* 2006;95(4):407-13.
15. de-Wahl Granelli A, Wennergren M, Sandberg K, Mellander M, Bejlum C, Inganas L et al. Impact of pulse oximetry screening on the detection of duct dependent congenital heart disease: a Swedish prospective screening study in 39821 newborns. *BMJ*. 2009;338:3037.
 16. Johnson LC, Lieberman E, O'Leary E, Geggel RL. Prenatal and newborn screening for critical congenital heart disease: Findings from a nursery. *Pediatr*. 2014;134(5):916-22.
 17. Ansary A. Pulse Oximetry Screening of Critical Congenital Heart Disease. *Indian Pediatr*. 2015;52:626.

Cite this article as: Shenoy KD, Rao SS. Positive predictive value of pulse oximetry in the screening of critical congenital heart defects in term neonates. *Int J Contemp Pediatr* 2017;4:832-6.