

## Case Report

# Bilateral spontaneous chylothorax in a newborn and response to octreotide therapy

Md. Nawad Azam\*, Subrat Kumar Majhi, Baikuntha Narayan Mishra,  
Ranjit Kumar Joshi, Prabin Prakash Pahi

Department of Pediatrics and Neonatology, AMRI Hospital, Bhubaneswar, Odisha, India

**Received:** 15 December 2016

**Accepted:** 16 January 2017

**\*Correspondence:**

Dr. Md. Nawad Azam,

E-mail: [dr.nawad2007@gmail.com](mailto:dr.nawad2007@gmail.com)

**Copyright:** © the author(s), publisher and licensee Medip Academy. This is an open-access article distributed under the terms of the Creative Commons Attribution Non-Commercial License, which permits unrestricted non-commercial use, distribution, and reproduction in any medium, provided the original work is properly cited.

### ABSTRACT

Chylothorax is an abnormal collection of milky white fluid called chyle in pleural space, and is an uncommon cause of respiratory distress in neonates. There is high morbidity and mortality, if not managed appropriately. Here we report a rare case of congenital bilateral chylothorax presented with respiratory distress in our NICU on day one of life. Thoracocentesis revealed chyle on both the sides. In view of high drainage of chylous fluid, besides TPN, Octreotide infusion started and the baby responded well.

**Keywords:** Chylothorax, Octreotide, Total parenteral nutrition

### INTRODUCTION

Chylothorax is defined as an abnormal accumulation of lymph in pleural cavity. Respiratory distress with pleural effusion is the commonest presentation. The incidence is about 1 in 10000 births. In about 90% cases it affects the right side. Radiological evidence of pleural effusion and aspiration of milky white fluid from pleural space, rich in triglyceride is diagnostic of chylothorax. It's a life-threatening condition with many respiratory, nutritional, immunological complications and the mortality rate is as high as 50%.<sup>1,2</sup>

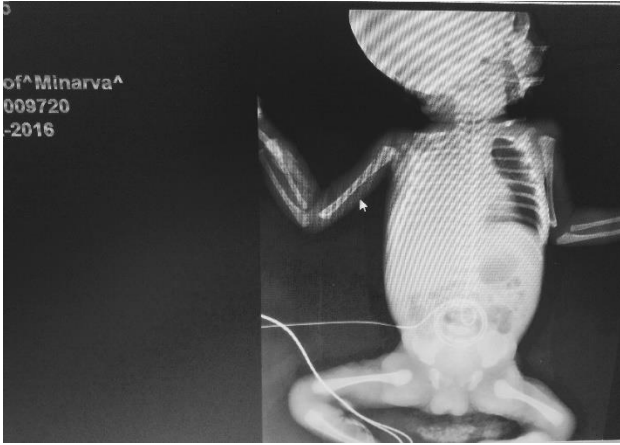
The management of such cases comprises of intercostal chest tube drainage, total parental nutrition, low or medium chain triglyceride and low fat high protein diets. Persistent Chylothorax beyond one month may require pleurodesis, pleuro-peritoneal shunt or ligation of thoracic duct.<sup>3</sup> But recently more conservative approach with Octreotide have yielded good results in traumatic and congenital chylothoraces.

Here in we report a case of congenital bilateral chylothorax, which was managed successfully with use of TPN and octreotide infusions.

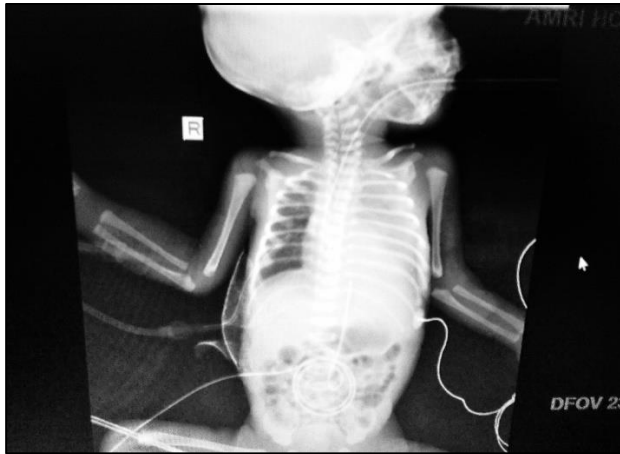
### CASE REPORT

A term female baby, delivered by LSCS for fetal distress, with birth weight of 1.25 kg (IUGR) developed respiratory distress soon after birth. She had tachypnea with hypoglycemia. There was no features of dysmorphism nor any evidence of tracheo-oesophageal fistula. She was ventilated on the second day of life due to intermittent bradycardia with increasing respiratory efforts. Chest X-ray was suggestive of right pleural effusion (Figure 1) and Ultrasound abdomen showed moderate ascites. Diagnostic thoracentesis revealed milky fluid. Aspirated fluid contained triglyceride 171 mg/dl, Cholesterol <50 mg/dl, protein <2 gm/dl and WBC 100 cells 75% neutrophil, 25% lymphocyte, sterile on culture. C-reactive protein was positive, viral serology showed detectable level of IgG antibody for toxoplasma, CMV, rubella. Cranial USG was normal and 2D ECHO

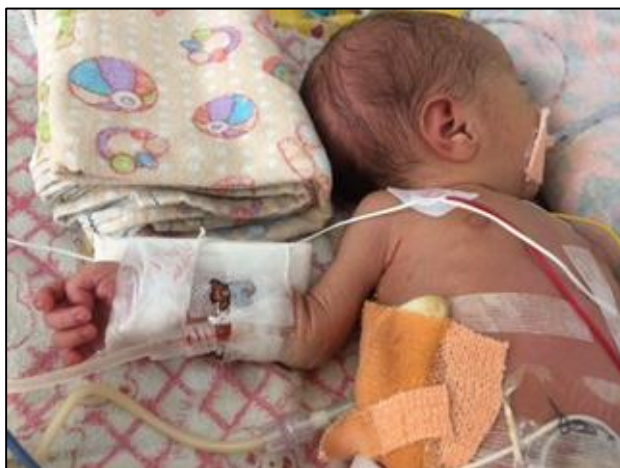suggestive of poor myocardial contractility without any PDA or other congenital malformation. Metabolic screening was also negative.



**Figure 1: CXR (AP view) showing Rt sided gross pleural effusion.**



**Figure 2: CXR (AP view) showing Lt sided gross pleural effusion.**



**Figure 3: Rt sided intercostal tube drainage showing Chyle.**

Baby was managed conservatively. With NPO, Broad spectrum antibiotics and TPN. Intercostal chest tube drain was put on right side and chyle drained though tube was averaged at 100ml/day for first 2 days. But baby developed respiratory acidosis with increased work of breathing on ventilator after two days. Repeat chest X-ray showed left sided pleural effusion (Figure 2) for which another intercostal tube was put on left thorax. The combined collection from both sides was around 250 ml/day. Since the drainage was high; Octreotide infusion was started @1 mic/kg/hr and gradually increased up to 4 mic/kg/hr over 3 days. There was remarkable decrease in chyle collection on day 3 of starting therapy. Due to improvement in respiratory parameters baby was gradually weaned off ventilator and extubated after 7 days of ventilation. As chyle loss decreased, Octreotide infusion was gradually tapered by 0.5 mic/kg/day and stopped after 8 days of therapy. During the period of octreotide therapy serum glucose, electrolytes were meticulously monitored. We didn't find any abnormalities in these parameters. Right intercostal chest tube was removed first followed by left after 11 days of therapy. Gradually feeds rich in medium chain triglyceride was initiated, baby tolerated well and was gaining weight at the time of discharge.

## DISCUSSION

Congenital chylothorax is rare and was first reported in 17th century.<sup>4</sup> It is a common cause of neonatal pleural effusion. Trauma and post cardiothoracic surgery are considered as cause, but in newborn, it is commonly associated with lymphatic malformation like lymphangiectasia, infections including congenital cytomegalovirus, adenovirus, streptococcus, congenital goiter, aneuploidy like Turner and Down syndrome, Noonan syndrome and malignancies.<sup>4,5</sup>

The characteristics of pleural chylous fluid are as follows: triglyceride >100 mg/dl, protein >20 g/L, cells>100 per ml with lymphocytosis, cholesterol 65-220 mg/dl. High triglyceride level and lower cholesterol level differentiate true chylothorax from pseudochylothorax.<sup>6</sup> Pleural fluid is sterile on culture. We had a similar finding.

Congenital chylothorax was associated with high morbidities and mortality (50%) particularly in preterm and low birth weight babies (2.7), few cases also show spontaneous resolution.<sup>7</sup>

There is no consensus on treatment approach to chylothorax but conservative management with infection control, nutritional and fluid electrolyte management and respiratory support are common mode of treatment. Surgical pleurodesis, ligation of thoracic duct should be performed in resistant cases with either excessively prolonged (>3 to 4 weeks) drainage or >10 ml/kg/day collection and recurrent chylothorax.<sup>8,9</sup> These procedures have their own complication and drawbacks as found in different studies.<sup>7,10</sup>

Currently a more conservative approach like octreotide infusion has seen some success in the treatment of chylothorax. Octreotide is a long acting analogue of somatostatin which is preferred in treating gastrointestinal bleeding, intractable secretory diarrhea, pancreatitis, metastatic carcinoid syndrome and vaso active peptide secreting tumor.<sup>11,12</sup> It is also used in persistent hypoglycemia caused by hyperinsulinemia in newborns.<sup>13</sup>

Mechanism of action of somatostatin in chylothorax is quite unclear. However, it has antisecretory action by mild splanchnic vasoconstriction and decreasing all gastro intestinal and pancreatic secretions with reduced intestinal absorption and hepatic venous flow. Octreotide is usually started with slow infusion @0.5 mcg/kg/hr to 1 mcg/kg/hr and gradually increased till desired effect. The usual dose range is from 0.2 mcg/kg/hr to 10 mcg/kg/hr.<sup>14</sup> Radly D et al in their review of neonatal chylothorax, have found median interval for maximum antisecretory effect is 3 days from starting therapy. Similar results were also reported by Tibbalis J et al.<sup>14,15</sup> The usual adverse effect of octreotide includes hyperglycemia / hypoglycemia, gall bladder sludge, cardiac conduction defect, hormone antagonism (cortisol, insulin, glucagon, Thyroxin etc.).<sup>16</sup> It is relatively free from side effects in neonates but needs caution in babies having NEC. Study did not come across any adverse effect of octreotide in our case.

Octreotide is a relatively safe drug with good efficacy in chylothorax cases in new born.

*Funding: No funding sources*

*Conflict of interest: None declared*

*Ethical approval: Not required*

## REFERENCES

1. Buettiker V, Hug MI, Burger R, Baenziger O. Somatostatin: a new therapeutic option for the treatment of chylothorax. *Intens Care Med.* 2001;27:1083-6.
2. Dubin PJ, King IN, Gallagher PG. Congenital Chylothorax. *Curr Opin Pediatr.* 2000;12:505-9.
3. Hesseling PB, Hoffman H. Chylothorax: a review of the literature and report of 3 cases. *S Afr Med.* 1981;60:675-8.
4. Avci A, Ulku R, Onat S. Chylothorax with Down syndrome: unusual case report. *J Intern Dent Med Res.* 2009;2:25-7.
5. Levine C. Primary disorders of the lymphatic vessels-a unified concept. *J Pediatr Surg.* 1989;24:233-40.
6. McGrath EE, Blades Z, Anderson PB. Chylothorax: aetiology, diagnosis and therapeutic options. *Resp Med.* 2010;104:1-8.
7. Sahin Y, Aydin D. Congenital chylothorax treated with octreotide. *Indian J Pediatr.* 2005;72(10):885-8.
8. Soto-Martinez M, Massie J. Chylothorax: diagnosis and management in children. *Paediatr Respir Rev.* 2009;10:199-207.
9. Teitelbaum DH, Teich S, Hirsch RB. Successful management of a chylothorax in infancy using a pleurectomy. *Pediatr Surg Int.* 1996;11:166-8.
10. Al-Tawil K, Ahmed G, Al-Hathal M, Al-Jarallah Y, Campbell N. Congenital chylothorax. *Am J Perinatol.* 2000;17:121-6.
11. Mulvihill S, Pappas TN, Passaro E, Debas HT. The use of somatostatin and its analogs in the treatment of surgical disorders. *Surg.* 1986;100:467-75.
12. Siafakas C, Fox VL, Nurko S. Use of octreotide for the treatment of severe gastrointestinal bleeding in children. *J Pediatr Gastroenterol Nutr.* 1998;26:356-9.
13. Glaser B, Hirsch HJ, Landau H. Persistent hyperinsulinemic hypoglycaemia of infancy: long-term octreotide treatment without pancreatectomy. *J Pediatr.* 1993;123:644-50.
14. Radly D, Sheila V, Rama B. Octreotide therapy for chylothorax in infants and children: a brief review. *Pediatr Crit Care Med.* 2008;7:576-9.
15. Tibbalis J, Soto R, Bharucha T. Management of newborn lymphangiectasia and chylothorax after cardiac surgery with octreotide infusion. *Ann Thoracic Surg.* 2004;77:2213-5.
16. Maayan-Metzger A, Sack J, Mazkereth R. Somatostatin treatment of congenital chylothorax may induce transient hypothyroidism in newborns. *Acta Paediatr.* 2005;94:785-9.

**Cite this article as:** Azam MN, Majhi SK, Mishra BN, Joshi RK, Pahi PP. Bilateral spontaneous chylothorax in a newborn and response to octreotide therapy. *Int J Contemp Pediatr* 2017;4:658-60.