

Case Report

Diagnosis of infantile hemangioendothelioma of the liver by triple phase computed tomography

Rahul Chopra^{1*}, Priya Arora², Rohtas K. Yadav¹

¹Department of Radiodiagnosis, Pandit Bhagwat Dayal Sharma Post Graduate Institute of Medical Sciences, Rohtak, Haryana, India

²Department of Physiology, Pandit Bhagwat Dayal Sharma Post Graduate Institute of Medical Sciences, Rohtak, Haryana, India

Received: 21 September 2014

Accepted: 13 October 2014

*Correspondence:

Dr. Rahul Chopra,

E-mail: talk2chopra@gmail.com

Copyright: © the author(s), publisher and licensee Medip Academy. This is an open-access article distributed under the terms of the Creative Commons Attribution Non-Commercial License, which permits unrestricted non-commercial use, distribution, and reproduction in any medium, provided the original work is properly cited.

ABSTRACT

We describe a case of a 9-month male infant who presented with abdominal lump, congestive cardiac failure and skin hemangiomas. Triple phase computed tomography (CT) showed multiple hypodense lesions of variable size in both lobes of the liver. Lesions showed peripheral enhancement in arterial phase and centripetal filling in portal venous phase. Lesions showed further centripetal progression of enhancement and enhanced uniformly in delayed phase. The diagnosis of infantile hemangioendothelioma (IHE) of the liver was suggested based on the typical triple phase CT imaging findings. This case is presented to emphasize the importance of the diagnosis of IHE of liver noninvasively by triple phase CT as needle biopsy is discouraged due to possible uncontrollable bleeding.

Keywords: Infantile hemangioendothelioma of liver, Triple phase, Computed tomography

INTRODUCTION

Infantile hemangioendothelioma (IHE) of the liver is the most common benign vascular neoplasm of liver in infants. Most lesions are asymptomatic, but some manifest as hepatomegaly, abdominal distension, a palpable upper abdominal mass, high output cardiac failure, or thrombocytopenia (consumptive coagulopathy - Kasabach-Merritt syndrome). For most patients, needle biopsy is discouraged due to possible uncontrollable bleeding. So computed tomography (CT) scan/magnetic resonance imaging (MRI) are used for diagnosis.¹ The disadvantages of MRI at present are its more limited availability, considerable expense and the length of the examination with most patients under 6-7 years requiring sedation or general anesthesia.

CASE REPORT

A 9-month male infant presented with abdominal lump, congestive cardiac failure and skin hemangiomas.

He had anemia with hemoglobin of 9 g/dl. Platelet count, liver function tests, serum bilirubin levels and serum alpha-fetoprotein were normal.

Ultrasonography (Figure 1) revealed multiple well-defined hypoechoic lesions in both lobes of the liver. On triple phase CT, lesions were multiple, involving both lobes of the liver. Lesions were variable in size with largest lesion measuring 3.5 cm × 3 cm. The lesions were hypodense on plain scan (Figure 2) with peripheral enhancement on arterial phase (Figure 3) and centripetal fill-in on portal venous phase (Figure 4). On delayed phase (Figure 5), there was further centripetal progression of enhancement and the lesions enhanced uniformly. The diagnosis of IHE of liver was suggested based on the typical triple phase CT imaging findings.

Biopsy was not done due to high vascularity of the lesions.

Prednisolone was started to accelerate the regression of liver lesions and anti-failure therapy (furosemide, digoxin,

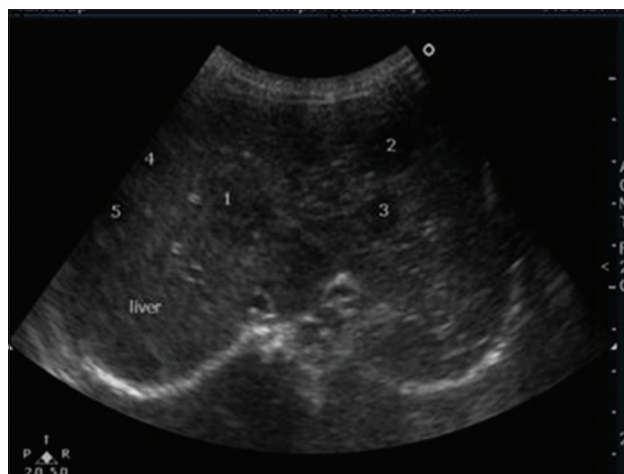


Figure 1: Infantile hemangioendothelioma of liver – Ultrasonography (USG). USG shows multiple well defined hypoechoic lesions in both lobes of liver.

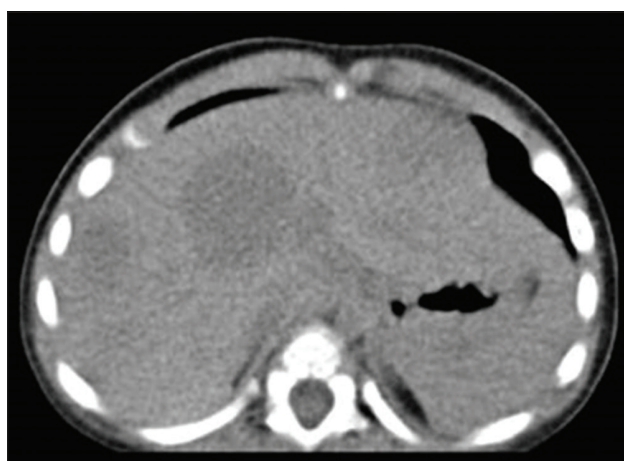


Figure 2: Infantile hemangioendothelioma of liver - Non contrast computerized tomography (NCCT). NCCT shows multiple well defined hypodense lesions in both lobes of liver.

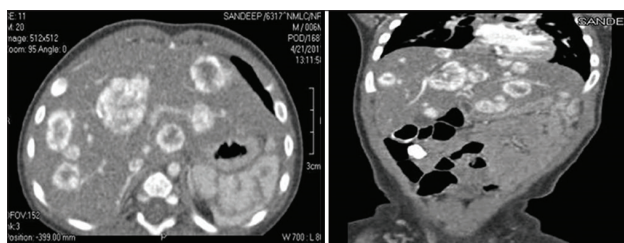


Figure 3: Infantile hemangioendothelioma of liver - Arterial phase. Lesions show peripheral enhancement in arterial phase.

propranolol) was initiated for cardiac failure, however the infant expired due to cardiac failure.

DISCUSSION

IHE of liver is the most common benign vascular neoplasm of liver in infants. IHE is a proliferative endothelial cell

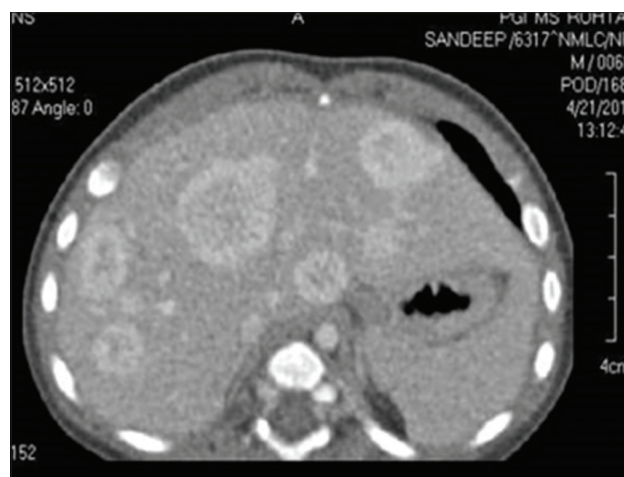


Figure 4: Infantile haemangioendothelioma of liver – Portal venous phase.

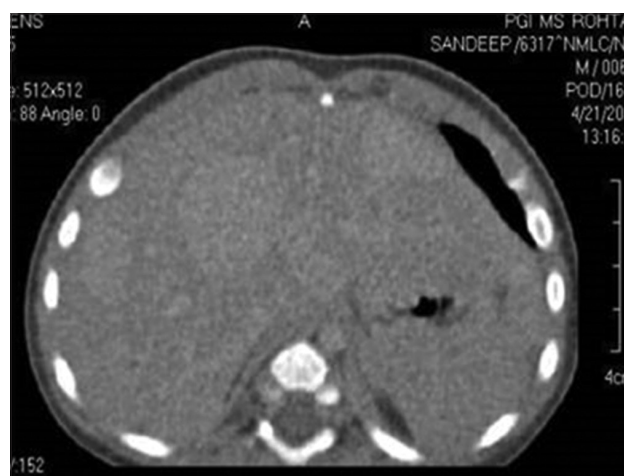

Figure 5: Infantile hemangioendothelioma of liver - Delayed phase. In delayed phase, lesions show further centripetal progression of enhancement and enhance uniformly.

neoplasm that involves the liver.¹ Approximately, 85% of affected patients present by 6 months of age,² however our patient presented at 9 months of age. In about 45-50% cases, these patients also have cutaneous hemangiomas. IHE has a female predilection (M:F=1:2),² however our patient was a male infant. Most lesions are asymptomatic and are incidentally discovered during imaging of the abdomen, but some manifest as hepatomegaly, abdominal distension, a palpable upper abdominal mass, high output cardiac failure, or thrombocytopenia (consumptive coagulopathy- Kasabach–Merritt syndrome).^{1,2} Our patient presented with abdominal lump, congestive cardiac failure and skin hemangiomas.

IHE may occur as a solitary lesion or multifocal nodules ranging in size from few mm up to 15 cm. Kassarian et al.,¹ Chung et al.³ and Jabra et al.⁴ have described that CT findings of IHE are dependent on the timing of the scan relative to the administration of contrast medium. On non-contrast scan lesion/s appear hypodense compared

with the liver. In arterial phase, lesion/s show peripheral enhancement with centripetal fill-in on portal venous phase. On delayed scan, the entire lesion enhances uniformly. Similar imaging findings were seen in our case.

For most patients, needle biopsy is discouraged due to possible uncontrollable bleeding, so CT scan and MRI are used for diagnosis.¹

About 70% tumors regress spontaneously within the first 12-18 months of life. About 30% need urgent management because of life threatening complications as cardiac failure, hepatic failure or tumor rupture.

Treatment includes corticosteroids/interferons to accelerate the regression of the lesion/s and anti-failure therapy for patients with cardiac failure. Transcatheter hepatic artery embolization and liver transplantation are other treatment options.¹

CONCLUSION

Diagnosis of IHE of liver can be made noninvasively by triple phase CT. About 70% tumors regress spontaneously within the first 12-18 months of life. About 30% need urgent management because of life-threatening complications as cardiac failure, hepatic failure or tumor rupture. Treatment options are corticosteroids/interferons, transcatheter hepatic artery embolization and liver transplantation.

Funding: No funding sources

Conflict of interest: None declared

Ethical approval: Not required

REFERENCES

1. Kassarian A, Zurakowski D, Dubois J, Paltiel HJ, Fishman SJ, Burrows PE. Infantile hepatic hemangiomas: clinical and imaging findings and their correlation with therapy. *AJR Am J Roentgenol*. 2004;182(3):785-95.
2. Roos JE, Pfiffner R, Stallmach T, Stuckmann G, Marincek B, Willi U. Infantile hemangioendothelioma. *Radiographics*. 2003;23(6):1649-55.
3. Chung EM, Cube R, Lewis RB, Conran RM. From the archives of the AFIP: Pediatric liver masses: radiologic-pathologic correlation part 1. Benign tumors. *Radiographics*. 2010;30(3):801-26.
4. Jabra AA, Fishman EK, Taylor GA. Hepatic masses in infants and children: CT evaluation. *AJR Am J Roentgenol*. 1992;158(1):143-9.

DOI: 10.5455/2349-3291.ijcp20141113

Cite this article as: Chopra R, Arora P, Yadav RK. Diagnosis of infantile haemangioendothelioma of liver by triple phase computed tomography. *Int J Contemp Pediatr* 2014;1:184-6.