

Research Article

Effect of anterior chest wall myofascial release on thoracic expansion in children with spastic cerebral palsy

Shraddha J. Diwan*, Ankita B. Bansal, Hetal Chovatiya, Dhara Kotak, Neeta Vyas

S.B.B. College of Physiotherapy, V.S. General Hospital, Ellis Bridge, Ahmedabad-380006, Gujarat, India

Received: 29 April 2014

Accepted: 9 May 2014

*Correspondence:

Dr. Shraddha J. Diwan,

E-mail: shraddhajadav@yahoo.com

© 2014 Diwan SJ et al. This is an open-access article distributed under the terms of the Creative Commons Attribution Non-Commercial License, which permits unrestricted non-commercial use, distribution, and reproduction in any medium, provided the original work is properly cited.

ABSTRACT

Background: Cerebral Palsy is primarily disorder of development of movement and posture attributed to damage to fetal brain. Children with spastic cerebral palsy are found with decreased chest mobility. Myofascial Release (MFR) is a form of soft tissue therapy used to treat somatic dysfunction and accompanying pain and restriction of motion. Hence some intervention is required to improve chest expansion. So this study was conducted in an effort to improve the chest expansion using MFR techniques to the respiratory muscles.

Methods: 12 spastic cerebral palsy children of both genders satisfying inclusion criteria were included for the study. The chest measurements were taken at three levels at axilla, 3 fingers below xiphoid process, and subcostally. These readings were documented as pre-test score. Myofascial release was given to the pectoralis major, intercostals, rectus abdominis and the diaphragm, with the subject in supine position. Post treatment data was taken and statistical analysis was performed.

Results: The difference of the pre and post readings of the expansion at the axilla, xiphoid and subcostal shows a mean difference of 0.15, 0.15, 0.20 respectively which is significant statistically, P value being <0.05.

Conclusion: The result shows that the chest expansion increased significantly at all the three levels. The expansion improved maximally at the nipple level.

Keywords: Spastic cerebral palsy, Myofascial release, Chest expansion

INTRODUCTION

Cerebral Palsy (CP) describes a group of disorders of the development of movement and posture, causing activity limitations that are attributed to non-progressive disturbances that occurred in developing fetal or infant brain. The motor disorders of cerebral palsy are often accompanied by disturbances of sensation, cognition, communication, perception and/or behavior and/or a seizure disorders.¹

Cerebral palsy is the most common cause of severe physical disability in childhood.² Although CP is non-

progressive disease in itself, its motor manifestation often changes due to abnormal tone & overactive muscles that can lead to muscle contractures which in turn, can lead to changes in skeletal alignment during growth. The motor manifestations typically involve a variety of neuromuscular & musculoskeletal problem. These problems include spasticity, dystonia, contractures, abnormal bone growth, poor balance, loss of selective motor control & muscles weakness.¹

The incidence of cerebral palsy is up to 3 cases per 1000 live births. There are an estimated over 25 lakh children & people in India with cerebral palsy. This statistics are

as per registration of birth/death of children only but in remote villages it is unclear about this registration.² Spastic cerebral palsy is one of the most common type. Spasticity occurs as a result of a loss of upper motor neuron inhibition on the lower motor neurons which results in increased or impaired motor unit firing and altered muscle tone. Adding to these neurological symptoms, skeletal muscle morphology in children with cerebral palsy is also altered due to abnormally long muscle sarcomere lengths and muscle tissue containing a hypertrophic extracellular matrix of poor quality.³⁻⁵ This results in muscle stiffness affecting posture and movement and can be described as hypertonia or increased muscle tone.⁴ Management of long-term disability and the burden of care on both the health care system and families are substantial.

Respiratory system muscles which support the posture and movements are usually compromised in a child with Spastic cerebral palsy and they suffer from a high incidence of respiratory dysfunction such as recurrent pneumonia, atelectasis, bronchiectasis, sleep apnea, chronic obstructive lung disease, and restrictive lung disease. A number of these conditions are secondary and develop over time or due to failure of development of more mature respiratory pattern from the infant belly breathers. Eun Sook 2006 stated that respiratory dysfunction is known to be a leading cause of death among individuals with CP.⁶

It has been reported that children with spastic cerebral palsy has decreased chest mobility. This inefficient chest mobility is reported due to various secondary factors like over activity of trunk muscles like intercostals, diaphragm and rectus abdominis, barrel shaped chest, inefficient stabilization by abdominals. Along with this there occurs adaptive soft tissue tightness or shortening at the chest wall in response to the altered position of the chest (e.g. barrel shaped chest). Added to the inefficient expansion mechanism of the chest, this tightness of the muscles, fascia and the skin overlying the chest reduces the overall excursion of the chest thus all the more reduced expansion of the chest.⁷

The physiotherapist working with cerebral palsy children should identify these secondary problems and treat it in order to help the children achieve functions that are not likely to develop if left untreated.

Myofascial release therapy is classified as a clinical massage technique, meaning that it uses focused manipulation of the muscle or surrounding fascia as well as other bodily systems. This form of massage is used to relieve pain and decrease restricted movement by attempting to release muscle spasms, strengthen/stretch specific muscles, and remodel fascial structures.⁸ The theory of myofascial release is based on the principle that physical trauma, inflammation, infection, and structural imbalances may create inappropriate fascial strain.⁹ Sustained traction or tension on this fascia may cause

varying degrees of fascial entrapment of neural structures, thereby causing a myriad of dysfunctions and symptoms.¹⁰ If fascial strain persists over time, this strain results in exertion forces that pull the body out of its Three dimensional alignment with the vertical gravitational axis. Myofascial release has been used more extensively in adults than in children in the published literature. For example, Barnes et al. used myofascial release treatments in adults in an attempt to restore pelvic symmetry, and their results indicated that this therapy had the potential to be effective in facilitating a change in pelvic position toward symmetry.¹¹ Schleip described the intimate relationship between fascia and the autonomic nervous system, suggesting that stimulation of mechanoreceptors responsive to manual pressure lowered sympathetic tonus resulting in decreased spasticity.¹²

Few studies has been reported regarding the effect of MFR on spastic muscles in cerebral palsy those which were reported were mainly done for mobility and were for calf muscles. As respiratory dysfunction is leading cause of mortality and morbidity in CP, this study aims to see the effect of anterior wall myofascial release on thoracic expansion in children with spastic cerebral palsy.

METHODS

Children with spastic cerebral palsy coming to OPD of pediatric department of SBB College of physiotherapy, V.S. general hospital, Ahmedabad, Gujarat were screened for study. Study is non-blinded quasi experimental study 12 children with both genders according to convenient sampling, those who were following into inclusion criteria were recruited for the study. Children with confirmed diagnosis of spastic hemiplegic CP, spastic quadriplegic CP, spastic dystonic CP, and spastic diplegic CP were included in the study. Children with hypotonic CP, Down's syndrome, and those who have surgical incision and have undergone surgery prior to 6 month before study entry were excluded. Nature and purpose of the study was explained to parents and oral consent was taken from parent or legal caregiver.

The children were taken in supine position on the mat/plinth and were made to relax. Then command was given to exhale as much as possible and hold the position to take the chest circumference at the maximal voluntary expiration. This was followed by deep breath as much as possible and was held for chest circumference at the maximal voluntary inspiration with the help of measure tape. Chest expansion were taken at 3 levels: at axilla, 3 fingers below the xiphoid process (9th rib), and subcostally. Chest expansion was taken before intervention, were used as baseline scores at all three levels. Myofascial Release was given to anterior chest wall: diaphragm, rectus abdominis, pectoralis major, intercostals were given for 5 days a week for a month. Post treatment data was taken and statistical analysis was performed.

Techniques of MFR

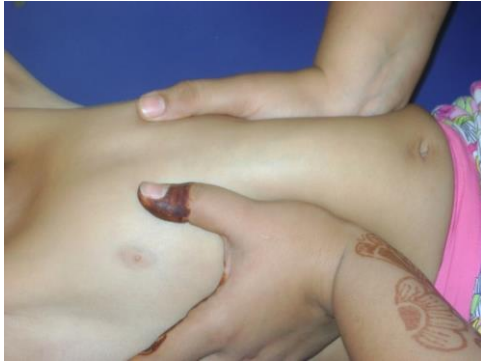

Figure 1: MFR to intercostals.

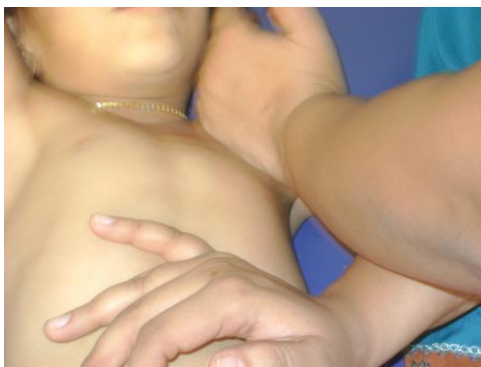

Figure 2: MFR to pectoralis major.

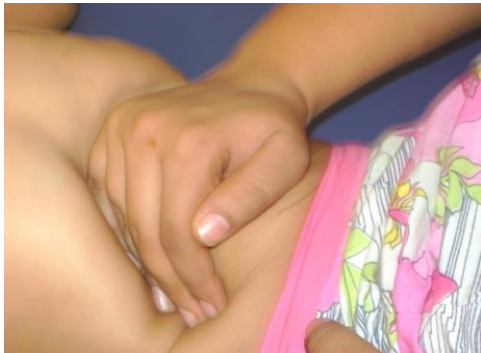

Figure 3: MFR to diaphragm.

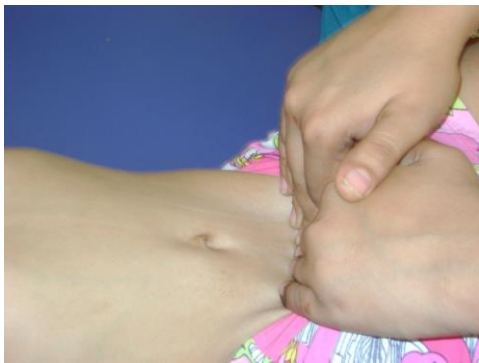

Figure 4: MFR to rectus abdominus.

RESULTS

Data analysis was done using SPSS version 16.0. Within group analysis was done using baseline outcome measures taken before the intervention and outcome measures taken after intervention i.e. after 1 month. Level of significance was kept at 5% with confidence interval (CI) at 95%.

The difference of the pre and post readings of the expansion at the axilla level shows a mean difference of 0.15 which is significant, P value being <0.05 . The difference of the pre and post readings of the chest expansion at 3 fingers below xiphoid process shows a significant difference, the difference with mean of 0.15 and the P value <0.05 . Similarly the difference of the readings at the subcostal level is significant, with mean of 0.20 and P value being <0.05 . Thus the result shows that the chest expansion shows significant difference at all the three levels. The expansion improved maximally at the subcostal level.

Table 1: Chest expansion (CE) at 3 levels.

CE at 3 levels	Pre treatment Mean \pm SD	Post treatment Mean \pm SD	W value	P value
At axilla	0.35 \pm 0.12	0.51 \pm 0.11	-3.126	0.02
3 fingers below xiphoid	0.35 \pm 0.12	0.51 \pm 0.11	-3.126	0.02
Subcostally	0.42 \pm 0.12	0.62 \pm 0.14	-3.093	0.02

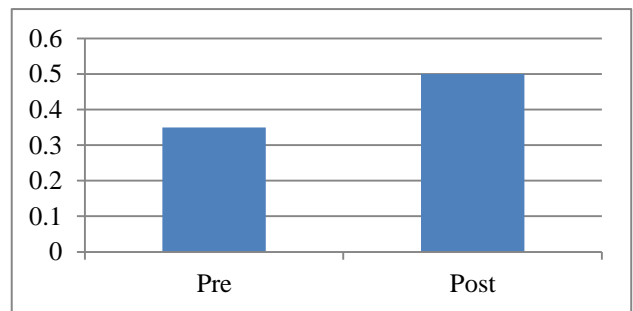


Figure 5: Mean values within group at axilla.

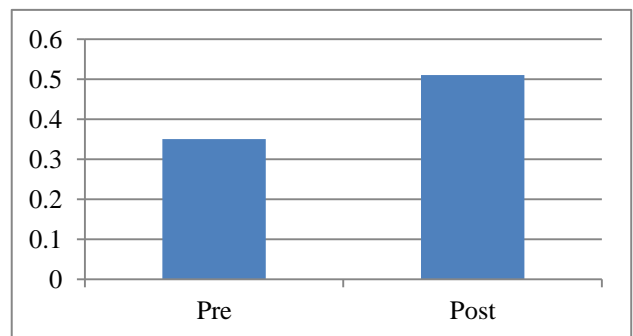


Figure 6: Mean values within group at 3 fingers below xiphoid process.

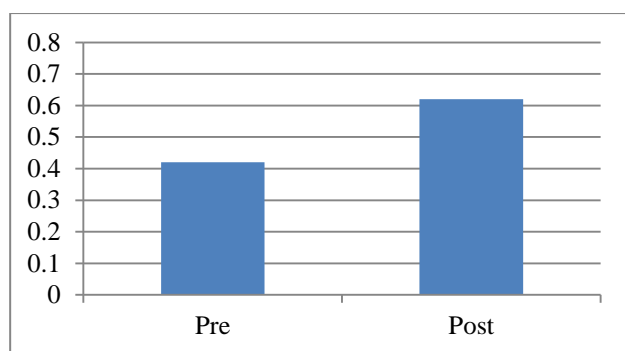


Figure 7: Mean values within group subcostally.

DISCUSSION

The present study showed the effect of anterior chest wall myofascial release on thoracic expansion at all three levels maximally subcostally when applied for diaphragm, pectoralis major, intercostals, rectus abdominus. The chest wall plays a dual role as a scaffold and a pump for the respiratory system. Normal respiratory function requires a scaffolding structure that allows adequate mobility and girth for lung expansion. For optimal pump function, the scaffolding needs to be rigid enough to withstand the distorting force of the inward lung recoil but not so rigid as to impede ventilation. Deviation from the optimal chest wall structure can result in respiratory dysfunction;¹³ however, there have been few studies on the clinical implications of developmental abnormalities of the chest wall.

People of all ages take deep breaths or sigh regularly, and, of course, infants cry. These actions stretch the respiratory structures. Children with CP, particularly quadriplegic CP, breathe in a poorly coordinated fashion, relying on the abdominal muscles instead of the chest muscles.¹⁴ eventually, chest movement is restricted and the chest muscles weaken. As a result, the ability to take a large breath is impaired.¹⁵⁻¹⁶ The shallow and low breathing volume in severe CP leads to the development of widespread microatelectasis and a decrease in lung distensibility.¹⁷ In particular, CP can lead to underdevelopment of the lung tissues and an alteration in chest wall development in children who are not fully grown.¹⁸⁻¹⁹

As CP does not have articular involvement, the limited chest mobility may be attributed to impaired neuromotor control and incoordination, weakness, spasticity and secondary changes in the respiratory muscles. The rib cage is either barrel shaped with excessive sustained superficial muscle activity or is flattened with distal rib flaring. The shape of rib cage changes due to over activity of the trunk muscles, including intercostals, diaphragm and rectus abdominis. This results in shallow respiration with an immobile rib cage during inhalation and exhalation. As in the patients of Spastic cerebral palsy, the stabilization of the rib cage is not proper so with each respiration there occurs flaring of the lower

ribs, which should otherwise be fixated by abdominals so as to provide diaphragm with a stable base to contract upon. A disturbance in this synergy causes the whole process to become inefficient. Along with this there occurs adaptive soft tissue tightness or shortening at the chest wall in response to the altered position of the chest (e.g. barrel shaped chest). Added to the inefficient expansion mechanism of the chest, this tightness of the muscles, fascia and the skin overlying the chest reduces the overall excursion of the chest thus all the more reduced expansion of the chest.²⁰

Body fascia composed of collagen tissue and elastic fibres may be regarded as a continuous laminated sheet of connective tissue that extends without interruption from the top of the head to the tip of the toes. Each time when there is a trauma, or an inflammatory process or poor postures over time, the fascial system becomes restricted. These restrictions act like the concentric layers of an onion. These adaptive layers slowly tighten and lead to loss of physiologic adaptive capacity and begin to pull out of three-dimensional orientation with gravity. This is fascial sweater concept which states that fascial restriction in one area will strain areas away from the restriction and cause abnormal movement patterns. Thus the tight myofascia should be stretched to its normal length.²¹⁻²²

Fascia has been viewed clinically as a potential source of dysfunction. As several muscles are connected through the same fascia, myofascial chains may contain restrictions and dysfunction in one area that influence a remote area. Because of its lack of extensibility and its intimate relationship with the muscular system, fascia may limit free movement of joints, facilitating further dysfunction (Lewit 2007). These fascial layers help connect muscle throughout the region, creating myofascial chains. The abdominal fascia attaches to the external oblique, internal oblique, TrA, pectoralis major, and serratus anterior. It contains the links that form the diagonal musclesling among the external oblique, pectoralis major, and serratus anterior.

Myofascial release is to release fascial restriction and restore its tissue so as to aid normal mechanics and functions. This technique is used to ease pressure in the fibrous bands of the connective tissue, or fascia by application of sustained pressure and gliding techniques.²³ Significant loss of ground substance is reported to occur due to immobilization. One of the primary functions of ground substance is to lubricate the area between adjacent collagen fibers. Collagen fiber lubrication is associated with the maintenance of the critical interfiber distance. This is the distance that must be maintained between collagen fibers to allow them to glide smoothly and to prevent micro adhesions between fibers. When the critical interfiber distance is not maintained, due to decreased or no mobility, then the collagen fibers approximate and eventually become cross linked by newly synthesized collagen. The newly

synthesized collagen then binds to the adjacent collagen fibers, decreasing the extensibility of the tissue.²² Researchers have identified the involvement of interstitial muscle receptors in fine tuning of the blood flow. When myofascial release is given, the interstitial fiber signals the blood vessels which increases the renewal speed of the ground substance i.e. extrusion of the plasma from the blood vessels into the interstitial fluid matrix. This in turn causes hydration of the ground substance thus lubricating the space between the fibers and maintaining the inter-fiber distance.²⁴ Gentle and sustained stretching of myofascial release frees the adhesions and softens and lengthens the fascia. The effects are because of the force applied in a particular direction which is against the lines of fascial restriction. As the neuromotor system is released from dysfunction via myofascial release, the fascia is stressed by appropriate and orderly movement causing the collagen to lay down in the direction of the stress. A combination of increased level of ground substance with more orderly arrangement of the fibers therefore causes break down of the cross linkage and increases the extensibility of the muscle thus improving the chest expansion.²²

Thus as due to myofascial release muscular restriction were released, neural mobility and synergy was improved, chest expansion was increased after anterior wall myofascial release.

CONCLUSION

There was effect of anterior chest wall myofascial release on thoracic expansion at all 3 levels maximally occurring at subcostal level. Henceforth, clinicians should use myofascial manipulation in treatment of respiratory problems and should take secondary impairments due to respiratory dysfunction into consideration in spastic CP. This study was limited in no of factors as sample size was too small, randomization was not done, control group was taken to rule out other extraneous variables, and other reliable measures to evaluate chest mobility should be taken into consideration.

ACKNOWLEDGEMENTS

Authors are grateful to the authors / editors / publishers of all those articles, journals and books from where the literature for this article has been reviewed. Authors want to express deep sense of gratitude to all the subjects and their parents who participated in the study and spent their valuable time. Authors are thankful to staff members of SBB College of physiotherapy for their assistance in carrying out this study.

Funding: No funding sources

Conflict of interest: None declared

Ethical approval: Not required

REFERENCES

1. Rosenbaum P, Paneth N, Leviton A. A report: the definition and classification of cerebral palsy April 2006. *Develop Med Child Neurol.* 2007;109:8-14.
2. Stanley FJ. Cerebral palsies: epidemiology and causal pathways. In: Stanley FJ, Blair E, Alberman E, eds. *Clinics in Developmental Medicine* No. 151. London: MacKeith Press; 2000: 22-39.
3. Smith LR, Ponten E, Hedstrom Y. Novel transcriptional profile in wrist muscles from cerebral palsy patients. *Biomed Cent Med Genom.* 2009;2(1):44.
4. Lance JW. Symposium synopsis. In: Feldmann RG, Young RR, Koella WP, eds. *Spasticity: Disordered Motor Control.* 2nd ed. Chicago: Year Book Medical Publishers; 1980:485-95.
5. Lieber RL. Spasticity causes a fundamental rearrangement of muscle-joint interaction. *Muscle and Nerve.* 2002;25(2):265-70.
6. Eun Sook Park, Jung Hyun Park, Dong-Wook Rha, Chang Il Park, Chan Woo Park. Comparison of the ratio of upper to lower chest wall in children with spastic quadriplegic cerebral palsy and normally developed children; *Yonsei Med J.* 2006;47(2):237-42.
7. Ersoz M, Selçuk B, Gündüz R, Kurtaran A, Akyüz M. Decreased chest mobility in children with spastic cerebral palsy. *Turk J Pediatr.* 2006;48(4):344-50.
8. Sherman KJ, Dixon MW, Thompson D, Cherkin DC. Development of taxonomy to describe massage treatments for musculoskeletal pain. *BMC Complement Altern Med.* 2006;6:24.
9. Barnes J. Myofascial Release: the missing link in traditional treatment. In: Davis CM, eds. *Complimentary Therapies in Rehabilitation: Holistic Approaches for Prevention and Wellness.* 2nd ed. Thorofare, NJ: Slack Inc; 2004: 59-81.
10. Cathie A. Selected writings. In: Cathie A, eds. *Academy of Applied Osteopathy.* 2nd ed. Maidstone, England: Academy of Applied Osteopathy Yearbook; 1974: 15-126.
11. Barnes MF, Gronlund RT, Little MF, Personius WJ. Efficacy study of the effect of a myofascial release treatment technique on obtaining pelvic symmetry. *J Bodywork Mov Ther.* 1997;1:289-96.
12. Schleip R. Fascial plasticity-a new neurobiological explanation: part 1. *J Bodywork Mov Ther.* 2003;7:11-9.
13. Papastamelos C, Panitch HB, England SE, Allen JL. Developmental changes in chest wall compliance in infancy and early childhood. *J Appl Physiol.* 1995;78:179-84.
14. Benditt JO. Management of pulmonary complications in neuromuscular disease. *Phys Med Rehabil Clin North Am.* 1998;9:167-85.
15. Redstone F. The effects of seating position on the respiratory patterns of pre-schoolers with cerebral palsy. *Int J Rehabil Res.* 2004;27:283-8.

16. Muller H. Speech. In: Finnie NR, eds. *Handling the Young Child with Cerebral Palsy at Home*. 3rd ed. Oxford: Butterworth-Heinemann; 1997: 112-117.
17. Stamer MH. Posture and movement of the child with cerebral palsy. In: Stamer MH, eds. *Congenital Hemiplegia*. 2nd ed. San Antonio, Texas: Therapy Skill Builders; 2000: 79.
18. Leopando MT, Moussavi Z, Holbrow J, Chernick V, Pasterkamp H, Rempel G. Effect of a soft Boston orthosis on pulmonary mechanics in severe cerebral palsy. *Pediatr Pulmonol.* 1999;28:53-8.
19. Bach JR, Bianchi C. Prevention of pectus excavatum for children with spinal muscular atrophy type 1. *Am J Phys Med Rehabil* 2003;82:815-9.
20. Stamer MH. Posture and movement of the child with cerebral palsy. In: Stamer MH, eds. *Congenital Hemiplegia*. 1st ed. San Antonio, Texas: Therapy Skill Builder; 2000: 9-16.
21. Manhein CJ. The myofascial release. In: Manhein CJ, eds. *Manual*. 3rd ed. Thorofare, NJ: Slack Publications; 2001: 1-36, 123-131, 180-185.
22. Cantu RI, Grodin AJ. Myofascial manipulation: theory and clinical application. In: Cantu RI, Grodin AJ., eds. *Aspen Book*. 2nd ed. Maryland: Aspen publication; 2001: 15-90.
23. Suman Kuhar, Khatri Subhash, Jeba Chitra. Effectiveness of myofascial release in treatment of plantar fasciitis: a RCT. *Indian J Physiother Occupat Ther.* 2007 July-Sept;1(3):3-9.
24. Michael Stanborough. Direct release myofascial technique. In: Michael Stanborough, eds. *Book Manual*. 3rd ed. United States: Elsevier Publishers; 2001: 3-23.

DOI: 10.5455/2349-3291.ijcp20140802

Cite this article as: Diwan SJ, Bansal AB, Chovatiya H, Kotak D, Vyas N. Effect of anterior chest wall myofascial release on thoracic expansion in children with spastic cerebral palsy. *Int J Contemp Pediatr* 2014;1:94-9.