

Case Report

Extrarenal nephroblastoma in a 7 year old child: a rare case report with review of literature

Sasi Kumar¹, Menon Narayanankutty Sunilkumar^{2*}, Divya Surendran³

¹Department of Paediatric Surgery, Amala Institute of Medical Sciences, Amala Nagar, Thrissur-680555, Kerala, India

²Department of Paediatrics, Amala Institute of Medical Sciences, Amala Nagar, Thrissur-680555, Kerala, India

³Department of Pathology, Amala Institute of Medical Sciences, Amala Nagar, Thrissur-680555, Kerala, India

Received: 11 February 2015

Revised: 04 March 2015

Accepted: 21 March 2015

*Correspondence:

Dr. Menon Narayanankutty Sunilkumar,
E-mail: sunilsree99@gmail.com

Copyright: © the author(s), publisher and licensee Medip Academy. This is an open-access article distributed under the terms of the Creative Commons Attribution Non-Commercial License, which permits unrestricted non-commercial use, distribution, and reproduction in any medium, provided the original work is properly cited.

ABSTRACT

Nephroblastoma or Wilms' tumors are a tumour of the kidney and is the commonest primary malignant tumour occurring in childhood with classic histopathological features. Majority of these tumors present as renal masses and atypical presentations like extrarenal masses have also been known. Extrarenal Wilms' tumor or Nephroblastoma (ERWT), excludes primary tumor in the kidney, is extremely rare and occurs predominantly in children. Most of the cases that have been reported involved the retroperitoneum. It is generally located anywhere in the retroperitoneum from the nephric region down through lumbar, iliac, pelvic region to inguinal canal. Though there are reports regarding its prevalence, its occurrence is very rare in childhood. We are reporting a case of ERWT in a 7 year old child arising from the retroperitoneum, adherent to the ascending colon, second and third part of duodenum, right kidney and ureter.

Keywords: Retroperitoneum, Extrarenal Wilms' tumor or Nephroblastoma, Intrarenal Wilms' tumor

INTRODUCTION

Retroperitoneal teratomas are uncommon germ cell cases.^{1,2} Occurrence of extrarenal Wilms' tumour (ERWT) is very exceptional and the diagnosis is almost always made after surgical intervention. The tumor can be located in the retroperitoneum, uterus, cervix, testes, skin and even in the thorax.³ The exact mechanism whereby a Wilms' Tumour (WT) occurs in extrarenal tissues is not known.⁴ Even if the histological characteristics are the same as in intrarenal WT, a retroperitoneal teratoma should be investigated for a possible admixture of WT cells.^{5,6} Age of presentation is reported to be between 2 months to 10 years. The oldest recorded patient suffering from uterine ERWT was a 77 years old female.⁷ In this case study, we report a case of ERWT in a 7-year-old girl.

CASE REPORT

A 7-year-old girl was brought with complaints of recently noticing swelling in the right side of abdomen of 1 week duration. Child was asymptomatic till then. According to the parents she had a fall at home while she was playing and subsequently swelling appeared. History taken did not reveal any abdominal pain, weight loss, and loss of appetite, fever or any other diseases. There was also no history of passing blood in stool and urine. The child was born full term with a birth weight of 3 kg of a normal vaginal delivery. Antenatal ultrasound examination had been performed and was told to be normal. She was born to nonconsanguineously married parents and has normal milestones of development and is immunized to date. On clinical examination vitals were stable. Per abdominal examination revealed a nontender mass, with rounded

border, firm to hard in consistency, 15 x 10 cm in size involving right hypochondrium, lumbar region and was extending to right iliac fossa (Figure 1A). There was no significant movement of the mass with respiration. It was not bimanually palpable or ballotable. All borders were well defined. There was no free fluid or any associated hepatosplenomegaly. No other abnormalities were detected on systemic examination. Differential diagnosis included neuroblastoma and teratodermoid tumor. Investigations were done, Hb (11.3 g/dl), PCV (33.7%), total count (10100/ μ l), neutrophils (73%), lymphocytes (22%), eosinophils (2.3%), monocytes (2.2%), ESR (63 mm/hour), and platelets count (210000/ μ l) were all found to be normal. BT: 2 minutes CT: 12 minutes HIV/HBsAg: negative, Serum creatinine: 0.4 mg% Lactate dehydrogenase: 945 IU/L, Alpha feto protein: 4.55 ng/mL, Serum Ca⁺⁺: 9.7 mg%. Urine routine and spot for Vanillyl mandelic acid were normal. Ultrasonography (USG)/ Computer Tomography (CT) scan abdomen and pelvis: suggestive of retroperitoneal swelling (Figure 1B). As the clinical findings and radiological diagnosis was retroperitoneal tumor, laparotomy was done. Peroperatively tumor was seen arising from retroperitoneum, adherent to ascending colon (Figure 1C), second and third part of duodenum, right kidney and ureter. The retroperitoneal mass was resected in toto. Right kidney (with renal capsule) and bowels were intact. The postoperative period was uneventful. On gross examination, the specimen consisted of a large nodular tissue measuring 9 x 7.5 x 5 cm (Figure 1D).

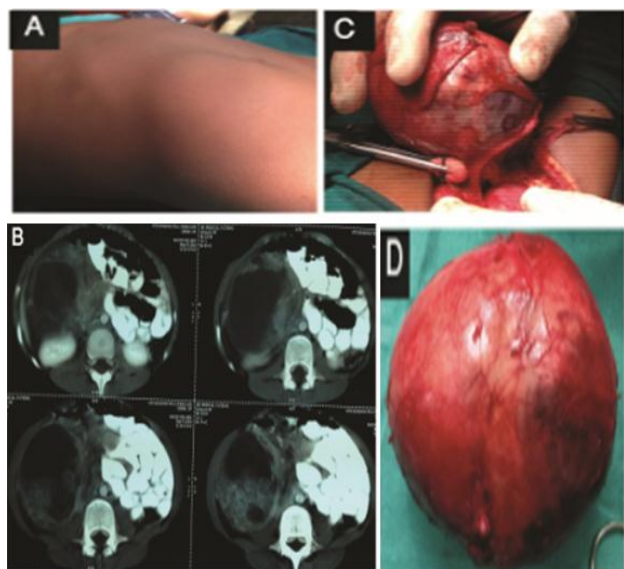


Figure 1: A) Right sided abdominal mass visible on examination abdomen; B) CT showed mass lesion arising from the retroperitoneum; C) Per operatively tumor was seen arising from retroperitoneum, adherent to ascending colon, second and third part of duodenum, right kidney and ureter; and D) Gross examination of the specimen consisted of a large nodular tissue measuring 9 x 7.5 x 5 cm.

The cut surface was solid, lobulated and grayish white in color. Histopathological examination showed features of Wilms' tumor, exhibiting both epithelial and mesenchymal differentiation (Figure 2A & 2B). The features of anaplasia were not appreciated. The child had a good recovery and was discharged on antibiotics for the wound healing. She is under follow-up of 9 months and is doing well.

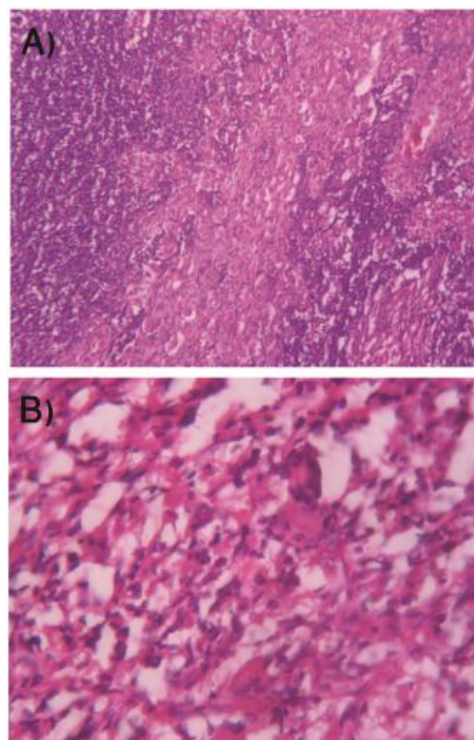


Figure 2: A and B Photomicrographs of mass-specimen (stained by H&E) showing features of Wilms' tumor, exhibiting both epithelial and mesenchymal differentiation with spindle cell stroma, separating lobules of blastemal tissue containing abortive tubules and glomeruli.

DISCUSSION

Wilms' tumor may occur in an extrarenal location without primary renal involvement and must be included in the differential diagnosis of abdominal, pelvic, and inguinal masses. ERWT excludes primary neoplasms those are arising from the kidney. It is extremely rare and the exact incidence is not known.^{5,6} A slight male preponderance seen in occurrence of ERWT. The age at presentation usually ranges from 2 months - 10 years. Exceptionally young (an 8 day-old child) and old (77 year-old female) cases have also been reported.⁷ It is usually associated with other neoplasms including teratoma in many cases^{1,2} The non-neoplastic association of this tumor is with horse-shoe kidney reported in six patients and spinal dysraphism in two cases.⁸ A palpable mass is the most common presentation. Patients with uterine ERWT may present with irregular menstrual bleeding.⁹ Our case also presented as solid abdominal

mass, the most commonly reported form so far. Constitutional symptoms are typically absent in our case that usually present at an advanced stage only.

The exact mechanism of pathogenesis is not clear. However, there are some popular hypotheses regarding the origin such as: first hypothesis is the origin from the ectopic metanephric blastema: this hypothesis is supported by the fact that the majority of the tumors occur in the retroperitoneal region. However, the presence of ERWT cephalad to kidney argues against it.¹⁰ Second hypothesis is the origin from the primitive mesodermal tissue: This hypothesis is based on the occurrence of ERWT in the cervix, vagina and inguinal canal, where there is a persistent mesonephric duct remnant.¹¹ The third is the Connheim's cell rest theory: This is a common hypothesis where cells with persistent embryonal potential undergo malignant transformation at any point of time.¹²

The clinical presentation may vary depending on its location with pressure effects on the adjacent vital structures such as blood vessels, nerves, ureter, bladder, and bowel.¹³ It is generally located anywhere in the retroperitoneum. The other sites of occurrence are inguinal region, endocervix, uterus, epididymis, ova testis and any place in retroperitoneum along paravertebral area.¹⁴ ERWT have similarity to renal nephroblastomas in the histogenesis, morphology, clinical staging, behavior, prognosis, as well as response to therapy.¹⁵

USG of the abdomen usually reveals the homogenous solid mass and intravenous urethrogram may show dilatation of the pelvicalyceal system due to mass effect from the tumor. CT of the abdomen typically shows a solid mass with either homogenous or heterogeneous enhancement. On magnetic resonance imaging, the mass is isointense to muscle on T1WI, slight hyperintense on T2WI and characteristically enhances intensely on post contrast (gadolinium) images. Angiography in a case showed an enlarged right gonadal artery and irregularly tortuous vessels in the tumour similar to intrarenal WT ("spider leg" or "creeping vine" appearance).¹⁶ The diagnosis of ERWT has to be done after ruling out an extension from the intrarenal WT or a metastatic lesion. The final diagnosis could only be arrived on histopathological examination.^{2,8,10,14}

Nephroblastomatosis is also associated with (1) WAGAR syndrome, (2) Denys-Drash syndrome, and (3) Beckwith Weidman Syndrome and thus associated with increased risk of developing WT. This suggests the related manifestations of genetic damage, affecting single gene or closely linked genes WT1 and WT2. The expression of WT1-mRNA has also been seen in some ERWT, indicating similar histogenesis as that of renal nephroblastoma.^{10,17,18}

The staging and management protocols of intrarenal WT can be applied to an extrarenal location as well according

to the National Wilms' Tumor Study (NWTS) protocol.¹² All cases treated by surgery need postoperative adjuvant chemotherapy, and drugs used for renal nephroblastoma, were equally effective for extrarenal nephroblastoma.¹⁷ Radiotherapy should be reserved for those patients with unresectable gross residual tumor and those with distant metastasis.^{12,17} The prognosis of ERWT is similar to its renal counterparts with the appropriate stage.¹⁷ The presence of anaplasia, characterized by extreme polyploidy, with nuclear and mitotic atypia, indicates poor prognosis as they show increased resistance to therapy.^{18,19} In this case, no evidences for anaplastic features. Conventional histology of the cystic variant is reported to have a slightly better prognosis than the solid ones. Similar to the classical WT, ERWT has a potential for local recurrences as well as distant metastases.^{10,12,17,20} Metastasis have been reported in lungs, liver, pancreas and brain and is responsible for poor prognosis.²⁰ The case reported did not have any evidence of any metastasis and after the excision of the tumor is doing well after 9 months of follow-up.

CONCLUSION

ERWT is an extremely rare in children. It should be differentiated from neuroblastoma and retroperitoneal teratoma. The prognosis in adequately treated ERWT is quite good if no anaplasia is evidenced in the histopathology.

Funding: No funding sources

Conflict of interest: None declared

Ethical approval: Not required

REFERENCES

- Grosfeld JL, Ballantine TV, Lowe D, Bahener RL. Benign and malignant teratomas in children: analysis of 85 patients. *Surgery.* 1976;80:297-305.
- Amit Chaudhary, Samir Misra, Ashish Wakhlu, R. K. Tandon, A. K. Wakhlu. Retro peritoneal teratomas in children. *Indian J Pediatr.* 2006;73:221-3.
- Rojas Y, Slater BJ, Braverman RM, Eldin KW, Thompson PA, Wesson DE, et al. Extrarenal Wilms tumor: a case report and review of the literature. *J Pediatr Surg.* 2013;48:E33-5.
- Arda IS, Tuzun M, Demirhan B, Sevmis S, Hicsonmez A. Lumbosacral extrarenal Wilms' tumour: a case report and literature review. *Eur J Pediatr.* 2001;160:617-9.
- McAlpine J, Azodi M, O'Malley D, Kelly M, Golenewsky G, Martel M, et al. Extrarenal Wilms' tumor of the uterine corpus. *Gynecol Oncol.* 2005;96:892-6.
- Hussain S, Nizami S, Tareen F. Neonatal extra-renal Wilm's tumour. *J Pak Med Assoc.* 2004;54:37-8.
- Jiscot P, Aertsens W, Degels MA, Moerman P. Extrarenal Wilm's tumor of the uterus. *Eur J Gynaecol Oncol.* 1999;20:195-7.

8. Yunus M, Hashmi R, Hasan SH, Brohi HM. Extrarenal Wilms' tumor. *J Pak Med Assoc*. 2003;53:436-9.
9. Sahin A, Benda JA. Primary ovarian Wilm's tumor. *Cancer*. 1988;61:1460-3.
10. Broecker BH, Caldamone AA, McWilliams NB, Maurer H, Salzberg A. Primary Extrarenal Wilms' tumor in children. *J Pediatr Surg*. 1989;24:1283-8.
11. Fernandes ET, Kumar M, Douglas EC, Wilimas J, Parham DM, Rao BN. Extrarenal Wilms' tumor. *J Pediatr Surg*. 1989;24:483-5.
12. Andrews PE, Kelalis PP, Haase GM. Extrarenal Wilm's tumor: results of national Wilms' tumor study. *J Pediatr Surg*. 1992;27:1181-4.
13. Goel V, Verma AK, Batra V, Puri SK. Primary extrarenal Wilms' tumour: rare presentation of a common paediatric tumour. *BMJ Case Rep*. 2014;2014:pil: bcr2013202172.
14. Lakhkar BN, Rajgopal KV, Shetty CM, Avinash KR. Extrarenal Wilms' tumour: a case report. *Indian J Radiol Imaging*. 2004;14:147-8.
15. Waingankar VS, Meisheri IV, Patel MP, Ramesh S, Naregal A, Muthal P. Extrarenal Wilms' tumour: a case report and review of literature. *Indian J Cancer*. 1995;32:135-40.
16. Suzuki K, Miyake H, Tashiro M, Mori H, Fukushige T, Tanimura R, et al. Extrarenal Wilms' tumour. *Pediatr Radiol*. 1993;23:149-50.
17. Roberts DJ, Haber D, Sklar J, Crum CP. Extrarenal Wilms' tumors. A study of their relationship with classical renal Wilms' tumor using expression of WT1 as a molecular marker. *Lab Invest*. 1993;68:528-36.
18. Faria P, Beckwith JB, Mishra K, Zuppan C, Weeks DA, Breslow N, et al. Focal versus diffuse anaplasia in Wilms tumor - new definitions with prognostic significance: a report from the National Wilms' Tumor Study Group. *Am J Surg Pathol*. 1996;20:909-20.
19. Beckwith JB. New developments in pathology of Wilms' tumour. *Cancer Invest*. 1997;15:153-62.
20. Egeler RM, Wolff JE, Anderson RA, Coppes MJ. Long-term complications and post-treatment follow-up of patients with Wilms' tumor. *Semin Urol Oncol*. 1999;17:55-61.

DOI: 10.5455/2349-3291.ijcp20150519

Cite this article as: Kumar S, Sunilkumar MN, Surendran D. Extrarenal nephroblastoma in a 7 year old child: a rare case report with review of literature. *Int J Contemp Pediatr* 2015;2:155-8.