

Original Research Article

Two dimensional echocardiography as an evidence for clinically significant murmur

Mohan Kumar N., Vinutha Patil, Varshini P., Chaitra K. M.*

Department of Pediatrics, Kempegowda Hospital, Bengaluru, Karnataka, India

Received: 05 August 2021

Revised: 07 October 2021

Accepted: 01 November 2021

*Correspondence:

Dr. Chaitra K. M.,

E-mail: drchaitrakm@gmail.com

Copyright: © the author(s), publisher and licensee Medip Academy. This is an open-access article distributed under the terms of the Creative Commons Attribution Non-Commercial License, which permits unrestricted non-commercial use, distribution, and reproduction in any medium, provided the original work is properly cited.

ABSTRACT

Background: Heart murmurs are extra and abnormal sounds made by turbulent flow of blood through heart. The most common cardiac abnormality found on auscultation is murmur. Edler is regarded as father of echocardiography. This is based on reflection of sound waves by heart structures similar to the radio detection and ranging (RADAR) and sound navigation and ranging (SONAR).

Methods: Our study was done in PICU of Kempegowda Institute of Medical Sciences hospital, Bangalore. Duration of study was 6 years that is from January 2015 to January 2020. During this period total 2304 pediatric cases with various diseases were admitted. Of these 150 (6.5%) children were having clinically significant murmur. All children who fulfilled inclusion criteria were subjected to 2d echo by GE VIVID portable 2 dimensional and colour Doppler echocardiography trans-thoracically.

Results: 96 (64%) children had abnormal 2d echo. Of these 37 (38.5%) children were found to have organic heart disease and 59 (61.5%) had functional heart disease. Of these 37 children 10 (27%) had pulmonary arterial hypertension (PAH), 8 (21%) children had atrial septal defect, 7 (18%) had perforated foramen ovale (PFO), 2 (5%) had mitral valve prolapse, 2 (5%) had ventricular septal defect (VSD), 1(2%) had tetralogy of fallot (TOF), 1 (2%) had septal aneurysm, and 1 (2%) had pericardial effusion.

Conclusions: There is 64% chances of detecting a heart disease, if 2D echo is done in children with clinically significant cardiac murmur. Hence 2D echo is a vital investigation in evaluating heart murmurs.

Keywords: 2D echocardiography, Cardiac murmur, Clinically significant murmur

INTRODUCTION

Heart murmurs are extra and abnormal sounds made by turbulent flow of blood through heart. The most common cardiac abnormality found on auscultation is murmur that too predominantly systolic murmur which is found in 80–90% children and 15–44% of adults.¹ The two main causes of cardiac murmur are functional and organic. The objective of the study was to evaluate the importance of 2D echocardiography (ECHO) in children with clinically significant murmur so that 2D ECHO can be used as an

investigation of choice routinely in all children with clinically significant murmur.

Types of murmur

Systolic murmur-murmur that occurs when heart contracts. Diastolic murmur-murmur that occurs when heart relaxes. Continuous murmur-murmur that occurs throughout the cardiac cycle. Presence of systolic murmur does not always indicate organic heart disease. Not all systolic murmurs are pathological, these are called innocent murmurs.

Criteria for innocent murmurs²

It included: systolic, short duration, loudest usually along left sternal border, medial to apex, transmission occurs but not widespread, loudness varies from examination to examination but usually less than grade 3, loudness may change with posture, other heart sounds normal, no consistent change in loudness with respiration, and increased loudness of murmur with exercise.

Organic murmurs³

It included: all diastolic murmurs, all pansystolic murmurs, late systolic murmurs, very loud murmurs >grade 3, continuous murmurs, and associated cardiac abnormalities.

2D ECHO is an important investigation done in day to day practice. The original description of M-mode echocardiography was done by Inge Edler and his physician friend Hellmuth Hertz in 1953.⁴ This was a marked non-invasive diagnostic technique. His work was followed by cardiologists all over the world who developed two dimensional, Doppler and transesophageal ECHO. Edler is regarded as father of echocardiography.⁵

This is based on reflection of sound waves by heart structures similar to the radio detection and ranging (RADAR) and sound navigation and ranging (SONAR) used in the world.⁶

Objectives

The objective of this study is to assess the importance of 2D ECHO in evaluating clinically significant murmur.

METHODS

This is a retrospective study, done in PICU of KIMS hospital Bangalore. Duration of study was 6 years that is from January 2015 to January 2020. During this period total 2304 paediatric cases with various diseases were admitted. Murmurs which were grade 3 and above were taken as significant and all diastolic, pansystolic murmurs were included and taken in to study.

Exclusion criteria were children who were already diagnosed cases of congenital heart diseases, children with haemoglobin less than 10 gram/dl.

From the medical records section individual case files were obtained and all children with documented significant murmur were selected which was 150 (6.5%) children were having clinically significant murmur. Of these 150 children, 2 children were excluded as they were already known cases of congenital heart diseases. As the investigation was non-invasive and mandatorily required for the sake of treatment of children ethical clearance was taken. All these children were subjected to 2D ECHO by GE VIVID portable 2 dimensional and colour Doppler

ECHO trans-thoracically (Figure 1). 2D ECHO reports were obtained from case files and digital records. The data obtained was subjected to statistical analysis by Chi square test.

RESULTS

Mean age of distribution of children with significant murmur was 4.5 ± 4 years. Majority of children that is 72 (48%) belonged to age group 1-5 years. 94 (62.6%) were boys and 56 (37.4%) were girls. Among these children most children presented with bronchopneumonia that is 16 (16.6%) (Figure 3).

A total 14 (14.5%) children presented with dengue fever and rest had various other illness. 96 (64%) children had abnormal 2D ECHO. Of these 37 (38.5%) children were found to have organic heart disease and 59 (61.5%) had functional heart disease. Of these 37 children 10 (27%) had pulmonary arterial hypertension (PAH), 8 (21%) children had atrial septal defect, 7 (18%) had perforated foramen ovale (PFO), 2 (5%) had mitral valve prolapse, 2 (5%) had ventricular septal defect (VSD), 1 (2%) had tetralogy of fallot (TOF), 1 (2%) had septal aneurysm, and 1 (2%) had pericardial effusion (Table 1 and Figure 2).

Few children with PAH when given thiamine injections were found to have reduced pressures on 2D ECHO. Those who responded to thiamine were classified as thiamine responsive PAH.

Table 1: Heart diseases found in our study.

Heart disease	Number
PAH	10
ASD	8
PFO	7
Mitral valve prolapse	2
VSD	2
TOF	1
Others	7

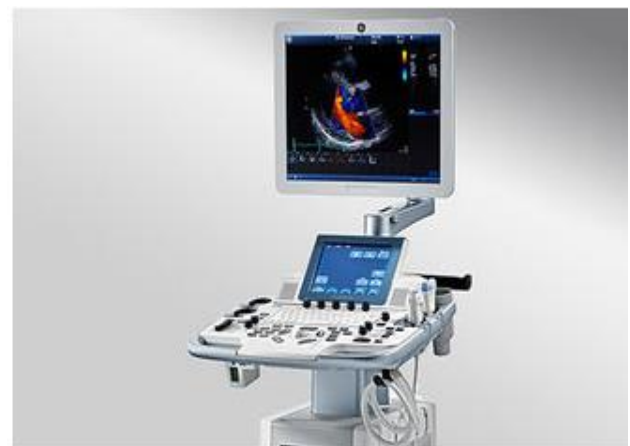

Figure 1: GE VIVID 2D echo machine.

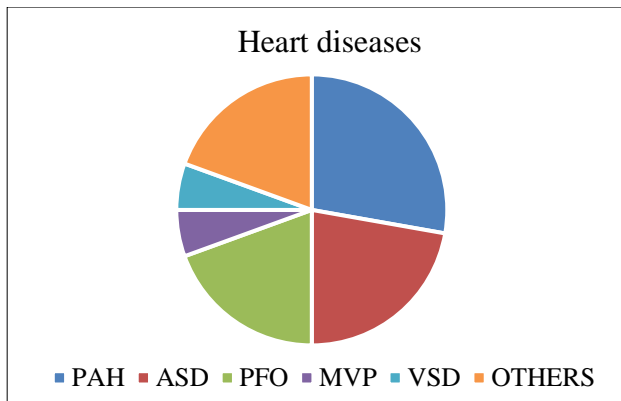


Figure 2: Heart diseases found in our study.

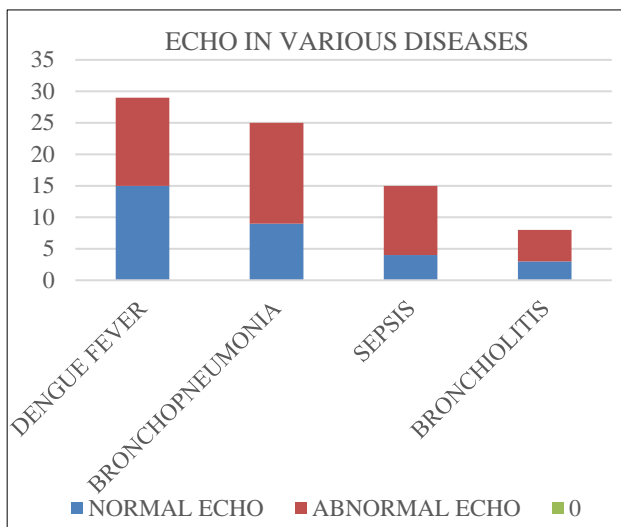


Figure 3: Echo in various diseases, bronchopneumonia cases found to have more abnormal echo findings (16.6%).

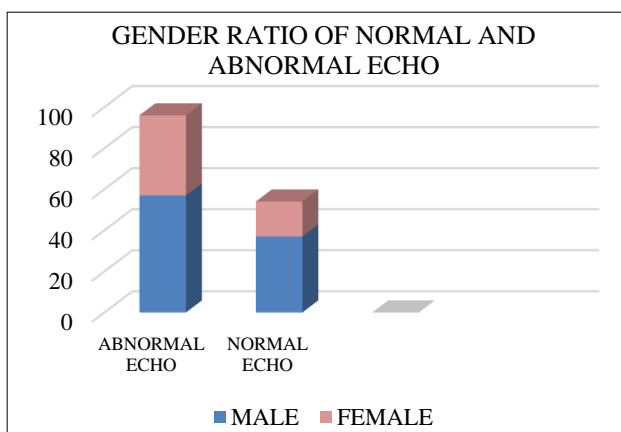


Figure 4: Gender ratio of echo findings: abnormal echo findings more in male.

DISCUSSION

In our study 150 children had clinically significant murmur and 2 excluded as they were known cases of congenital

heart disease. Among these, 96 children were found to have abnormal echo findings, 37 (38.5%) had organic heart disease and 59 (61.5%) had functional heart disease. There by there is 64% children had heart disease among children with clinically significant murmur. Similar findings seen in a study by Smyth and Neidermeyer.^{7,8} This shows 2D ECHO is a very vital investigation in evaluating a child with murmur. Most children (27%) had PAH as the finding on 2D ECHO. This is a functional condition of heart secondary to various respiratory diseases. In our study, majority children (16.6%) had bronchopneumonia leading to raised PAH.

Majority (48%) of children belonged to age group of 1 to 5 years, majority were males 94 (62.6%) and rest were females 56 (37.4%) (Figure 4). Few children with PAH responded to thiamine injections and were classified as thiamine responsive PAH. This study shows that there is 64% chances of detecting a heart disease if 2D ECHO is done in children with clinically significant murmur.⁹ Ainsworth et al study emphasizes this finding.¹⁰

2D ECHO is a vital investigation in children with clinically significant murmur.^{11,12} routine application of 2D ECHO will help in identification of fatal cardiac conditions in children and prompt intervention.¹³

Limitations

Few cardiac conditions do not clinically present significantly will be detected only after 2D ECHO. Such cases will be missed if only significant murmur is taken into inclusion.

CONCLUSION

2D ECHO is a vital investigation in evaluating heart diseases. If there is a clinically significant murmur there is 64% chance of detecting a heart disease by 2D ECHO. Professionals should be aware that detection of a murmur should not be neglected and echocardiography should be done. There by if any lesion found can promptly refer to cardiologists for further treatment. 2D ECHO should be an investigation of choice if clinically significant murmur is detected.

ACKNOWLEDGEMENTS

Authors would like to thank medical records section of KIMS Hospital for providing required data.

Funding: No funding sources

Conflict of interest: None declared

Ethical approval: The study was approved by the Institutional Ethics Committee

REFERENCES

1. Lateef MA. Cardiac murmurs in children. 2015. Available at: <https://www.slideshare.net/Lateef>

- Siddiqui1/cardiac-murmur-by. Accessed on 08 July 2021.
2. AHA Innocent heart murmurs. 2019. Available at: <https://educatesimplify.com/news/aha-pals-2019-innocent-heart-murmurs/>. Accessed on 08 July 2021.
3. Perlauff textbook Cardiac murmurs in children , textbook of pediatric cardiology
4. Attenhofer Jost CH, Turina J, Mayer K, Seifert B, Amann FW, Buechi M, Facchini M, Brunner-La Rocca HP, Jenni R. Echocardiography in the evaluation of systolic murmurs of unknown cause. *Am J Med*. 2000;108(8):614-20.
5. Singh S, Goyal A. The origin of echocardiography: a tribute to Inge Edler. *Tex Heart Inst J*. 2007;34(4):431-8.
6. Mohamed AA, Arifi AA, Omran A. The basics of echocardiography. *J Saudi Heart Assoc*. 2010;22(2):71-6.
7. Smythe JF, Teixeira OH, Vlad P, Demers PP, Feldman W. Initial evaluation of heart murmurs: are laboratory tests necessary? *Pediatrics*. 1990;86(4):497-500.
8. Niedermeyer J, Daniel WG. Value of transesophageal echocardiography in diagnosis of diseases of native heart valves. *Herz*. 1993;18(6):329-40.
9. Ahmadipour S, Mohsenzadeh A, Soleimaninejad M. Echocardiographic Evaluation in Neonates with Heart Murmurs. *J Pediatr Intensive Care*. 2018;7(2):81-5.
10. Ainsworth S, Wyllie JP, Wren C. Prevalence and clinical significance of cardiac murmurs in neonates. *Arch Dis Child Fetal Neonatal Ed*. 1999;80(1):43-5.
11. Cheitlin MD, Alpert JS, Armstrong WF, Aurigemma GP, Beller GA, Bierman FZ, et al. ACC/AHA Guidelines for the Clinical Application of Echocardiography. A report of the American College of Cardiology/American Heart Association Task Force on Practice Guidelines (Committee on Clinical Application of Echocardiography). Developed in collaboration with the American Society of Echocardiography. *Circulation*. 1997 Mar 18;95(6):1686-744.
12. Nale SR, Garud B, Chavan SC. A study of profile of heart murmurs in correlation with clinical examination and 2D echo. 2020.
13. Attenhofer Jost CH, Turina J, Mayer K, Seifert B, Amann FW, Buechi M, Facchini M, Brunner-La Rocca HP, Jenni R. Echocardiography in the evaluation of systolic murmurs of unknown cause. *Am J Med*. 2000;108(8):614-20.

Cite this article as: Mohan KN, Patil V, Varshini P, Chaitra KM. Two dimensional echocardiography as an evidence for clinically significant murmur. *Int J Contemp Pediatr* 2022;9:163-6.