

## Case Report

# The modified Nadeem's technique for the treatment of H-type tracheoesophageal fistula

Fatima Al Zahra<sup>1</sup>, Nadeem Akhtar<sup>1</sup>, Sana Khan<sup>1\*</sup>, Mohammed Abdulmomen Abdullah Saif<sup>1</sup>,  
Muhammad Umair Butt<sup>2</sup>, Ramsha Syed<sup>1</sup>

<sup>1</sup>Department of Pediatric Surgery, Pakistan Institute of Medical Sciences (PIMS), Shaheed Zulfiqar Ali Bhutto Medical University, Islamabad, Pakistan

<sup>2</sup>Department of Pediatric Medicine, Shifa College of Medicine, Islamabad, Pakistan

**Received:** 29 April 2021

**Accepted:** 27 May 2021

### \*Correspondence:

Dr. Sana Khan,

E-mail: [ssana35@yahoo.com](mailto:ssana35@yahoo.com)

**Copyright:** © the author(s), publisher and licensee Medip Academy. This is an open-access article distributed under the terms of the Creative Commons Attribution Non-Commercial License, which permits unrestricted non-commercial use, distribution, and reproduction in any medium, provided the original work is properly cited.

## ABSTRACT

An H-type fistula is an unusual category of the tracheoesophageal fistula to occur constituting only 5 % of all cases. The continuity of the esophagus leads to a delayed and vague presentation with a complaint of choking on feed and respiratory issues unlike the inability to feed and frothing soon after birth in other variants of tracheoesophageal fistula. We received a referred case of a 3-months-old male having recurrent respiratory tract infections and episodes of choking. After a thorough evaluation, a suspicion of H-type fistula was encountered that led to refined radiological evaluation. Contrast given per oral also delineated fistula and CT scan with intravenous and oral contrast revealed fistulous communication between two channels. Operated for H-type fistula through the modified Nadeem's technique via a left cervical approach and discharged after uneventful recovery. The modified Nadeem's technique via a left-sided cervical approach facilitates access, vision, and intervention easily as compared to the conventional right-sided approach given in the literature.

**Keywords:** Tracheoesophageal, Fistula, Transfixation, Ligation

## INTRODUCTION

An H-type fistula is 5% of tracheoesophageal fistula variants as per Gross classification. The incidence of TEF overall being 1 in 2000-5000 live births.<sup>2</sup> The cause is multifactorial having genetic and environmental factors as well as syndromic association. Though familial propensity is not usually seen. Tracheoesophageal fistula is thought to have developmental issues of improper budding of respiratory diverticulum or failure in recanalization or separation through the septum. The mortality was initially exceptionally high owing to the complexity of the condition and its alliance with cardiac issues. Neonates with compromised birth weight were more prone to mortality. With emerging care facilities for low-birth-

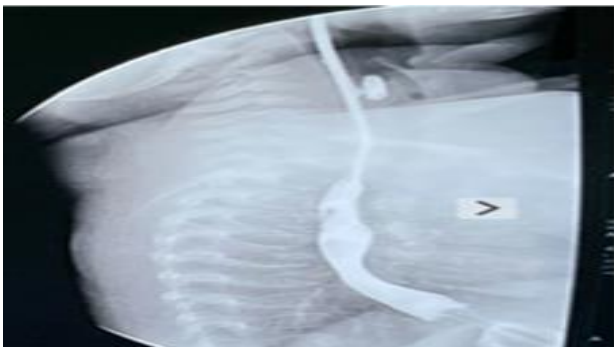
weight neonates in NICU settings, the quality of care had a promising impact on the overall outcome of these neonates as depicted by Okamoto and Spitz. The worse consequential result was seen in neonates having a cardiac malformation, TEF, and low birth weight of less than 2000 g<sup>3</sup>. That being said the studies are mostly carried out in the esophageal atresia patients with a tracheoesophageal fistula that formulates 86% of all cases. The unusual types are lesser evaluated owing to low incidence.

One of such variants is an H-type fistula with no esophageal atresia but communication between the trachea and esophagus. These patients present later as compared to type 3; distal fistula which are diagnosed soon after birth or even antenatally.<sup>4</sup> The late presentation is due to

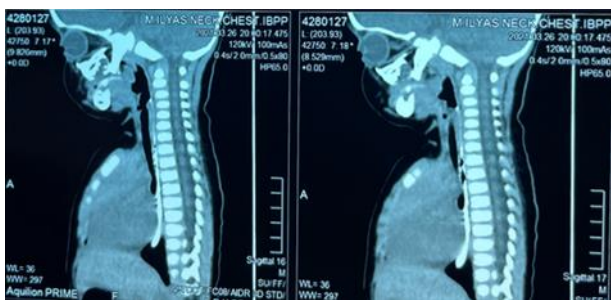the muscular esophageal tube occluding the opening partially. Also, the antenatal presentation is not common because of the lack of polyhydramnios as in other causes of upper GI obstruction in other variants of TEF and small gut atresia. The usual presentation is of an infant having recurrent chest infections and choking on feeding. The patent communication allows feed to trickle in the airway in a prone and recumbent posture. There is usually a history of ALTE (apparent life-threatening events). The case usually lands with the medical faculty initially and Pediatric surgery is in routine involved based on strong suspicion.<sup>5</sup> We encountered an H-type fistula as a referred case from pediatric medicine. Since the condition was atypical it mandated mention so does the innovation in the approach we opted for.

**CASE REPORT**

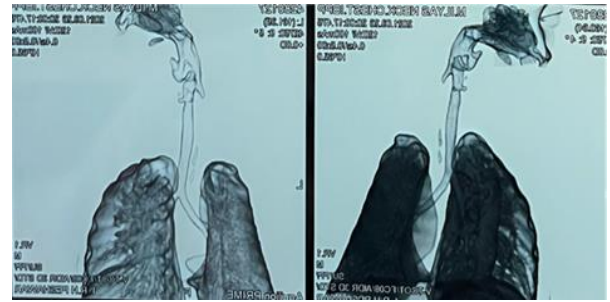
A 3-months-old baby landed in our outpatient department as a referred case of pediatric medicine, initially being treated in a tertiary care set up for recurrent chest infections. The provisional impression was of an H-type fistula for which a contrast swallow and a CT scan were advised.<sup>1,2</sup> Hence, there was no need for esophagoscopy. Both the studies showed patent tract coursing from the esophagus to the trachea in the proximal part of the channel in the mid-upper thorax. The patient after being administered anesthesia was evaluated via bronchoscopy that identified a fistulous tract at the 6 o'clock position. Modified Nadeem's technique was used. In this technique, the left cervical approach was used rather than the contemporary right sided approach.



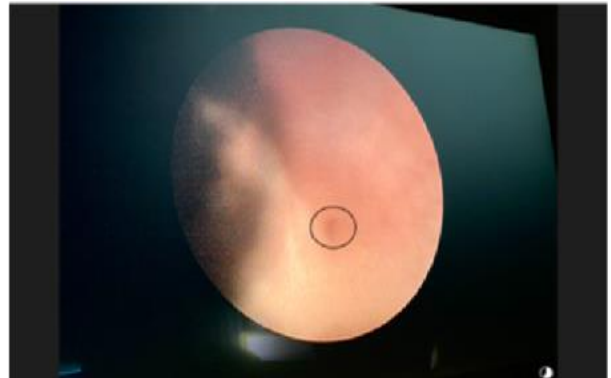
**Figure 1: Contrast swallow depicting fistulous communication.**



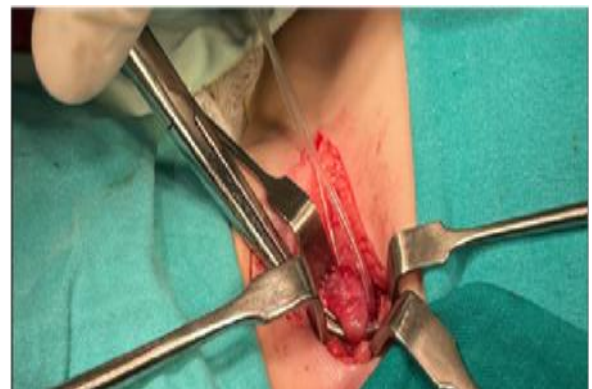**Figure 2: Coronal view CT scan of H-type fistula.**



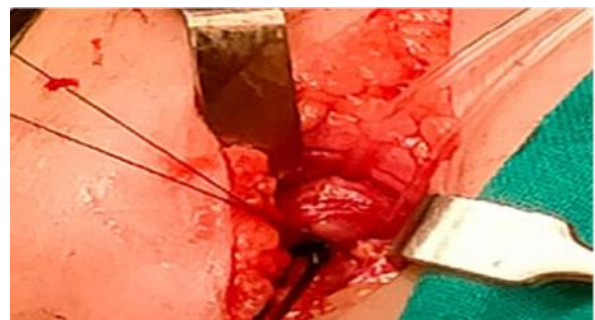**Figure 3: High resolution CT- 3D view of H-TEF.**



**Figure 4: Bronchoscopic view of fistula at 6 o'clock position.**



**Figure 5: Esophageal lumen held up with a sling occluding the patency, following air insufflation via NG tube thus enhancing the fistulous communication.**



**Figure 6: Visual depiction of modified Nadeem's technique.**

A transverse incision was made 2 cm above the left clavicle. Deep cervical fascia and platysma were incised. The lower aspect of the thyroid lobes became clear in the view and was retracted. The trachea with its C-shaped cartilages was followed distally to see for the passage which was not found. Distal esophagus was occluded by pulling up with the sling. Nasogastric tube was placed in the proximal esophagus and air injected into the NG tube by the anesthetist. This led to ballooning of the fistula and helped in easy identification of the fistulous tract which was then followed by separation and transfixation followed by free ligation. The patient was retained in PICU and then shifted back to the inpatient ward the next day. The patient was fed via nasogastric tube and subsequently shifted to oral feed.

## DISCUSSION

An H-type fistula has been picked usually after having dubiety with recurrent chest infections. The diagnosis is complemented with contrast studies in the form of barium swallow in prone position to let the contrast seep in the trachea or CT scan with oral contrast. A contemporary approach is to visualize the fistulous opening with bronchoscopy where cartilages in the trachea keep the luminal patency and enhance track down of opening.

The scarce literature on the subject advocates a right-sided cervical approach though few surgeons opted for thoracic or left sided approach as well. Few centers recommend thoracoscopic approach under the umbrella of minimal invasive surgery.<sup>6</sup> The H-type fistula is commonly in upper aspect before tracheal bifurcation at carina and is oblique.<sup>7</sup> Ou et al reported that air distension of the esophagus via NG tube during high resolution CT acquisition in a critically ill neonate provided better visualization of the fistulous communication.<sup>8</sup> The modified Nadeem's technique via a left cervical approach remains superior because it gives clear and easy identification of each fistula by direct air insufflation of the upper esophagus.<sup>9</sup> Peri-operative preparation is crucial for optimal outcome as lung parenchyma has been compromised by ongoing chest infections. Per operative positioning includes head support and neck extension. Anesthesia should be ideally administered via single lung ventilation. Another significant per operative concern is placing a guidewire in opening once it is identified.<sup>10</sup> Many experienced surgeons don't probe after confirmation and intervene directly instead. Post-operatively the main complication suspected is damage to recurrent laryngeal nerve that leads to postoperative stridor in some patients.<sup>11</sup> Other possible complications are damage to adjacent structures, thyroid, cartilaginous ring of trachea, carotid sheath. Furthermore, the damage to adjacent structures including cartilaginous ring of trachea, thyroid gland and carotid sheath was less pronounced using this technique. Another concern is the option of either transfixation and resection or leaving after tying up the fistulous tract. The possibility of recurrence is noticed in both as trans fixation alone is not reliable

enough but division of two ends also poses equal risk as two raw surfaces healing at same time may end in recurrence. The recurrence in distal fistula is found to be 11%. The success rate in literature for H-type fistula is nearing 100%.<sup>12</sup>

## CONCLUSION

A left sided H-type fistula ligation via the modified Nadeem's technique proves to be safe and efficacious. Moreover, identifying the fistulous tract by air instillation through the nasogastric tube while kinking the esophageal lumen is an effective means to pinpoint the tract.

*Funding: No funding sources*

*Conflict of interest: None declared*

*Ethical approval: Not required*

## REFERENCES

- Clark DC. Esophageal atresia and tracheoesophageal fistula. *Am Fam Physician.* 1999;59(4):910-6.
- Spitz L. Oesophageal atresia. *Orphanet J Rare Dis.* 2007;2:24.
- Solomon BD, Baker LA, Bear KA, Cunningham BK, Giampietro PF, Hadigan C, et al. An approach to the identification of anomalies and etiologies in neonates with identified or suspected VACTERL (vertebral defects, anal atresia, tracheo-esophageal fistula with esophageal atresia, cardiac anomalies, renal anomalies, and limb anomalies) association. *J Pediatr.* 2014;164(3):451-7.
- Risher WH, Arensman RM, Ochsner JL. Congenital bronchoesophageal fistula. *Ann Thorac Surg.* 1990;49(3):500-5.
- Lal D, Miyano G, Juang D, Sharp NE, Peter SD. Current patterns of practice and technique in the repair of esophageal atresia and tracheoesophageal fistula: an IPEG survey. *J Laparoendosc Adv Surg Tech A.* 2013;23(7):635-8.
- Aziz GA, Schier F. Thoracoscopic ligation of a tracheoesophageal H-type fistula in a newborn. *J Pediatr Surg.* 2005;40(6):35-6.
- Lelonge Y, Varlet F, Varela P, Saitua F, Fourcade L, Gutierrez R, et al. Chemocauterization with trichloroacetic acid in congenital and recurrent tracheoesophageal fistula: a minimally invasive treatment. *Surg Endosc.* 2016;30(4):1662-6.
- Ou P, Seror E, Layouss W, Revillon Y, Brunelle F. Definitive diagnosis and surgical planning of H-type tracheoesophageal fistula in a critically ill neonate: first experience using air distension of the esophagus during high-resolution computed tomography acquisition. *J Thorac Cardiovasc Surg.* 2007;133(4):1116-7.
- Pinheiro PF, Simoes SAC, Pereira RM. Current knowledge on esophageal atresia. *World J Gastroenterol.* 2012;18(28):3662-72.
- Antabak A, Luetic T, Caleta D, Romic I. H-type Tracheoesophageal Fistula in a Newborn:

Determining the Exact Position of Fistula by Intra-operative Guidewire Placement. *J Neonatal Surg.* 2014;3(3):36.

11. Zani A, Jamal L, Cobellis G, Wolinska JM, Fung S, Propst EJ, Chiu PP, et al. Long-term outcomes following H-type tracheoesophageal fistula repair in infants. *Pediatr Surg Int.* 2017;33(2):187-90.
12. Fallon SC, Langer JC, Peter SD, Tsao K, Kellagher CM, Lal DR, et al. Congenital H-type tracheoesophageal fistula: A multicenter review of outcomes in a rare disease. *J Pediatr Surg.* 2017;52(11):1711-4.

**Cite this article as:** Zahra FA, Akhtar N, Khan S, Saif MAA, Butt MU, Syed R. The modified Nadeem's technique for the treatment of H-type tracheoesophageal fistula. *Int J Contemp Pediatr* 2021;8:1264-7.