

## Case Report

# Miliary tuberculosis: an atypical presentation

N. Santosh Kumar\*, Ravi Prakash Naulakha, Ipsita Vashishtha, Neelu Elon,  
Rajdeep Pal, Prithi Inamdar, Rajesh Rai

Department of Paediatrics, D. Y. Patil University School of Medicine, Navi Mumbai, Maharashtra, India

**Received:** 11 April 2021

**Revised:** 15 May 2021

**Accepted:** 17 May 2021

### \*Correspondence:

Dr. N. Santosh Kumar,

E-mail: [Santhosh.632@gmail.com](mailto:Santhosh.632@gmail.com)

**Copyright:** © the author(s), publisher and licensee Medip Academy. This is an open-access article distributed under the terms of the Creative Commons Attribution Non-Commercial License, which permits unrestricted non-commercial use, distribution, and reproduction in any medium, provided the original work is properly cited.

### ABSTRACT

Miliary tuberculosis (TB) is a severe form of disseminated TB. In developing countries childhood miliary TB is a significant health problem. Pulmonary TB is the most common type of TB in children. Of all TB cases miliary TB accounts for about 1%. We report a case of paediatric miliary TB with acute presentation in a eleven years old female who presented with fever and cough since 3 days and rapid breathing since one day. Clinical examination showed hepatosplenomegaly, on auscultation chest was clear and air entry bilateral equal, chest x-ray was suggestive of miliary shadows suggestive of TB and it was confirmed by HRCT chest. Laboratory studies revealed anaemia and elevated erythrocyte sedimentation rate (ESR). Tuberculin test was negative, gastric lavage for acid-fast bacilli Gene-Xpert was positive for mycobacterium tuberculosis. Fundus examination revealed bilateral small, white sub retinal opacities with the classical appearance of choroidal tubercles. The diagnosis of Miliary TB was confirmed and the patient was started on anti TB therapy.

**Keywords:** Miliary TB, Hepatosplenomegaly, Gene Xpert, Choroid tubercles, HRCT

### INTRODUCTION

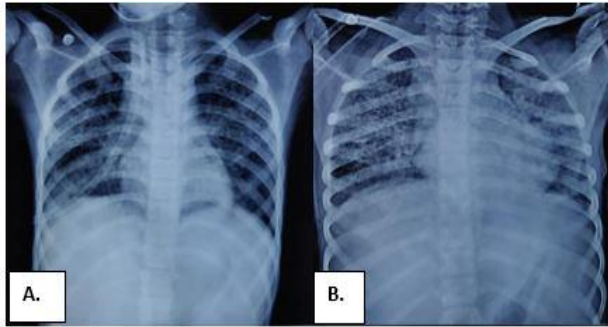
Annual worldwide burden of tuberculosis (TB) in children in 2012 as reported by World Health Organization was approximately 530,000 cases which is 6% of Global TB burden, this included up to 74,000 children mortality. After acquiring infection, the risk factors for developing disease are early childhood, adolescence and immunodeficiency. Risk of developing severe, disseminated form of TB like TB meningitis or miliary TB is more common in infants and young children.<sup>1</sup> Pulmonary TB is the most common type of TB disease in children. In children extra pulmonary TB occurs in approximately 20-30% of all cases. Among all TB cases miliary TB accounts for about 1%.<sup>2</sup> 11% of patients with extra-pulmonary tuberculosis have abdominal involvement and 1% have ocular involvement.<sup>3,4</sup> As it is a paucibacillary disease, the burden of childhood TB is under-reported. Many TB cases are being missed, as the

symptomatology of TB mimics common childhood diseases.<sup>1,5</sup> Lymphohematogenous dissemination of Mycobacterium tuberculosis-laden focus results in miliary TB. Earlier miliary TB was considered as childhood disease but in recent times it is increasingly seen in adults as well, the reason being malnutrition, immunosuppression by medications and diseases, and human immunodeficiency virus (HIV).<sup>6</sup> If miliary TB is suspected, early initiation of empirical treatment increases the chances of survival.<sup>7</sup> The objective of this report is to describe acute presentation of miliary TB with choroidal miliary infiltrates.

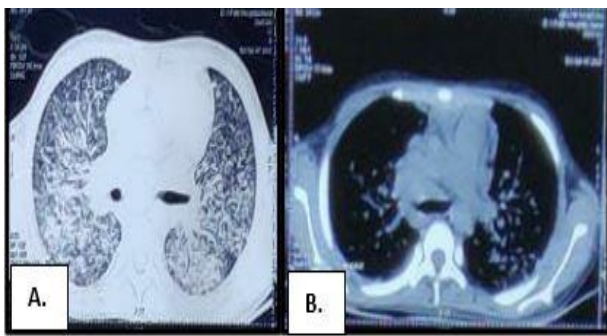
### CASE REPORT

11 years old female presented with complaints of fever and cough since 3 days and rapid breathing since 1 day. She was febrile at time of presentation with tachycardia, tachypnoea and oxygen saturation being 88% on room air.

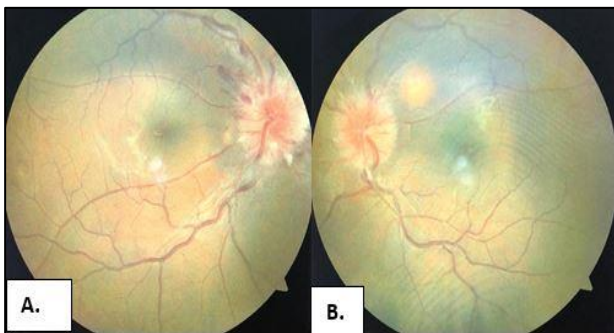
She was put on oxygen by face mask and was admitted in PICU. On examination chest was clear without any adventitious sounds and there was hepatosplenomegaly.



**Figure 1: (A) Day 1. (B) Day 3.**



**Figure 2: (A) Chest CT (lung window) showing classical miliary pattern. (B) CT scan of patient showing bilateral miliary opacification.**



**Figure 3: (A) and (B) Fundus of the patient showing choroid tubercles, characteristic of miliary TB.**

ESR was elevated, chest-X ray on admission was normal. Due to continuous fever spikes and investigations, our initial impression was atypical pneumonia and clarithromycin was started. As oxygen requirement increased, patient was shifted to oxygen by NRM from face mask. Repeat chest-X ray was done on day 3 of admission which showed classic miliary shadows. Mantoux was given which came out negative but GLAFB and gene-xpert was positive. So HRCT chest was done which showed mediastinal lymphadenopathy suggestive of infective etiology likely miliary tuberculosis. Fundus

examination was done which showed bilateral multiple choroid tubercles, which confirmed the diagnosis of miliary TB and AKT was started. Hydrocortisone was started and was given for total 14 days. After 1 week of starting AKT patient condition gradually improved, fever spikes decreased, patient was slowly weaned of oxygen support and was shifted to ward. In ward patient vitals monitored and AKT continued and supplements started. Finally, patient was discharged after 16 days of admission on AKT (intensive phase).

## DISCUSSION

Even though incidence of TB is decreasing, the worldwide disease burden remains a major health problem.<sup>2</sup> If not diagnosed and treated early miliary TB has high mortality. Diagnosis of miliary TB is difficult because of non-specific, atypical symptoms and varied clinical signs. Chest X rays with classic miliary shadows is seen very late in the disease. Therefore, a high index of clinical suspicion and a systematic approach are required to establish the diagnosis of miliary TB.<sup>6</sup> The incidence of the miliary TB in all pediatric TB infections has been found to be different. Hussey et al<sup>8</sup> documented miliary TB in 8% of all TB admissions, while 3.2% of all pediatric TB cases were reported in another study.<sup>9</sup> Pelvic TB or gastrointestinal or genitourinary tracts TB can be easily misdiagnosed as malignant tumors.<sup>10</sup> Peripheral lymphadenopathy and hepatosplenomegaly are more commonly seen in children with miliary TB compared to adults, as seen in our patient. Things which made TB a remote possibility in our patient were: BCG vaccination and presence of its scar, chest examination and chest X-ray were normal initially. BCG vaccination protects from disseminated TB like miliary TB.<sup>6</sup> However, the BCG protective efficacy is controversial ranging from 0 to 80%.<sup>11</sup> Gurkan et al recorded 96% of the cases with no prior BCG vaccination, while in another clinical study by Hussey et al, history of BCG vaccination was documented in 88% of all children with miliary TB. Classic symptoms of TB like chills and night sweats, productive cough and hemoptysis are less common in children as compared to adults. Further data in our case that perplexed our diagnosis, tuberculin test which was negative. For tuberculin skin test, Gurkan et al in their study documented positivity was not obtained in 17 out of 23 patients as would be expected in miliary TB infection at diagnosis. In various published pediatric and adult series tuberculin anergy has ranged from 35 to 74% and 20 to 70%, respectively.<sup>6</sup> Because of the paucibacillary nature of mycobacteria, microbiological confirmation is difficult in children. Smear positivity of the gastric lavage was documented in 20% of children and positive cultures in less than 50% of children with suspected tuberculosis.<sup>12</sup> Out of 96 suspected patients of pulmonary tuberculosis, 60 (62.5%) were culture positive, acid-fast bacilli smear positive were 34 (35.4%) and blood PCR was positive in 14 (14.5%) thus they concluded that due to low sensitivity, a negative PCR assay does not rule the disease.<sup>13</sup>

In patients with miliary TB several uncommon clinical manifestations and complications were observed, example- focal extra pulmonary TB.<sup>6</sup> Intrathoracic and sometimes, intra-abdominal lymphadenopathy may be associated with miliary TB.<sup>6</sup> The choroid tubercles in miliary TB vary in size from one sixth to two thirds of a papillary diameter.<sup>14</sup> Choroidal tubercles when present is considered to be pathognomonic of military TB, as in our case. Therefore, in all patients with suspected miliary TB an ophthalmoscopic examination is recommended.<sup>6</sup> TB meningitis is more common in children with miliary TB (20-40%) than adults with miliary TB (15-30%).<sup>6</sup> In our case, the clues which pointed in favour of an underlying TB focus are: low socioeconomic state of her family, overcrowded family positive family history of open pulmonary TB, positive GLAFB, clinical and radiological hepatosplenomegaly. CT Sharma et al presented a criteria useful for the diagnosis of miliary TB: (i) clinical presentation consistent with a diagnosis of TB such as, fever with evening rise of temperature, weight loss, anorexia, tachycardia and night sweats of greater than six weeks duration responding to anti-TB treatment; (ii) classical miliary pattern on chest radiograph; (iii) bilateral diffuse reticulonodular lung lesions on a background of miliary shadows demonstrable either on plain chest radiograph or high resolution CT; and (iv) microbiological and/or histopathological evidence of TB.<sup>15</sup> The combination clinical and radiological findings along with positive GLAFB and choroid tubercles on fundus examination helped us in early diagnosis and treatment. There are several reports of rapid progression of miliary TB in immunocompromised individuals. We have a similar clinical presentation to that observed in immunocompromised individuals in our patient who is immunocompetent. It needs to be highlighted that although rapid disease progression in miliary TB is not a norm, our patient presented with similar presentation.

## CONCLUSION

In conclusion, a prompt diagnosis and early intervention is key to survival in cases of miliary TB. Given the barriers for prompt microbiological or radiological diagnoses, much emphasis is placed on clinical judgement and this case highlights how important it is to revisit diagnosis and repeat investigations according to the patient's clinical course as in this case patient acutely presented. Systematic approach is required to establish the diagnosis of miliary TB and treatment has to be started as early as possible to reduce the mortality rate.

*Funding: No funding sources*

*Conflict of interest: None declared*

*Ethical approval: Not required*

## REFERENCES

1. World Health Organization. Roadmap for Childhood Tuberculosis: Towards Zero Deaths. Geneva: WHO;

2013. Available at: [http://apps.who.int/iris/bitstream/10665/89506/1/9789241506137\\_eng.pdf](http://apps.who.int/iris/bitstream/10665/89506/1/9789241506137_eng.pdf). Accessed on 10<sup>th</sup> March 2021.
2. Mert A, Arslan F, Kuyucu T. Miliary tuberculosis: epidemiological and clinical analysis of large-case series from moderate to low tuberculosis endemic Country. *Medicine*. 2017;96:e5875.
3. Kapoor VK. Abdominal tuberculosis. *Postgrad Med J*. 1998;74:459-67.
4. De Benedetti ZME, Carranza LB, Gotuzzo HE, Rolando CI. Ocular tuberculosis. *Rev Chilinfecol*. 2007;24:284-95.
5. Hamzaoui A, Yaalaoui S, Cherif FT, Saidi LS, Berraies A. Childhood tuberculosis: a concern of the modern world. *Eur Respir Rev*. 2014;23:278-91.
6. Sharma SK, Mohan A, Sharma A. Challenges in the diagnosis & treatment of miliary tuberculosis. *Indian J Med Res*. 2012;135:703-30.
7. Overview Miliary tuberculosis. *Medscape*. 2019. <https://emedicine.medscape.com/article/221777-overview>. Accessed on 30th November, 2017.
8. Hussey G, Chisholm T, Kibel M. Miliary tuberculosis in children: a review of 94 cases. *Pediatr Infect Dis J*. 1991;10:832-6.
9. Gurkan F, Bosnak M, Dikici B. Miliary tuberculosis in children: a clinical review. *Scand J Infect Dis*. 1998;30:359-62.
10. Hasanzadeh M, Naderi HR, Hoshyar AH, Shabane S, Shahidsales S. Female genital tract tuberculosis presenting as ovarian cancer. *J Res Med Sci*. 2014;19:184-9.
11. Thilothammal N, Krishnamurthy PV, Runyan DK, Banu K. Does BCG vaccine prevent tuberculous meningitis. *Arch Dis Child*. 1996;74:144-7.
12. Parashar D, Kabra SK, Lodha R, Singh V, Mukherjee A. Delhi pediatric TB study group. does neutralization of gastric aspirates from children with suspected intrathoracic tuberculosis affect mycobacterial yields on MGIT culture? *J Clin Microbiol*. 2013;51(6):1753-6.
13. Khan MA, Mirza SH, Abbasi SA, Butt T, Anwar M. Peripheral blood-based polymerase chain reaction in diagnosis of pulmonary tuberculosis. *J Ayub Med Coll Abbottabad*. 2006;18(2):25-8.
14. Shiono T, Abe S, Horiuchi T. A case of miliary tuberculosis with disseminated choroidal hemorrhages. *BJO*. 1990;74:317-9.
15. Sharma SK, Mohan A, Pande JN. Clinical profile, laboratory characteristics and outcome in miliary tuberculosis. *Q J Med*. 1995;88:29-37.

**Cite this article as:** Kumar NS, Naulakha RP, Vashishtha I, Elon N, Pal R et al. Miliary tuberculosis: an atypical presentation. *Int J Contemp Pediatr* 2021;8:1111-3.