

Case Report

Stridor at birth: a diagnostic dilemma

Rajparath Ragu*, Ramkumaar U.

Department of Neonatology, Cloudnine Hospital, Chennai, Tamil Nadu, India

Received: 11 March 2021

Revised: 25 March 2021

Accepted: 26 March 2021

***Correspondence:**

Dr. Rajparath Ragu,

E-mail: rajragu89@gmail.com

Copyright: © the author(s), publisher and licensee Medip Academy. This is an open-access article distributed under the terms of the Creative Commons Attribution Non-Commercial License, which permits unrestricted non-commercial use, distribution, and reproduction in any medium, provided the original work is properly cited.

ABSTRACT

Stridor is a common complaint in neonates. Double aortic arch (DAA) is a congenital anomaly of the aortic arch. It is the most common type of complete vascular ring. When it occurs, the connected segment of the aortic arch and its branches encircle the trachea and esophagus, leading to symptoms related to these two structures. Association with respiratory distress mandates early flexible bronchoscopic examination of the airway. We report here the diagnosis and management of a neonate with double aortic arch that presented as stridor at birth. Persistence of stridor after surgery and its management was highlighted.

Keywords: Double aortic arch, Respiratory distress, Stridor, Vascular ring

INTRODUCTION

Amongst respiratory symptoms, stridor is a very common complication in a full-term neonate. Congenital cardiovascular anomalies are unusual but treatable causes of stridor in the pediatric population.^{1,2} The reported likelihood of aortic vascular rings was 0.3 to 0.6%.¹ Vascular rings thoroughly encircle the trachea as well as esophagus are usually associated with significant airway and esophagus symptoms.³ The double aortic arch was the most common kind of congenital vascular ring anomalies. For the double arch, the paired aortic arteries neglect to remodel properly, which results in two aortic arches each linking the descending as well as ascending aortas.⁴ We report here the diagnosis and management associated with a neonate with double aortic arch which presented as stridor at birth.

CASE REPORT

A full term (39 weeks and 3 days) new born baby presented with stridor and respiratory distress soon after vacuum assisted vaginal delivery. Antenatally baby was diagnosed to have right sided aortic arch. On further

evaluation in Neonatal intensive care unit (NICU) chest X-ray was normal and arterial blood gas (ABG) showed type-2 respiratory failure. Otorhinolaryngologist opinion was obtained and advised for trial feeding via paladai slowly. Paediatric surgeon opinion was obtained and advised for propped up position, tube feeds, prokinetic cover and conduit oesohagogram. Pediatric cardiologist opinion was obtained and baby was confirmed to have right sided aortic arch alone and no other significant abnormality. Patient had persistent worsening stridor on agitation and in awake state. On examination baby tolerated full tube feed, trial paladai was failure and gas analysis was normal on high flow. The baby was not cooperative for MRI scan and for further evaluation CT angiography was done which revealed double aortic arch with incomplete vascular ring. Cardiac thoracic surgeon opinion was obtained and baby was subjected for thoracotomy which showed,

- Double aortic arch encircling the trachea and esophagus
- Left aortic arch was anterior giving raise to LCC and LSA
- Right aortic arch was posterior

- Distal end of left arch was legated distal to the left subclavian artery
- Compression of trachea and esophagus.

The stridor improved after one week post-operatively. At present baby is thriving will with normal development for the age.

DISCUSSION

A double aortic arch is a result of the failure of regression of the right aortic arch. Normally, absorption of the right (posterior) arch occurs between the right subclavian artery along having its junction with the descending aorta. The remnant of the right arch becomes the right innominate artery and leaves a left (anterior) arch in standard development, freeing the trachea as well as esophagus. Failure of this process of absorption within the right arch develop a vascular ring, the esophagus and also trachea is entirely encircled and compressed, resulting in serious respiratory and feeding difficulties.^{5,6} In this case of baby, baby was identified to have a right-sided aortic arch antenatally. Identification of the double aortic arch is generally restricted by limited acoustic windows and also radiologist experience. Since the left arch is a double aortic arch is usually hypoplastic/atretic that will imitate the left brachiocephalic trunk of a right aortic arch.^{7,8} Hence failing to effectively distinguish double aortic arch from right aortic arch is easy to understand and has been determined by others.^{9,10} Therefore, double aortic arch anatomy should be attempted by experienced radiologist and prenatal counseling should be done accordingly.

Flexible bronchoscopy would be the first line of investigation for neonatal stridor. Typical compression of the esophagus and the trachea was visualized by esophagoscopy and bronchoscopy which were indicated for respiratory or feeding difficulties.¹¹ In our case bronchoscopy could not be performed because of limited accessibility of resources. Echocardiography is implemented liberally in evaluating baby for vascular ring anomalies since it might possibly be enough for diagnosis and is much less invasive compared to other modalities.¹² Although the double aortic arch vascular ring anomaly usually happens without related cardiovascular anomalies, echocardiography offers the additional capability to rule out intracardiac anomalies.¹³

Nature of extra-mural obstruction would be best shown by spiral CT scan, MRI or color-coded 3D echocardiogram reconstruction or angiography.¹⁴ Angiography confirms the diagnosis by demonstrating the details of the anomaly.¹⁵ In our study CT angiography revealed double aortic arch with incomplete vascular ring in the baby who is not cooperative for MRI scan.

In our case the baby was subjected for thoracotomy after CT angiography revealed double aortic arch with incomplete vascular ring. Surgical division of the vascular

ring was indicated in patients with symptoms of trachea or esophageal compression, double aortic arch encircling the trachea and esophagus, left aortic arch was anterior giving raise to left coronary cusp (LCC) and left subclavian artery (LSA), right aortic arch was posterior, distal end of left arch was legated distal to the left subclavian artery. After the surgery the stridor improved after one week and at present the baby is thriving will with normal development for the age.

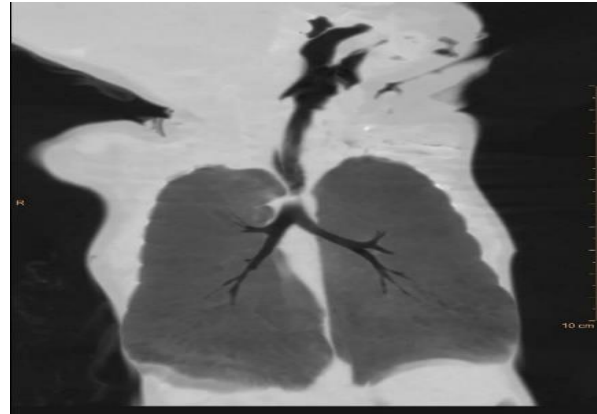


Figure 1: CT chest of compression of trachea.

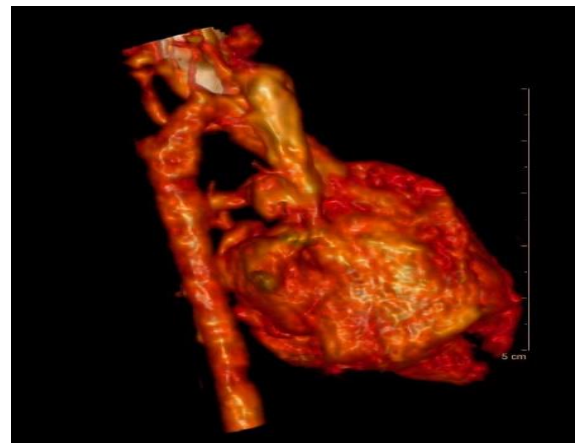


Figure 2: CT angiogram of double sided aortic arch compressing trachea.

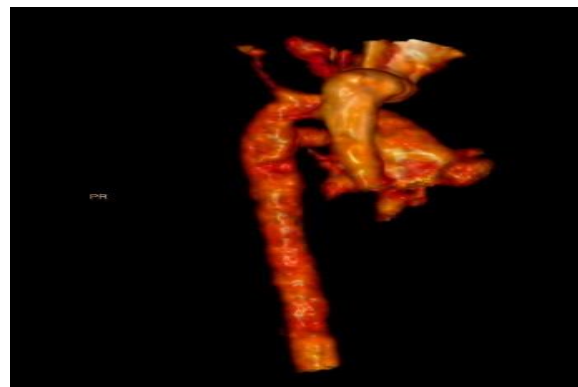


Figure 3: CT angiogram of clear visualisation of double-sided aortic arch.

CONCLUSION

To conclude physicians must always have a suspicion of vascular ring in a baby presenting with stridor at birth. Diagnosis of vascular ring both complete and incomplete to be made precisely with proper radiological examination.

Funding: No funding sources

Conflict of interest: None declared

Ethical approval: Not required

REFERENCES

1. Chan YT, Ng DK, Chong AS, Ho JC. Case Report Double Aortic Arch Presenting as Neonatal Stridor. *HK J Paediatr.* 2003;8(2):126-9.
2. Cesnjevar R, Harig F, Purbujo A, Cuomo M, Blumauer R, Münch F, Alkassar M, Dittrich S. Tracheobronchial Compression by Congenital Vascular Anomalies-Surgical Procedures and Results. *Thorac Cardio Surg.* 2020;68(S1):1-72.
3. Mong DA. Pediatric Thoracic Radiology. In: Pretorius ES and Solomon JA, eds. *Radiology Secrets Plus.* 3rd ed. Elsevier; 2011;413-7.
4. Priya S, Thomas R, Nagpal P, Sharma A, Steigner M. Congenital anomalies of the aortic arch. *Cardiovasc Diagn Ther.* 2018;8(S1):26-44.
5. Tarmahomed A, Umapathi KK. Double Aortic Arch. *StatPearls.* 2020.
6. Hanneman K, Newman B, Chan F. Congenital variants and anomalies of the aortic arch. *Radiographics.* 2017;37(1):32-51.
7. Galindo A, Nieto O, Nieto MT, Rodríguez-Martín MO, Herraiz I, Escribano D, Granados MA. Prenatal diagnosis of right aortic arch: associated findings, pregnancy outcome, and clinical significance of vascular rings. *Prenat Diagn.* 2009;29(10):975-81.
8. Bravo C, Gámez F, Pérez R, Álvarez T, De León-Luis J. Fetal Aortic Arch Anomalies: Key Sonographic Views for Their Differential Diagnosis and Clinical Implications Using the Cardiovascular System Sonographic Evaluation Protocol. *J Ultrasound Med.* 2016;35(2):237-51.
9. Razon Y, Berant M, Fogelman R, Amir G, Birk E. Prenatal diagnosis and outcome of right aortic arch without significant intracardiac anomaly. *J Am Soc Echocardiogr.* 2014;27(12):1352-8.
10. Jain S, Kleiner B, Moon-Grady A, Hornberger LK. Prenatal diagnosis of vascular rings. *J Ultrasound Med.* 2010;29(2):287-94.
11. Daniel M, Cheng A. Neonatal stridor. *Int J Pediatr.* 2012;2012:859104.
12. Mądry W, Karolczak MA, Myszkowski M, Zacharska-Kokot E. Non-invasive diagnosis of aortic arch anomalies in children–15 years of own experience. *J Ultrason.* 2019;19(76):5-8.
13. Umegaki T, Sumi C, Nishi K, Ikeda S, Shingu K. Airway management in an infant with double aortic arch. *J Anesth.* 2010;24(1):117-20.
14. Sahni D, Franklin WH. Vascular Ring Double Aortic Arch. *Stat Pearls.* 2020.
15. Ganie IS, Amod K, Reddy D. Vascular rings: a radiological review of anatomical variations. *Cardiovascular journal of Africa.* 2015;27(1):30-6.

Cite this article as: Ragu R, Ramkumaar U. Stridor at birth: a diagnostic dilemma. *Int J Contemp Pediatr* 2021;8:924-6.