

Case Report

Menorrhagia in a teenager: a rare presentation of paroxysmal nocturnal haemoglobinuria

Salma Sadaf, Pushpalatha Kariyappa*

Department of Paediatrics, Employees' State Insurance Corporation Medical College and Post Graduate Institute of Medical Sciences and Research, Rajajinagar, Bengaluru, Karnataka, India

Received: 22 December 2020

Accepted: 30 January 2021

*Correspondence:

Dr. Pushpalatha Kariyappa,

E-mail: dr.pushpalathaamil@yahoo.in

Copyright: © the author(s), publisher and licensee Medip Academy. This is an open-access article distributed under the terms of the Creative Commons Attribution Non-Commercial License, which permits unrestricted non-commercial use, distribution, and reproduction in any medium, provided the original work is properly cited.

ABSTRACT

Paroxysmal nocturnal hemoglobinuria (PNH) is a rare clonal disorder characterised by complement mediated hemolysis, thrombosis and bone marrow failure due to mutation of PIG A gene on chromosome X which codes for decoy proteins Glycoprotein anchor (CD55 and CD59) on hematopoietic stem cells. Onset of PNH is typically seen in adulthood. Pediatric cases account for 5-10% of all reported cases. It is largely underdiagnosed in children because of varied presentation and atypical symptoms. Here, we report a young girl who presented with menorrhagia and severe pallor which when evaluated unmasked the underlying PNH with aplastic anemia. She underwent a successful hematopoietic stem cell transplant. She has remained asymptomatic for 2 years highlighting the need for early evaluation and management for a better outcome.

Keywords: PNH, Menorrhagia, Teenager, Pancytopenia, Hemoglobinuria, Nocturnal, Aplastic anemia

INTRODUCTION

Paroxysmal nocturnal hemoglobinuria is a non-malignant hematological disease with expansion of hematopoietic stem cells and mature cells which was first described in 1882 by Paul Strübing.¹ It is characterised by a triad of intravascular hemolysis, pancytopenia and thrombosis. Underlying defect in PNH being PIG A gene mutation on chromosome X which codes for glycoprotein anchor (CD55 and CD59) on hematopoietic stem cells and progeny mature cells. This makes cells vulnerable to complement mediated lysis which manifest as thrombosis, renal failure and vascular spasms.

PNH has an incidence of 1 to 10 cases per million population.² The incidence of PNH in India is between 11.8% and 35.3% with mean age of presentation of 34 years usually manifesting as anemia with petechiae, purpura or thrombosis.^{3,4} It is very rarely seen in children and requires a high degree of suspicion, needing timely intervention to prevent life-threatening complications.

CASE REPORT

A 14-year-old girl, resident of Uttar Pradesh, with normal developmental and menstrual history (menarche at 13 years) presented with excessive and prolonged menstrual bleeding associated with easy fatigability from the past 2 months. She also complained of progressive pallor, breathlessness and palpitation since 1 month for which she had received blood transfusion elsewhere. There was history of jaundice 3 months back associated with dark coloured urine with no other bleeding manifestations.

On detailed examination, she was severely pale with no icterus, knuckle pigmentation, petechiae, purpura, lymphadenopathy, koilonychia or bony tenderness. She had mild splenomegaly with spleen measuring 1 cm below left costal margin. Cardiovascular, nervous and respiratory systems were unremarkable. Hence, the probable clinical diagnosis of anemia with pubertal menorrhagia or bleeding disorder were considered.

Initial laboratory tests revealed pancytopenia with low levels of all three cell lines with a normal reticulocyte count. MCV, MCHC, MCH, iron profile and vitamin B12 levels were within normal limits. RFT, LFT, TFT, serum electrolytes, urine analysis, and coagulation profile were within normal limits (Table 1). Peripheral blood smear suggested pancytopenia with no hemoparasite or other abnormal cells (Figure 1). Accordingly, the probable diagnosis of aplastic anemia, myelodysplasia and myelofibrosis were contemplated.

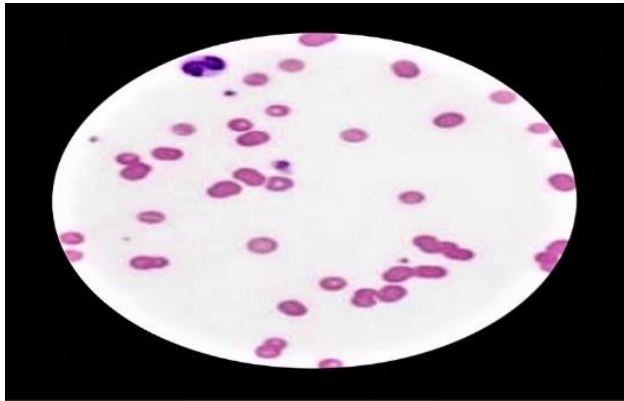


Figure 1: Peripheral blood smear- 100x- suggestive of pancytopenia.

Viral serology (HBV, HCV and CMV load) was negative. Followed by karyotyping, cytoanalysis for myelodysplastic syndrome and ANA profile were all found to be negative. A diagnosis of PNH was considered at this point and Ham test was found positive. To confirm, fluorescein-labelled proaerolysin (FLAER) was done which showed PNH clone in granulocytes (76.1%) and monocytes (84.5%) and RBCs (0.6%), type 2 and 3 being 0.1% and 0.5% respectively. This is diagnostic for PNH (Table 2). Figure 3 illustrates the algorithm followed in the present case (Figure 3).

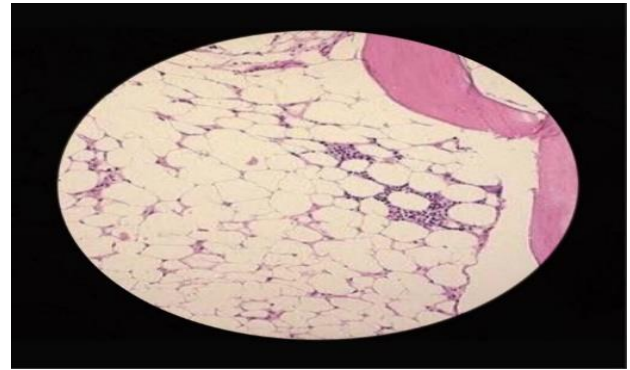


Figure 2: Bone marrow biopsy-100x-suggestive of hypoplastic anemia.

Table 1: Routine laboratory investigations.

Investigation	Result	Investigation	Results
Hemoglobin	3.4g/dL, N-10, L-82, M-11,	Total count	1800/cmm
Differential count	B-0, E-1	Platelet count	51000/dL
PCV	12.5%	Reticulocyte count	3.9%
MCV	97 Fl	MCHC	33.6 g/dL
MCH	32.7 pg	Blood smear	Pancytopenia with no hemoparasite/abnormal cells
Iron profile	Within normal limits		
LFT	Tot Bilirubin-0.3 mg/dL, SGOT-26.6 U/L, ALP-106.7 U/L, S. Protein-6.7 g/dL, S. albumin-3.9 g/dL	Vitamin B12	2.78
		TFT	T3-1.88 ng/mL, T4-9.90, TSH 7.400 mIU/mL
Serum electrolytes	Within normal limits	RFT	Within normal limits
Coagulation profile	pT-11.7s apTT 40.4s, INR-0.93	Urine routine and microscopy	Within normal limits

Table 2: Special investigations.

Investigation	Results
Bone marrow biopsy	Hypocellular bone marrow with erythroid to myeloid ratio of 1:1. Differential distribution of cells are within normal limits. Erythropoiesis is normoblastic. Increased megakaryocytes seen. No hemoparasite or other abnormalities- Suggestive of hypoplastic anaemia
Viral serology-HCV, HBV, CMV load	Negative
Karyotyping (chromosome breakage test on peripheral lymphocytes using mitomycin C and diepoxybutane)	Normal
MDS cytoanalysis	Normal

Continued.

Investigation	Results
ANA screen	0.3 (negative)
Ham test	Positive
Fluorescein-labelled proaerolysin (FLAER)	PNH clone identified in granulocytes (76.1%) and monocytes (84.5%), on RBCs (0.6%) total type 2-0.1%, type 3-0.5%
USG abdomen and pelvis	Unremarkable

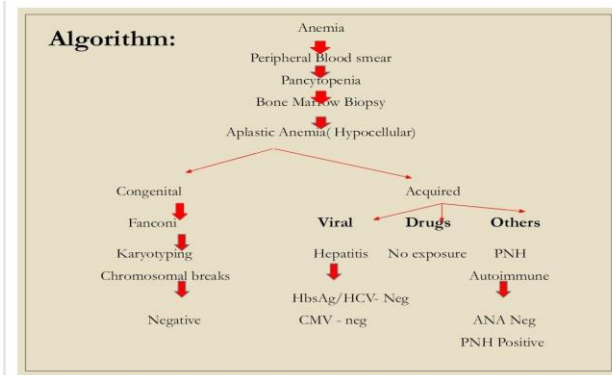


Figure 3: Approach to child with PNH in the present case.

Supportive treatment with transfusion of packed red cells and platelet concentrates was given. It was followed by immunomodulator cyclosporin therapy and continued for 3 months until the child underwent a successful hematopoietic cell transplant from sibling donor after Meningococcal and Pneumococcal vaccination. She has remained symptom free for 2 year.

DISCUSSION

Paroxysmal nocturnal hemoglobinuria is a rare hematological disease in the general population with incidence of 1 to 10 cases per million of total population.² It is extremely rare in children (5-10% of total reported cases) even rarer is manifesting as menorrhagia.

PNH usually presents between 30-50 years of age.⁷ A retrospective study by Schrezenmeier showed that the prevalence of PNH in children below 10 years was 3.8% of all PNH cases in the international paroxysmal nocturnal hemoglobinuria registry.

International PNH interest group has classified PNH into (1) classical PNH (including thrombotic and haemolytic patients); (2) PNH with associated other primary disorders like aplastic anemia or myelodysplastic syndrome; (3) Subclinical PNH without clinical symptoms of hemolysis or thrombosis (usually have small clones).⁸ Classically presenting with triad of intravascular hemolysis, pancytopenia and thrombosis.⁹

Often diagnosis of PNH is made incorrectly in children due to rarity of disease and age at presentation, leading to a mean delay of 19 months from the time of presentation

to diagnosis.⁶ Our child presented first with symptoms of hematuria and menorrhagia 2 months before the diagnosis of PNH was made.

Association of PNH with bone marrow disorders like aplastic anemia is high (43.5%) as theorized by dual pathophysiology theory of PNH.¹⁰ Ware et al in their study reported that associated bone marrow failure was more common in childhood-onset compared to adult-onset with 58 and 25% respectively.⁶

The diagnosis of PNH is essential for effective management and to reduce complications. Flow cytometry is considered gold standard for diagnosis of PNH and associated diseases. Flow cytometry identifies presence of PNH clones and helps in quantification of clone size in RBC's and WBC's (neutrophils and monocytes). The clone size in neutrophils is used to determine the extent of the disease.⁸ Children with PNH have smaller clones than adults according to study by Urbano-Ispizua.⁵

Of all PNH cases, up to 10% present with thrombosis but the incidence is higher as the disease course progresses.¹¹ Cumulative thrombosis incidence is between 23 and 30% (before Eculizumab) over a period of 8-10 years.¹² 31% of children with PNH have been confirmed with venous thrombosis.⁶ The incidence of thrombosis is correlated with granulocyte clone size. Hall et al reported in his study a granulocyte clone size of >50% to have a 44% increased 10-year risk of venous thrombosis.¹³ 50-60% of deaths occur due to thrombosis and pancytopenia. Patients treated inadequately survive for 10-15 years.⁶ In our child, the clone size was not found to be small, increasing the susceptibility of child to developing venous thrombosis. Hence, early diagnosis will not only help modify the outcome of the disease but also decrease the mortality rate.

Treatment depends upon clinical presentation. Transfusion therapy is indicated for correcting significant anemia. Prednisolone in case of acute attacks can ameliorate hemolysis but long-term use can be harmful.⁸ Aplastic anemia is managed with cyclosporine (Cy A) alone with or without antithymocyte globulin. Results are found to be better as a combination (ATG and Cy A).¹⁰ Eculizumab, monoclonal antibody against C5 complement, is proven to decrease the need for blood transfusion and risk of thrombosis but has been found to be more effective in classical PNH patients than PNH associated with bone marrow failure.⁸ The only curative

treatment is allogeneic haematopoietic cell transplantation.

CONCLUSION

PNH is a rare disease with clinical presentations so variable that it can be easily missed when presented at such a young age. As mortality and morbidity secondary to pancytopenia and thrombosis is high it validates the need for early diagnosis and treatment for longer survival and better prognosis. Hence, this study highlights a rare disease manifesting as a rare presentation in an unexpected age group.

Funding: No funding sources

Conflict of interest: None declared

Ethical approval: Not required

REFERENCES

1. Wilmanns J. Paroxysmal nocturnal hemoglobinuria first described in 1882 by Paul Stübing: An example of cooperation between clinical and basic research. *Blut*. 1982;45(6):367-73.
2. Gulbis B, Eleftheriou A, Angastiniotis M, Ball S, Surrallés J, Castella M et al. Epidemiology of rare anaemias in Europe. *Rare Dis Epidemiol*. 2010;375-96.
3. Rahman K, Gupta R, Yadav G, Husein N, Singh M, Nityanand S. Fluorescent Aerolysin (FLAER)-based paroxysmal nocturnal hemoglobinuria (PNH) screening: a single center experience from India. *International J Lab Hematol*. 2017;39(3):261-71.
4. Kashyap R, Awasthi N, Gupta R. Clinical and flow cytometric analysis of paroxysmal nocturnal hemoglobinuria in Indian patients. *J App Hematol*. 2018;9(3):85.
5. Urbano-Ispizua A, Muus P, Schrezenmeier H, Almeida A, Wilson A, Ware R. Different clinical characteristics of paroxysmal nocturnal hemoglobinuria in pediatric and adult patients. *Blood*. 2015;126(23):3341.
6. Ware R, Hall S, Rosse W. Paroxysmal nocturnal hemoglobinuria with onset in childhood and adolescence. *N Eng J Med*. 1991;325(14):991-6.
7. Socié G, Mary J, de Gramont A, Rio B, Leporrier M, Rose C et al. Paroxysmal nocturnal haemoglobinuria: long-term follow-up and prognostic factors. *The Lancet*. 1996;348(9027):573-7.
8. Parker C, Omine M, Richards S, Nishimura J, Bessler M, Ware R et al. Diagnosis and management of paroxysmal nocturnal hemoglobinuria. *Blood*. 2005;106: 3699-709.
9. Rotoli B, Luzzatto L. Paroxysmal nocturnal haemoglobinuria. *Baillière's Clinl Haematol*. 1989;2(1):113-8.
10. Schrezenmeier H, Muus P, Socié G, Szer J, Urbano-Ispizua A, Maciejewski J et al. Baseline characteristics and disease burden in patients in the International Paroxysmal Nocturnal Hemoglobinuria Registry. *Haematologica*. 2014;99(5):922-9.
11. De Latour R, Mary J, Salanoubat C, Terriou L, Etienne G, Mohty M et al. Paroxysmal nocturnal hemoglobinuria: natural history of disease subcategories. *Blood*. 2008;112(8):3099-106.
12. Hall C, Richards S, Hillmen P. Primary prophylaxis with warfarin prevents thrombosis in paroxysmal nocturnal hemoglobinuria (PNH). *Blood*. 2003;102(10):3587-91.

Cite this article as: Sadaf S, Kariyappa P. Menorrhagia in a teenager: a rare presentation of paroxysmal nocturnal haemoglobinuria. *Int J Contemp Pediatr* 2021;8:581-4.