

## Case Report

# Spigelian hernia with bilateral undescended (impalpable) testis in a child: rare scenario

Gaurav Singh\*, Garvita Singh, Satish K. Aggarwal

Department of Paediatric Surgery, Sir Ganga Ram Hospital, New Delhi, India

**Received:** 12 December 2020

**Accepted:** 11 January 2021

### \*Correspondence:

Dr. Gaurav Singh,

E-mail: [gauravpsurg86@gmail.com](mailto:gauravpsurg86@gmail.com)

**Copyright:** © the author(s), publisher and licensee Medip Academy. This is an open-access article distributed under the terms of the Creative Commons Attribution Non-Commercial License, which permits unrestricted non-commercial use, distribution, and reproduction in any medium, provided the original work is properly cited.

### ABSTRACT

Spigelian hernia (SH) is rarely seen in children. Various mechanisms has been described for the co-existence with cryptorchidism. A 4 month old boy, a known case of bilateral impalpable testes and intermittent right lower abdominal swelling was brought to paediatric emergency with complaints of excessive cry, poor feeding and irreducible right lower abdominal swelling - the swelling was a little higher than the usual inguinal hernia. On exploration, SH was seen coming off the deep ring then turning around the conjoint tendon and dissecting between internal oblique and external oblique aponeurosis. The hernia contained oedematous but viable gut with compression over the testicular vessels. Gut was viable. The testes was mobilized and fixed into the scrotum. Left testis was impalpable for which nubbin excision was done at a later date. A SH in the lower abdomen may be confused with a high inguinal hernia. In acute obstruction, emergent exploration and reduction is the cornerstone of treatment.

**Keywords:** Inguinal, Swelling, Hernia, Spigelian

### INTRODUCTION

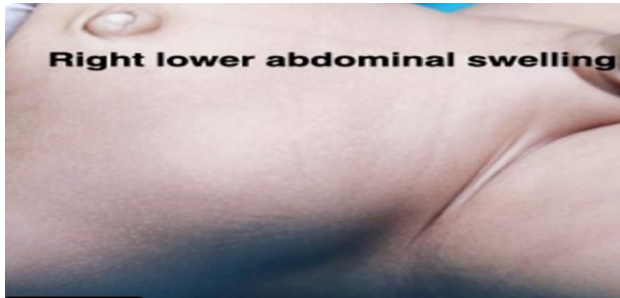
Spigelian hernia (SH) has been described as a disease of the adult and is rare in children. Congenital SH was first described in 1935.<sup>1-3</sup> Its co-existence with cryptorchidism, and different mechanisms thereof, have been described in 31 cases till now.<sup>4</sup> A case of SH in an infant with bilateral impalpable testes is reported. The child presented with irreducible hernia.

### CASE REPORT

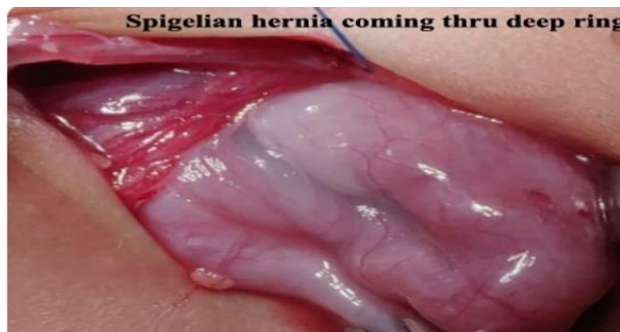A 4 month old boy, a known case of bilateral impalpable testes and intermittent right lower abdominal swelling was brought to paediatric emergency with complaints of excessive cry, poor feeding and irreducible right lower abdominal swelling - the swelling was a little higher than the usual inguinal hernia -lateral to the rectus midway between umbilicus and symphysis pubis (Figure 1). It was tender and the child had features of intestinal obstruction. With a diagnosis of obstructed hernia, emergency

exploration was done through a right inguinal incision. No superficial inguinal ring could be found. On opening the inguinal canal a spigelian hernia was seen coming off the deep ring then turning around the conjoint tendon and dissecting between internal oblique and external oblique aponeurosis (Figure 2). The hernia contained oedematous but viable gut with compression over the testicular vessels (Figure 3). Hernia could not be reduced from inguinal approach. Hence, additional laparotomy was done and reduction was done by push and pull technique by incising on the fascia transversalis to enlarge the deep ring (Figure 4). The gut was viable. A SH was seen coming off the deep ring then turning around the conjoint tendon and dissecting between internal oblique and external oblique aponeurosis. The hernia contained oedematous but viable gut with compression over the testicular vessels. Testicular vessels were oedematous and testis dusky – compressed by hernia. Vas and vessels were mobilized and right testis fixed in the scrotum (Figure 5). Deep ring was narrowed by transversalis fascia repair. The left testis was impalpable. Child was discharged after establishing feeds. Three

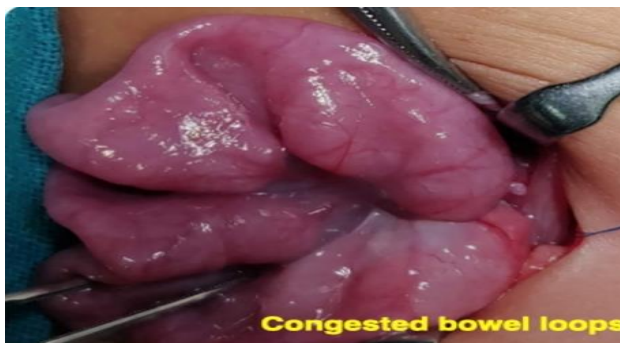months later, a diagnostic laparoscopy was performed for left impalpable testis. Normal looking vas and vessels were seen entering a closed deep ring. On left inguinal exploration a nubbin was found. It was excised and histopathological examination (HPE) revealed atrophied testis but no dysplasia.



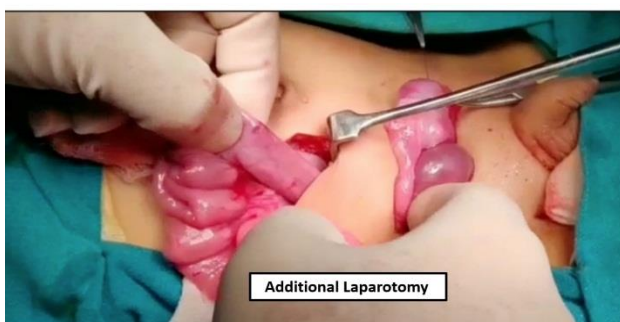**Figure 1: Right lower abdominal swelling.**



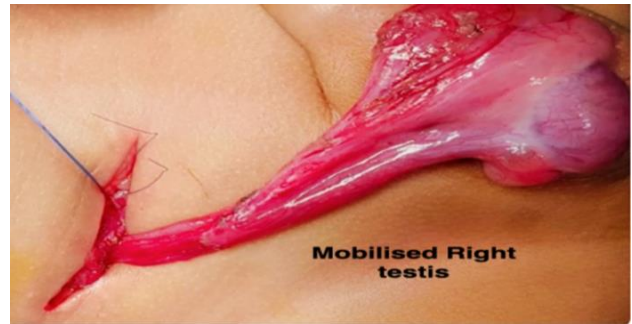**Figure 2: Spigelian hernia coming through deep ring.**



**Figure 3: Congested bowel loops.**



**Figure 4: Additional laparotomy.**



**Figure 5: Mobilized right testis.**

## DISCUSSION

Adrian vander spiegelhel was the first to describe the term semilunar line, extending between the 9<sup>th</sup> costal cartilage and the pubic tubercle. Spigelian fascia is the part of transversus abdominis lying between the lateral border of the rectus abdominis muscle and the semilunar line. A SH is a ventral interstitial hernia through a defect in the spigelian fascia.<sup>5-7</sup> They usually occur below the level of umbilicus, lateral to the junction of the semilunar and arcuate line.<sup>8</sup> The region is also defined as SH belt and comprises the aponeurotic portion of the transverses abdominis muscle.<sup>6,7</sup> This potentially weaker anatomical area is considered to be the underlying cause of high incidence of SH in the particular region.<sup>9</sup>

The existence of ectopic testis with SH has been discussed frequently as a syndromic association with their probable mechanisms. Salem et al hypothesized that the SH pre-exists and the descending testis follows the path of least resistance leading it to an ectopic position.<sup>8</sup> On the contrary a study from Indian subcontinent suggested that an ectopic testis in the spigelian fascia pre-exists and later on it is the increased abdominal pressure for various reasons which leads to development of hernia. However, these hypothesis are yet to be generalized.<sup>10</sup> The present case had bilateral undescended testes and contralateral testis was atrophied which is another complex phenomenon and may be due to antenatal vascular insult leading to a vanished testis. Congenital SH with bilateral undescended testes is extremely rare the present case being only the fifth to be reported in literature.<sup>9</sup>

Diagnostic laparoscopy for the bilateral impalpable UDT is the standard protocol of treatment laparoscopic management of the SH has also been reported.<sup>4</sup> As this child presented with an acute abdomen open exploration was preferred. Ipsilateral orchidopexy was done in the same sitting.

A SH in the lower abdomen may be confused with a high inguinal hernia. Confirmation with an ultrasound in the suspicious cases is the mainstay for diagnosis and further treatment however, in acute obstruction, emergent exploration and reduction is the cornerstone of treatment.

## CONCLUSION

SH is rare in children. An association with ipsilateral undescended testis has been reported previously but bilateral undescended (impalpable) testes and contralateral atrophic/vanished testis is hitherto unreported.

*Funding: No funding sources*

*Conflict of interest: None declared*

*Ethical approval: Not required*

## REFERENCES

1. Singal AK, Ravikumar VR, Kadam V, Jain V. Undescended testis in spigelian hernia – A report of 2 cases and review of the literature. Eur J Pediatr Surg. 2011;21:194-6.
2. Bilici S, Güneş M, Göksu M, Melek M, Piriñçi N. Undescended testis accompanying congenital spigelian hernia: Is it a reason, a result, or a new syndrome? Eur J Pediatr Surg. 2012;22:157-61.
3. Mittal T, Kumar V, Khullar R, Sharma A, Soni V, Baijal M, et al. Diagnosis and management of spigelian hernia: A review of literature and our experience. J Minim Access Surg. 2008;4:95-8.
4. Deshmukh SS, Kothari PR, Gupta AR, Dikshit VB, Patil P, Kekre GA, et al. Total laparoscopic repair of Spigelian hernia with undescended testis. J Min Access Surg 2019;15:265-7.
5. Aird I. Comparison in surgical studies, 2nd edn. Livingston, Edin- burgh London. 1957;652.
6. Graivier L, Bernstein D, RuBane CF. Lateral ventral (spigelian) hernias in infants and children. Surgery. 1978;83:288-90.
7. Spangen L. Spigelian hernia. Surg Clin North Am. 1984;64:351-66.
8. Al-Salem AH. Congenital spigelian hernia and cryptorchidism: cause or coincidence? Pediatr Surg Int. 2000;16(5-6):433-6.
9. Durham MM, Ricketts RR. Congenital spigelian hernias and cryptorchidism. J Pediatr Surg. 2006;41(11):1814-7.
10. Raveenthiran V. Congenital Spigelian hernia with cryptorchidism: probably a new syndrome. Hernia. 2005;9(4):378-80.

**Cite this article as:** Singh G, Singh G, Aggarwal SK. Spigelian hernia with bilateral undescended (impalpable) testis in a child: rare scenario. Int J Contemp Pediatr 2021;8:578-80.