

Case Report

Successful management of a recurrent hepatosplenic metastatic nasopharyngeal carcinoma in an adolescent boy: case report and review of literature

Varsha Ramesh¹, Latha M. Sneha^{1*}, Sushruthan Muralitharan², Dhaarani Jayaraman¹

¹Department of Pediatrics, ²Department of Pathology, Sri Ramachandra Institute of Higher Education and Research, Chennai, Tamil Nadu, India

Received: 06 December 2020

Accepted: 08 January 2021

*Correspondence:

Dr. Latha M. Sneha,

E-mail: drmslatha@yahoo.com

Copyright: © the author(s), publisher and licensee Medip Academy. This is an open-access article distributed under the terms of the Creative Commons Attribution Non-Commercial License, which permits unrestricted non-commercial use, distribution, and reproduction in any medium, provided the original work is properly cited.

ABSTRACT

Nasopharyngeal carcinoma (NPC) is a rare tumor in pediatric age group and adolescents are the commonly affected age group. It generally presents as locoregionally advanced disease and 15-30% of them develop a recurrence or distant metastatic disease. The outcome of patients with recurrent metastatic nasopharyngeal carcinoma has been reported to be very poor, with a median overall survival of about 20 months. We present a case of adolescent boy who presented initially with locally advanced nasopharyngeal carcinoma, treated with local radiotherapy and cisplatin, 5 fluorouracil and later presented with a recurrent metastatic disease in liver and spleen, within 2 months of completing treatment. He was managed with total splenectomy and paclitaxel and gemcitabine and he remains disease free for more than 18 months now. The case highlights that long term remission could be attained with conventional chemotherapy, combined with surgery in relapsed metastatic NPC even in a resource limited settings.

Keywords: Nasopharyngeal carcinoma, Metastatic relapse, Splenectomy, Conventional chemotherapy

INTRODUCTION

Nasopharyngeal carcinoma (NPC) is a rare neoplasm and accounts for 2% of head and neck malignancies in children.¹ We report a case of metastatic relapsed NPC in a 15 year old boy who had advanced locoregional disease at presentation and hepatosplenic recurrence later. He was managed successfully with surgery and chemotherapy and is currently well on follow up.

CASE REPORT

A 16 year old boy presented with complaints of right sided nasal block for 4 months with right sided neck swelling for 2 months. Magnetic resonance imaging (MRI) of the head and neck done elsewhere revealed a nasopharyngeal mass with multiple necrotic nodes in the cervical, prevertebral and parapharyngeal region. Biopsy of the cervical lymph

node was confirmative of undifferentiated nasopharyngeal carcinoma – non keratinizing type. Positron emission tomography-computed tomography (PET CT) done for metastatic evaluation revealed a fluorodeoxyglucose (FDG) avid mass with its epicenter in the right posterolateral wall of nasopharynx of size 44×40×45 mm (SUV max: 9.8) and FDG avid lymph nodes in right parotid, right upper and deep cervical, right supraclavicular and left upper deep cervical regions confirming advanced locoregional disease. He was treated 5 fluorouracil and cisplatin and received 66Gys in 33 fractions to the nasopharynx and cervical lymph nodes. During the course of treatment, he developed radiation induced mucositis and had significant weight loss.

Eight weeks after completion of treatment, PET CT done on routine follow up showed a heterogeneous enhancing lesion of size 20.5×12.7 mm, SUV max 6.1 in segment IV

a of the left lobe of liver and lesion of size 10.2×7 mm, SUV max 4.3 in segment VII of right lobe of liver and lesion of size 65×42.5×43 mm SUV max 11.2 seen in upper pole of spleen and FDG avid lymph nodes at the splenic hilum and peripancreatic region suggestive of distant metastatic relapse (Figure 1a and b).

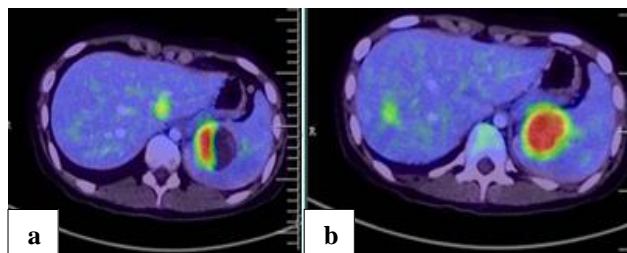


Figure 1: (a) PET CT showing FDG avid enhancing lesion seen in upper pole of spleen and in left lobe of liver and (b) PET CT showing FDG avid lesion in right lobe of liver.

During ultrasonography (USG) guided biopsy of the splenic lesion, an irregular, mixed echoic area measuring 6.8×6.5 cm, with a volume 170 ml was noted, suggestive of a cystic lesion. The aspirate was negative for malignant cells. In view of increasing size of the cystic lesion, a pigtail catheter was inserted and he had a continuous drain of around 500–750 ml daily. As repeated aspirates were negative for malignant cells, USG guided biopsy of the liver lesion was done. It showed sheets of malignant infiltrates in the liver (Figure 2a). He underwent total splenectomy with presplenectomy prophylactic immunization. By Immunohistochemistry, the tumor cells in spleen were positive for epithelial membrane antigen (EMA), Epstein-Barr virus (EBV) and vimentin (Figure 2b). He was started on paclitaxel and gemcitabine and received 6 cycles totally. Nutritional intervention was initiated from the first cycle. He gained 10 kg during the treatment period and did not experience any significant side effects. Currently he is on penicillin prophylaxis.

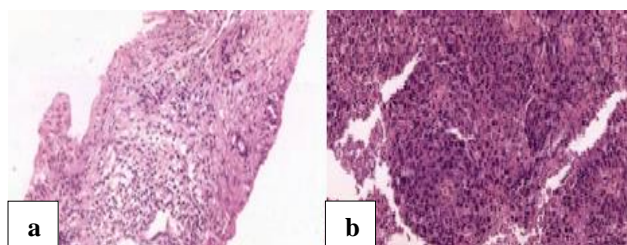


Figure 2: (a) Histological image shows core of liver tissue showing sheets of atypical cells with prominent nucleoli surrounded by desmoplastic stroma, and (b) histological image shows section of spleen with sheets of large cells with prominent nucleoli and moderate amount of cytoplasm.

PET CT done after 6 weeks of chemotherapy showed complete metabolic response and he is currently disease free for more than 18 months.

DISCUSSION

Nasopharyngeal carcinoma (NPC) is a very rare tumor in children and constitutes 2% of head and neck malignant tumors in children. NPC in children varies from its adult counterpart by the prevalence of non-keratinizing undifferentiated forms - a histological subtype that is seen to be associated with advanced locoregional disease and increased rate of distant metastases.² About 5-10% have distant metastases at presentation. Bones (67%), lungs (20%), liver (30%), and bone marrow (23%) are the common sites of metastasis.³

Around 8-10% of those treated for locally advanced NPC will develop recurrent disease and most of them develop distant metastases.⁴ The outcome of recurrent or metastatic NPC is very poor with a median overall survival of about 20 months.⁵ Liver is one of the most common site of metastasis, with an incidence of 29-36% and is usually multifocal with a worse prognosis than metastasis to the lung or bones.

Splenic metastasis is reported only in 1% of NPC.⁶ Splenic metastases are reported to be resulting from the growth of early blood borne disseminated cancer cells within the spleen after a period of clinical latency. They are commonly identified during routine follow ups as more than 60% of them are asymptomatic. Cystic metastatic lesions in NPC are rare. Venkatraman et al has reported multiple metastatic cystic lesions in liver at diagnosis in a 14 year old boy with NPC and the few other cases of cystic metastasis are reported only in adults.⁷ Cystic metastasis are believed to be due to the rapid tumor growth, outstripping its blood supply, leading to central tumor necrosis. Imaging guided percutaneous biopsy of the splenic lesion is considered safe and accurate for diagnosis with a diagnostic yield and accuracy of 90% and 95% respectively.⁸

In splenic metastases, splenectomy is advised as it avoids complications related to progressive increase in metastatic volume and infiltrative spread in the surrounding organs, especially diaphragm and abscess formation. It is considered as a debulking procedure before chemotherapy and could result in longer survival.^{9,10}

Piardi et al has reported 28 cases of splenectomy in solitary isolated metastatic lesions in spleen with no increase in complications or mortality.¹¹ For pediatric patients with relapsed NPC, an oxaliplatin containing regimen in combination with gemcitabine is recommended as a reasonable choice for first line salvage therapy by DeRenzo et al. He has reported a 3 year event free survival of 34% and overall survival of 44% in his study of 14 pediatric relapsed/ progressive NPC cases.¹² Currently no molecular targeted therapy has been approved for treatment of relapsed metastatic NPC. Immunotherapy has proven to be effective in few clinical trials but its use is still experimental. Ma et al has evaluated the efficacy of nivolumab in 44 patients who had progressed after a first

line chemotherapy and reported one year OS and PFS of 59% and 19.3% respectively.¹³.

CONCLUSION

The case report highlights the possibility of attaining disease remission in a relapsed metastatic NPC with chemotherapy and surgery even in a resource limited settings and cystic lesions should be ruled out as metastatic lesions, with a previous history of malignancy.

Funding: No funding sources

Conflict of interest: None declared

Ethical approval: Not required

REFERENCES

1. Cunningham MJ, Myers EN, Bluestone CD. Malignant tumours of the head and neck in children: a twenty year review. *Int J Pediatr Otorhinolaryngol*. 1987;13:279-92.
2. Downing NL, Wolden S, Wong P, Petrik DW, Hara W, Le QT. Comparison of treatment results between adult and juvenile nasopharyngeal carcinoma. *Int J Radiat Oncol Biol Phys*. 2009;75:1064-70.
3. Healy G. Malignant tumors of the head and neck in children: diagnosis and treatment. *Otolaryngol Clin North Am*. 1980;13:483-8.
4. Perri F, Bosso D, Buonerba C, Lorenzo GD, Scarpati GD. Locally advanced nasopharyngeal carcinoma: current and emerging treatment strategies. *World J Clin Oncol*. 2011;2:377-83.
5. Wei WI, Sham JS. Nasopharyngeal carcinoma. *Lancet*. 2005;365:2041-54.
6. Genova P, Brunetti F, Bequignon E, Landi F, Lizzi V, Esposito F, et al. Solitary splenic metastasis from nasopharyngeal carcinoma: a case report and systematic review of the literature. *World J Surg Oncol*. 2016;14:184.
7. Radhakrishnan V, Thulkar S, Karunanithi S, Tanveer N, Bakhshi S. Nasopharyngeal carcinoma with splenic and cystic liver metastases in a pediatric patient: 18F-FDG PET-CT findings. *Pediatr Radiol*. 2010;40(1):79-82.
8. Kraus MDFM, Vonderheide RH. The spleen as a diagnostic specimen. *Cancer*. 2001;91:2001-9.
9. Lee SS, Morgenstern L, Phillips EH, Hiatt JR, Margulies DR. Splenectomy for splenic metastases: a changing clinical spectrum. *Am Surg*. 2000;66:837-40.
10. Sauer J, Sobolewski K, Dommisch K. Splenic metastases—not a frequent problem, but an underestimate location of metastases: epidemiology and course. *J Cancer Res Clin Oncol*. 2009;135:667-71.
11. Piardi T, D'Adda F, Giampaoli F, Pulcini G, Lancini GP, Pouche A. Solitary metachronous splenic metastases: an evaluation of surgical treatment. *J Exp Clin Cancer Res*. 1999;18:575-8.
12. DeRenzo C, Lam C, Rodriguez-Galindo C, Rapkin L, Gottschalk S, Venkataramani R. Salvage regimens for pediatric patients with relapsed nasopharyngeal carcinoma. *Pediatr Blood Cancer*. 2019;66:27469.
13. Ma BBY, Lim WT, Goh BC, Hui EP, Lo KW, Pettinger A, et al. Antitumor activity of nivolumab in recurrent and metastatic nasopharyngeal carcinoma: an international, multicenter study of the Mayo Clinic phase 2 Consortium (NCI-9742). *J Clin Oncol*. 2018;36:1412-8.

Cite this article as: Ramesh V, Sneha LM, Muralitharan S, Jayaraman D. Successful management of a recurrent hepatosplenic metastatic nasopharyngeal carcinoma in an adolescent boy: case report and review of literature. *Int J Contemp Pediatr* 2021;8:386-8.