

## Case Report

# Type-1 Glanzmann's thrombasthenia: a rare cause of epistaxis in a child

Saumil M. Patel<sup>1</sup>, Rekha Thaddanee<sup>1\*</sup>, Ajeet Kumar Khilnani<sup>2</sup>, Gurudas Khilnani<sup>3</sup>

<sup>1</sup>Department of Pediatrics, <sup>2</sup>Department of Otorhinolaryngology, <sup>3</sup>Department of Pharmacology, Gujarat Adani Institute of Medical Sciences and GK General Hospital, Kachchh, Gujarat, India

**Received:** 13 November 2020

**Accepted:** 07 January 2021

### \*Correspondence:

Dr. Rekha Thaddanee,

E-mail: rekhataddanee@gmail.com

**Copyright:** © the author(s), publisher and licensee Medip Academy. This is an open-access article distributed under the terms of the Creative Commons Attribution Non-Commercial License, which permits unrestricted non-commercial use, distribution, and reproduction in any medium, provided the original work is properly cited.

### ABSTRACT

Glanzmann's thrombasthenia (GT) is a rare genetic platelet surface disorder of glycoprotein IIb/IIIa receptor presenting with muco-cutaneous bleeding of varying severity. We are reporting an unusual case of a child presenting with recurrent epistaxis with prolonged bleeding time, moderate thrombocytopenia and giant platelet size. GT was suspected because the platelet aggregation was abnormal with adenosine diphosphate, epinephrine, collagen, and thrombin; but normal with ristocetin. Diagnosis was confirmed by flow cytometry which showed deficiency of platelet membrane receptors CD 41 (Gp IIb) and CD 61 (GpIIIa) with normal expression of CD 42b (GpIb). Platelets transfusions and antifibrinolytics were given to manage bleeding. Due to repeat platelets transfusions patients with GT can develop anti-platelet antibodies for which rFVIIa (recombinant activated factor VII) is effective. Definitive treatment includes stem cell transplant or gene therapy.

**Keywords:** Epistaxis, Glanzmann's thrombasthenia, Platelet transfusion

### INTRODUCTION

Glanzmann's Thrombasthenia (GT) is a rare autosomal recessive platelet disorder. It was first described by Dr. Edward Glanzmann in 1918.<sup>1</sup> Reported incidence of GT is one in million.<sup>2</sup> A higher incidence is seen in families with consanguineous marriages, with equal sex predilection.<sup>3</sup> Patients with GT present with mild to severe mucocutaneous bleeding manifestations.<sup>3</sup> GT is usually characterised by normal platelet number and morphology, although, rarely, moderate thrombocytopenia and giant platelet size are also observed.<sup>4,5</sup> The platelet aggregation is normal with ristocetin but abnormal with physiologic agonists including adenosine diphosphate (ADP), epinephrine, collagen, and thrombin.<sup>5</sup>

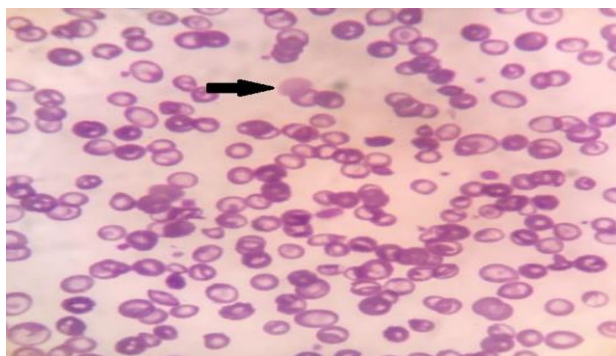
Here, we are reporting a case of GT with unusual features of thrombocytopenia and giant size platelets who presented with epistaxis.

### CASE REPORT

A 4 years old Muslim male child, born of a consanguineous marriage, 2<sup>nd</sup> by birth order, resident of Kutch district; presented to pediatrics outpatient department (OPD) with complaint of recurrent unprovoked epistaxis on and off for two years. On physical examination, severe pallor was present and rest of the examination was normal. Patient had history of similar episodes of epistaxis in the past for which blood was transfused on two occasions. The initial blood investigations showed microcytic hypochromic anemia (hemoglobin i.e. Hb 5 gm %), normal leucocyte count (8000/ml), reticulocyte count (0.6 %), erythrocyte sedimentation rate (ESR) (12 mm/hour), and C-reactive protein (CRP) (<1 mg/dl); and, decreased platelet count (1.2 lakhs per microliter), serum iron (40 mcg/dl), vitamin B12 (150 pg/ml) and folic acid (4 ng/ml) levels. So, the child was transfused 2 units of packed cell volume. Otorhinolaryngology reference was done for epistaxis and

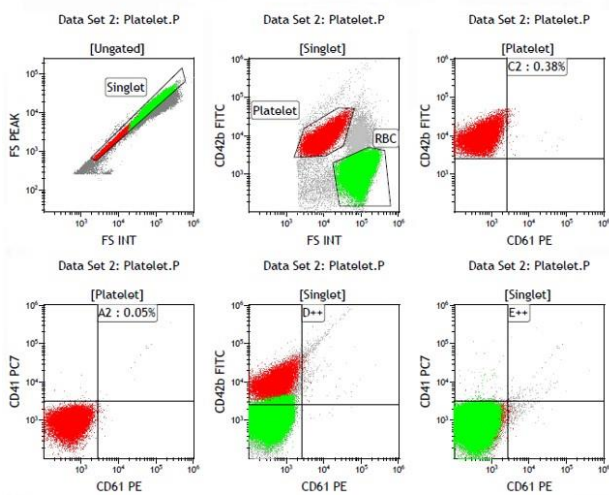
anterior nasal packing was done. Though the severity of bleeding decreased, steady oozing continued along the edges of nasal packs and also in nasopharynx. After 36 hours, once the bleeding stopped, nasal packs were removed and nasal examination done. Nasal endoscopy showed widespread raw nasal mucosa and no mass lesion or focal bleeders. Computed tomographic (CT) scan of nose and para nasal sinuses did not show any abnormality.

The above findings prompted us to search for possible hematological disorders as cause of recurrent epistaxis. A repeat peripheral blood smear examination showed decreased platelet counts (80,000 per microliter) and giant platelets (Figure 1).



**Figure 1: Peripheral blood smear shows giant platelets (black arrow) surrounded by red blood cells (field stain, 1000 X).**

Prothrombin time and activated partial thromboplastin time were normal. Serological evaluation for dengue virus, human immunodeficiency virus (HIV), hepatitis B virus (HBV) and hepatitis C virus (HCV) were negative. Antinuclear antibody (ANA) and anti-dsDNA tests were also negative.



**Figure 2: Flow cytometry platelet analysis showed deficiency of platelet membrane CD 41 (Gp IIb) and CD 61 (GpIIIa) with normal expression of CD 42b (GpIb).**

However, the bleeding time was 13 minutes (prolonged), favoring the diagnosis of functional disorder of platelets. The child again had an episode of epistaxis for which platelet transfusion was done, oral tranexamic acid, iron, vitamin B12 and folic acid were given. Bleeding stopped, thereby, affirming the probable diagnosis of functional disorder of platelets. Ristocetin induced platelets aggregation test was normal but platelet aggregation with ADP, epinephrine and collagen was not seen. Finally, flow cytometry platelet analysis was done which showed deficiency of platelet membrane CD 41 (Gp IIb) and CD 61 (GpIIIa) with normal expression of CD 42b (GpIb) (Figure 2). As expressions of CD 41 and CD 61 were negative, diagnosis of type-1 GT was made.

**DISCUSSION**

GT is a rare autosomal recessive bleeding disorder characterised by defect in platelet aggregation. It is caused by either quantitative or qualitative defect of platelet membrane glycoprotein IIb/IIIa (integrin  $\alpha$ IIB $\beta$ 3) which is essential for platelet aggregation. It is due to genetic defect on ITGA2B or ITGB3 gene on chromosome 17 (12q21).<sup>2</sup> According to integrin  $\alpha$ IIB $\beta$ 3 (CD41/CD61) concentration and its functionality, there are three types of GT. In type I and II, GP IIb/IIIa is either absent or < 5% and 5-20 % of normal respectively. In type III or variant, GP IIb/IIIa is >20% but functionally impaired.<sup>3</sup> Classical GT is characterized by normal platelet numbers, normal platelet morphology, prolonged bleeding time (BT), abnormal clot retraction and absent or decreased platelet aggregation to physiologic agonists like adenosine diphosphate (ADP), epinephrine, collagen, and thrombin but normal platelet aggregation with ristocetin. In our case thrombocytopenia and giant size platelets were present which is unusual of GT but has been reported in some patients.<sup>4,5</sup> In our case, since platelet aggregation was normal with ristocetin, Bernard-Soulier syndrome, which is another platelet function disorder, was excluded.

Severity of bleeding varies in patients with GT. Some patients have mild muco-cutaneous bleeding while others can have life threatening hemorrhage. Common bleeding manifestations are epistaxis (73%), gingival hemorrhage (55%), purpura (86%), menorrhagia (98%); rarely gastrointestinal hemorrhage (12%), hematuria (6%), hemarthrosis (3%), intracranial hemorrhage (2%) and visceral hematoma (1%) are seen.<sup>3</sup> In our case recurrent epistaxis was main manifestation.

Diagnosis of GT is confirmed by flow cytometry in which platelet membrane CD 41 (Gp IIb) and CD 61 (GpIIIa) are decreased with normal expression of CD 42b (GpIb).<sup>6</sup> In our case, CD 41 and CD 61 expressions were negative in flow cytometry so diagnosis of type-1 GT was made. Molecular genetic study can be done to know the site of mutation.<sup>7</sup> Treatment of GT requires platelets transfusion, antifibrinolytics or recombinant activated factor VII (rVIIa) alone or in combination.<sup>8,9</sup> Definitive treatment by stem cell transplant and gene therapy is required in severe

cases.<sup>10</sup> In our case, platelet transfusion and antifibrinolytics were given. Generally, in GT the incidence of severe bleeding decreases with age.<sup>10</sup> During follow up of our patient, two episodes of nasal bleeding occurred during next one year for which antifibrinolytics and platelets transfusion were given.

## CONCLUSION

GT is a rare bleeding disorder, which should be considered as a differential diagnosis in patients with recurrent bleeding manifestations with normal coagulation profile. Rarely, thrombocytopenia or giant platelets can be seen in GT.

*Funding: No funding sources*

*Conflict of interest: None declared*

*Ethical approval: Not required*

## REFERENCES

1. Glanzmann E. Hereditaire Hamorrhagische thrombasthenic. Ein Beitrag Zur Pathologie der Blutplattchen. Jahrbuch Kinderheilkde. 1918;88:1-42.
2. Nurden AT, Caen JP. Specific roles for surface membrane glycoproteins in platelet function. Nature. 1975;255:720-2.
3. George JN, Caen JP, Nurden AT. Glanzmann's thrombasthenia: The spectrum of clinical disease. Blood. 1990;75:1383-95.
4. Nurden AT, Pillois X, Nurden P. Understanding the genetic basis of Glanzmann thrombasthenia: Implications for treatment. Exp Rev Hematol. 2012;5:487-503.
5. Caen JP, Castaldi PA, Lecrec JC, Insmann S, Larrieu MJ, Probst M, et al. Congenital bleeding disorders with long bleeding time and normal platelet count. 1. Glanzmann's thrombasthenia (report of fifteen patients). Am J Med. 1966;41:4-26.
6. Wilcox DA, Wauthier JL, Pidard D, Newman PJ. A single amino acid substitution flanking the fourth calcium binding domain of  $\alpha$ Ib prevents maturation of the  $\alpha$ Ib $\beta$ 3 complex. J Biol Chem. 1994;269:4450-7.
7. Pillitteri D, Pilgrimm AK, Kirchmaier CM. Novel mutations in the GPIIb and GPIIIa genes in Glanzmann Thrombasthenia. Transfus Med Hemother. 2010;37(5):268-77.
8. Santoro C, Rago A, Biondo F. Prevalence of allo-immunization anti-HLA and anti-integrin  $\alpha$ IIb $\beta$ 3 in Glanzmann's thrombasthenia patients. Haemophilia. 2010;16(5):805-12.
9. Poon MC, D'Oiron R, Von Depka M, et al. Prophylactic and therapeutic recombinant factor VIIa administration to patients with Glanzmann's thrombasthenia: results of an international survey. J Thromb Haemost. 2004;2(7):1096-103.
10. Nurden AT, Pillois X, Wilcox DA. Glanzmann thrombasthenia: state of the art and future directions. Semin Thromb Hemost. 2013;39(6):642-55.

**Cite this article as:** Patel SM, Thaddanee R, Khilnani AK, Khilnani G. Type-1 Glanzmann's thrombasthenia: a rare cause of epistaxis in a child. Int J Contemp Pediatr 2021;8:374-6.