

Case Report

Leigh's disease (subacute necrotising encephalo myelopathy): a rare mitochondrial disorder

Sheesham Agarwal*, Nikita Tripathi, Anurag Singh, Suresh Verma

Department of Pediatrics, Dr SNMC, Jodhpur, Rajasthan, India

Received: 08 December 2015

Revised: 15 December 2015

Accepted: 09 January 2016

***Correspondence:**

Dr. Sheesham Agarwal,

E-mail: agarwalsheesham@yahoo.com

Copyright: © the author(s), publisher and licensee Medip Academy. This is an open-access article distributed under the terms of the Creative Commons Attribution Non-Commercial License, which permits unrestricted non-commercial use, distribution, and reproduction in any medium, provided the original work is properly cited.

ABSTRACT

Leigh syndrome is a rare progressive neurodegenerative, mitochondrial disorder of childhood with only a few cases documented from India. Raised lactate levels in blood and/or cerebrospinal fluid along with neuroimaging, mainly the Magnetic Resonance Imaging showing characteristic symmetrical necrotic lesions in the basal ganglia and/or brain stem confirms the diagnosis. MRS can also be used to detect raised level of Lactate. Here, we report a case of 11 months old female child who presented with seizures, delayed milestones and regression of the already achieved milestones with abnormal choreoathetoid movements and dystonia.

Keywords: Leigh's disease, MRI, Magnetic resonance spectrometry

INTRODUCTION

Leigh syndrome is a rare progressive neurodegenerative, mitochondrial disorder of childhood with only a few cases documented from India. The clinical presentation of Leigh syndrome is highly variable. However, in most cases it presents as a progressive neurological disease with motor and intellectual developmental delay and signs and symptoms of brain stem and/or basal ganglia involvement.¹ Raised lactate levels in blood and/or cerebrospinal fluid along with neuroimaging, mainly the magnetic resonance imaging showing characteristic symmetrical necrotic lesions in the basal ganglia and/or brain stem confirms the diagnosis. MRS can also be used to detect raised level of Lactate.² Here, we report a case of 11 months old female child who presented with seizures, delayed milestones and regression of the already achieved milestones with abnormal choreoathetoid movements and dystonia. She had metabolic acidosis and a distant cousin with similar history.³ We suspected it to be a case of neurodegenerative disorder involving basal ganglia. Our initial differential diagnosis included Leigh's disease, biotin responsive basal ganglia disease, pyruvate dehydrogenase deficiency, MELAS and acute

necrotising encephalitis of childhood. Subsequently we were led to a diagnosis of Leigh's disease by MRI and magnetic resonance spectrometry findings which were confirmed by raised CSF and serum lactate levels.⁴

CASE REPORT

An 11 Month old Female child, 2nd issue of a non-consanguineous marriage was admitted in our hospital with chief complain of seizures and failure to thrive. There was a history of developmental delay with regression of milestones. At the time of admission the child's general condition was low and she came in the state of status epilepticus with a GCS of 5. The seizures were in the form of tonic posturing in all the four limbs with repeated episodes at 15 minutes interval. The seizures were not associated with fever and they were resistant to the conventional first line antiepileptic drugs and responded to IV Midazolam infusion. There was a history of regression of achieved milestones in all the domains of the development in the form of loss of social smile, cooing, head control, rolling from supine to prone, sitting with support, eye fixation and following objects up to 180 degree. She had a normal antenatal and perinatal

history, but had a global delay in development. She achieved social smile at 6 months, cooing at 6 months, Hand Regard at 7 months, turning in bed at 10 months and then gradually lost all developmental milestones after that. Presently even social smile is lost. On deep probing it was found that a second degree relative (Aunts Daughter) also had a history of developmental regression, and was wheelchair bound at 6 years of age. Our first suspicion had been a neuroregressive disorder. On general physical examination, there was visible wasting with weight 4.2 kg, microcephaly, HC=40 cm, length 69 cm, with weight for height < - 3 SD (severe acute malnutrition and microcephaly as per WHO standards). The child had long eyelashes and preauricular tags on left side with no facial dysmorphism and no organomegaly. On neurological examination, anterior fontanelle was normal. There was no cranial nerve palsy or focal neurological deficit. There was hypertonia with brisk deep tendon reflexes and choreoathetoid and saccadic eye movements that persisted even after the control of seizures.

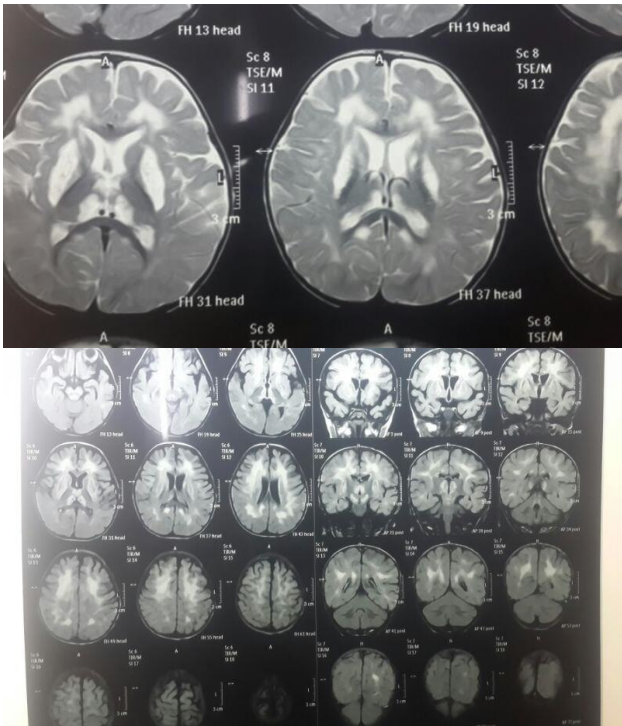


Figure 1: MRI pictures showing hyperdensity in basal ganglia.

In view of choreoathetoid movements with dystonia and developmental regression we suspected involvement of basal ganglia and thus our differentials included Leigh's disease, biotin responsive basal ganglia disease, pyruvate dehydrogenase deficiency, NARP, MELAS and acute necrotising encephalitis of childhood. Absence of ketosis ruled out propionic acedemia. The patient had metabolic acidosis with pH 7.3, without urinary sugar and ketones and with normal blood sugar level. Screening Echo was normal and an ophthalmologic evaluation ruled out

retinitis pigmentosa so the possibility of NARP was ruled out. A normal tandem mass spectrometry ruled out defects of fatty acid oxidation and amino acid metabolism. Thereby we were left with a strong possibility of two disorders: Leigh's disease or Biotin responsive basal ganglia disease. On further work up serum ammonia and lactate were done. The lactate levels were high-66.8(normal<19.8) and thus we performed CSF examination and found that the CSF lactate level was also high -38.0(normal<25). This went against Biotin Responsive Basal Ganglia Disease and there was a strong possibility of Leigh's Disease and thus to confirm the diagnosis MRI with MRS was performed that showed bilateral, symmetrical, hyper intense signals in basal ganglia in T2 weighted image (putamen>globus pallidus) and low signals in T1 weighted image with volume atrophy of both basal ganglia (Figure 1). Magnetic resonance spectrometry showed a markedly increased lactate peak that was almost characteristic of Leigh's disease (Figure 2).

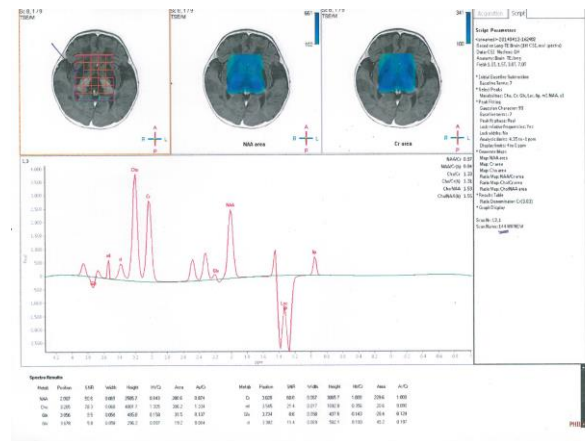


Figure 2: MRS picture showing lactate peak.

Patient was discharged on cocktail therapy consisting of Riboflavin, Thiamine, Biotin, Pyridoxine, Co enzyme Q and Levo-Carnitine and syrup carbamazepine in therapeutic doses with advice of a regular follow up.

DISCUSSION

Leigh's disease or SNE is a rare progressive neurological disorder of the childhood. It was first reported in 1951 by Denis Leigh, a British neuropathologist, in a 7 month old infant that progressed rapidly and resulted in death over a 6-week period.¹ Leigh's disease is usually inherited in an autosomal recessive fashion, and the underlying defect can be at any of a number of sites in the enzyme pathway for respiratory metabolism. Associated mitochondrial enzyme deficiencies are pyruvate carboxylase, pyruvate dehydrogenase, cytochrome C oxidase, and Complex 1 (NAD-Coenzyme Q Reductase) deficiencies.^{2,3} The pathology of SNE is characterized by capillary proliferation with bilaterally symmetric gray and white matter necrosis, spongiform degeneration or vacuolization and demyelination.^{2,4,5}

It presents early in life with psychomotor regression, abnormal muscle tone, weakness, dystonia, brainstem and cerebellar dysfunction (ataxia), visual loss, missed milestones or regression of the achieved milestones, tachypnea and seizures.^{1,2,5} Age of onset of symptoms is usually less than 2 years (infantile form), but others may present in childhood (juvenile form) and unusually in adulthood. Death usually occurs within a few years after onset of symptoms, typically from progressive respiratory failure.^{3,4} Laboratory analysis shows metabolic acidosis with elevated blood, CSF lactate, and pyruvate concentrations.²

The lesions are seen as non-enhancing hypo densities on CT. Low attenuation in the putamina on CT is considered to be characteristic of the disease.^{4,6} MR imaging shows bilateral areas of abnormal high signal intensity on T2 weighted images in the basal ganglia, periventricular white matter, corpus callosum, periaqueductal grey matter and brainstem.^{2,4,5} In the basal ganglia, the putamen is particularly involved. In one series, 100% of the patients with proven SNE had putaminal involvement.²

In our case of this 11 month female child, the patient typically presented with seizures, neuroregression despite an uneventful perinatal history, hypertonia and all these clinical presentations with a family history of a similar 2nd degree relative pointed to a large possibility of an IEM. With the classic CT findings of bilateral symmetrical hypo attenuation of basal ganglia and MRI findings of hyper intense signals in T2 and hypo attenuation in T1 in basal ganglia (putamen>globus pallidus). Elevated serum and CSF

lactate levels and lactate peak on MRS clinched the diagnosis of Leigh's disease.

Funding: No funding sources

Conflict of interest: None declared

Ethical approval: Not required

REFERENCES

1. Leigh D. Subacute necrotizing encephalomyelopathy in an infant. *J Neurol Neurosurg Psychiatry.* 1951;14:216.
2. Medina L, Chi T, DeVivo D. MR findings in patients with subacute necrotizing encephalomyelopathy (Leigh syndrome): correlation with biochemical defect. *AJNR.* 1990;11:379-84.
3. Barkovich AJ. Toxic and metabolic brain disorders. In: *Pediatric Neuroimaging.* New York: Raven Press. 1995:55-106.
4. Geyer CA, Sartor KJ, Prenskey AJ. Leigh disease (subacute necrotizing encephalomyelopathy): CT and MR in five cases. *J Comput Assist Tomogr.* 1988;12:4044.
5. Davis PC, Hoffman JC Jr., Braun IF. MR of Leigh's disease (subacute necrotizing encephalomyelopathy). *AJNR.* 1987;8:71-5.
6. Palteil HJ, O'Gorman AM, Meagher-Villemure K. Subacute necrotizing encephalomyelopathy (Leigh disease): CT study. *Radiology.* 1987;162:115-8.

Cite this article as: Agarwal S, Tripathi N, Singh N, Verma S. Leigh's disease (subacute necrotising encephalo myelopathy): a rare mitochondrial disorder. *Int J Contemp Pediatr* 2016;3:285-7.