

## Case Report

# Incontinentia pigmenti: a rare case of neurocutaneous disorder in the newborn

Himanshu S. Dave<sup>1\*</sup>, Abhishek K. Berwal<sup>2</sup>, Priya M. Patel<sup>3</sup>, Tanushree Joshi<sup>1</sup>

<sup>1</sup>Department of Paediatrics, Northern Railway Central Hospital, New Delhi, India

<sup>2</sup>Department of Paediatrics, Dr. RML Hospital, New Delhi, India

<sup>3</sup>Department of Paediatrics, GMERS Medical College, Himmatnagar, Gujarat, India

**Received:** 24 August 2020

**Accepted:** 02 October 2020

### \*Correspondence:

Dr. Himanshu S. Dave,

E-mail: [davehimanshu08@gmail.com](mailto:davehimanshu08@gmail.com)

**Copyright:** © the author(s), publisher and licensee Medip Academy. This is an open-access article distributed under the terms of the Creative Commons Attribution Non-Commercial License, which permits unrestricted non-commercial use, distribution, and reproduction in any medium, provided the original work is properly cited.

### ABSTRACT

Incontinentia pigmenti (IP) is a rare X linked dominant genetic multisystem neurocutaneous disorder that may affect many organs including the skin, bone, eyes and the central nervous system. Central nervous system manifestations are seen in 30%-40% of cases with seizures and mental retardation. Seizures as the presenting sign of IP in neonates are rarely reported. We report a case of a female newborn with IP who had pleomorphic skin rashes and erythematous vesicles over upper and lower extremities since 5th day of life which were followed by seizures on day 22nd of life. With this case report, we would like to emphasize the need for inclusion of IP in the differential diagnosis of neonatal seizures and to confirm diagnosis of all such unusual skin lesions histologically.

**Keywords:** Bloch-sulzberger disease, Incontinentia pigmenti, Neonatal seizures, Neurocutaneous disorder, X linked

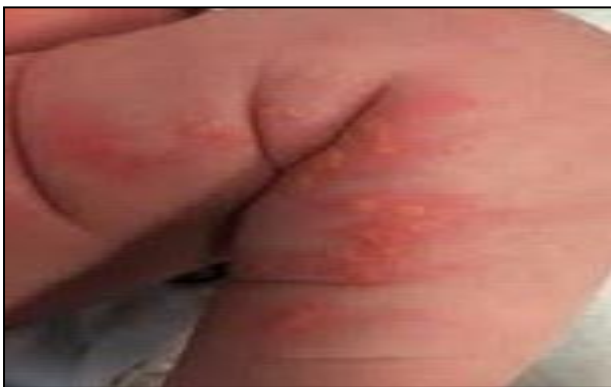### INTRODUCTION

Incontinentia pigmenti (IP), also known as Bloch-Sulzberger disease, is a rare X linked dominant neurocutaneous disorder that is often lethal in male patients.<sup>1</sup> It is a rare genodermatosis which may include disorders of skin, hair, teeth, nail, eye, and Central nervous system (CNS).<sup>2</sup> Dermatological abnormalities are the most prominent manifestations of this disorder, developing through four stages, including vesicular stage, verrucous stage, hyper pigmentation phase, and atrophic phase.<sup>3,4</sup> Although this condition is lethal for the affected males in utero, it presents overwhelmingly in the females as a result of mutant X chromosome inactivation. Lyonization of the X chromosome contributes to the reticular or whorled vesicubullous pathognomonic pattern of IP. It is caused by a mutation in the inhibitor of Nuclear factor kappa B (NF-κB), Kinase subunit gamma (IKBKγ) gene located on Xq28.<sup>5</sup>

The NFκB is crucial for the regulation of tumor necrosis factor-induced apoptosis. Reactivation is believed to occur when specific triggers (possibly infection, fevers, or vaccinations) reactivate pathways in the residual mutant cells.<sup>6</sup> It is now possible to perform molecular analysis of the NF-kappa-B essential modulator (NEMO) gene (codes for nuclear factor κB (NFκB) essential modulator) and skewed X chromosome inactivation. However, the diagnosis of IP is typically based on the characteristic clinical findings. IP is suspected based on characteristic skin eruptions occurring along Blaschko lines. These lesions slowly evolve from erythematous vesicopustules in the neonatal period to hyperkeratosis, verrucous papules, and plaques in infancy followed by hyper pigmentation and then hypo pigmentation.<sup>7</sup> Histopathological evaluation of skin lesions reveal marked eosinophilia.<sup>8</sup> CNS manifestations include seizures, which often start in the first week of life, spastic tetraplegia and diplegia, mental retardation, microcephaly, and Magnetic resonance imaging (MRI) changes.<sup>9,10</sup>

## CASE REPORT

We present a case of female neonate presented at 22nd day of life with right sided focal seizures. A 3.24 kg female child was born via a normal vaginal delivery to a healthy primigravida mother, after an uncomplicated pregnancy at term. The baby cried immediately after birth and was 48.5 cm in length (50-90 percentile) with a head circumference of 34.0 cm (50-90 percentile). Soon breastfeeding was initiated. On 5th day of life skin rashes were noticed by the mother over the lower extremities and groin. The baby was taken to some local physician. On suspecting staphylococcal skin infection, intravenous and topical antibiotics were started by the treating physician. Baby was vitally stable and was accepting feeds well. Few lesions healed and baby was discharged and sent home, as per the history given by the mother. On 22nd day of life the child developed abnormal movements which were confirmed as right sided focal seizures on admission. There was no evidence of hypoxia or hypoglycemia as patient was having normal glucose levels and was maintaining oxygen saturation on room air and there was no history of birth asphyxia. Seizures subsided after the loading dose of phenobarbitone and the baby was having stable vitals. On thorough physical examination we found linear hyper pigmented hyperkeratotic lesions on the upper and lower extremities. Crops of erythematous vesicles were also noticed over the thorax, abdomen and groin and linear hyper pigmented hyperkeratotic lesions were observed on the upper and lower extremities (Figure 1). Complete family history was taken which revealed no significant illness or health issues. There was no history of seizure disorders, mental retardation or sudden death in family.



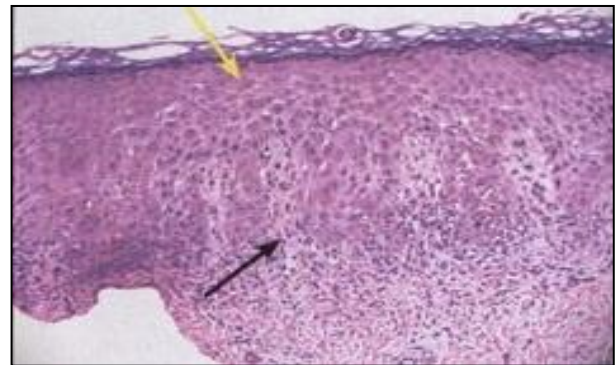
**Figure 1: Skin lesions.**

Complete blood cell (CBC) test and urine workup were done. CBC showed raised total leukocyte counts (22,500/mm<sup>3</sup>) and eosinophilia (14%). C-reactive protein (CRP) was negative. Liver function test, kidney function test and serum electrolytes showed no abnormality. TORCH (Toxoplasma, Rubella, Herpes) screen was negative. Cranial ultrasound was found to be normal. Retinal vascular abnormalities were noted during fundus examination by an ophthalmologist. The

electroencephalogram (EEG) showed epileptiform discharges in the right cerebral hemisphere.

After analyzing the history, clinical features, laboratory parameters, ophthalmic examination and EEG report; common infections and hypoxic ischemic encephalopathy was ruled out. Taking into consideration the multisystem involvement of the disease (mainly skin, CNS and eyes) and the pattern of skin involvement (over Blaschko lines); IP was suspected. Diffusion weighted imaging showed high-signal-intensity lesions in the parietal lobes of the cerebrum suspected of being bilateral non-hemorrhagic infarctions.

Skin biopsy from one of the blisters on lower extremity was taken by the dermatologist. Histopathological examination was done. Hyperkeratosis, spongiosis with eosinophilia, necrotic keratinocytes and dense eosinophilic infiltrates were seen on histological examination of skin (Figure 1). The patient was diagnosed as IP with clinical and histological findings from the skin biopsy.



**Figure 2: Histopathological findings skin biopsy in IP. Black arrow: Eosinophilic spongiosis. Yellow arrow: Dyskeratotic keratinocytes.**

## DISCUSSION

The IP is an X-linked dominant disorder, which is usually lethal in utero for male child. IP is a rare multisystem disease, which is characterized by the abnormalities of the tissues and organs embryonically derived from the ectoderm and neuroectoderm. The pigment melanin is usually located in the melanocytes of the basal epidermal layer; however, this pigment is seen in the superficial layer in the IP.<sup>11</sup> The incidence of IP is very low (approximately 0.0025%).<sup>12</sup> It can be familial or sporadic due to spontaneous mutation; as seems to be in our case. In familial cases abnormalities related to tissues of ectodermal origin (skin, teeth, hair, palate etc.) may be easily seen. Ninety-seven percent of patients are females; the effected males also have Klinefelter syndrome. The mutation is on the NEMO gene on the long arm of X chromosome which results in loss of function of NF kB protein which has a role in cellular proliferation, apoptosis, and pro inflammatory factor regulation.<sup>13</sup> The skin changes (4 stages) occurring in IP represent the major

criteria of this disorder Minic et al published updated diagnostic criteria for IP in 2014.<sup>14</sup> (Table 1) Eosinophilia has been classified as a major diagnostic criteria of IP. Since eosinophilia is not pathognomonic for IP, it may only support the IP diagnosis.<sup>14</sup> Histopathological findings differ according to the phase of the lesions. The first phase manifest with intraepidermal spongiosis with eosinophilic, neutrophilic, and occasionally basophilic inflammatory infiltration. Large dyskeratotic cells are usually present in this phase.<sup>11</sup> The histopathological findings in our patient were compatible with the early phase. The marked eosinophilic skin infiltration, as in our case, is a characteristic finding in IP and has hence been proposed as a minor diagnostic criterion.<sup>8</sup> This eosinophilic infiltration, seen in the early stages of IP, is due to an eosinophil-selective, NF-κB-activated chemokine, eotaxin, which is released in the inflammatory cytokines.<sup>15</sup> Peripheral eosinophilia, which is usually associated with dermal infiltration, was also observed in our case. CNS is the most affected system after the skin in the IP patients, which is involved in about 40% of the case. Our patient showed seizures as the presenting feature along with EEG and MRI changes in brain. Ocular diseases such as microphthalmia, and pigmentary retinal changes may be present in about 30-70% of the IP patients.<sup>16,17</sup> Vision loss has been associated with vascular occlusions, secondary extra retinal neovascularization, fractional retinal detachment, and foveal hypoplasia.<sup>17</sup> Our patient showed retinal vasculopathy. Some reports suggest that abnormalities found in maternal dentition can act as a sensitive indicator of the nature of problems expected in the offspring. Such findings in mother are absent in our case which suggests sporadic nature of disease in this patient with spontaneous mutation.

**Table 1: Diagnostic criteria for IP.**

Major criteria	Minor criteria
<b>Typical skin manifestations distributed along Blaschko's lines:</b>	CNS abnormalities
<b>Stage 1</b>	Ocular abnormalities
<b>Vesiculobullous stage</b>	Dental abnormalities
<b>Stage 2</b>	Alopecia
<b>Verrucous stage</b>	Abnormal hair
<b>Stage 3</b>	Abnormal nails
<b>Hyperpigmented stage</b>	Palate anomalies
<b>Stage 4</b>	Nipple and breast anomalies
<b>Atrophic / Hypopigmented stage</b>	Multiple male miscarriages
	Histopathological findings in skin biopsy

The diagnosis of IP is based on the clinical findings. The differential diagnosis includes neonatal herpes simplex infection, impetigo, neonatal bullous dermatoses, and autoimmune blistering. The skin lesions do not require specific treatment, since spontaneous resolution of the

lesions usually occurs. Bacterial super infection is to be prevented but the use of topical and systemic antibiotics for vesicular lesions is not recommended.<sup>16</sup>

Common differential diagnosis for first stage of IP is congenital herpes simplex which was ruled out in this patient due to absence of history of herpes infection in mother during any stage of pregnancy or just after birth and also by the pattern of skin lesions which non-blaschkoid and non-linear in neonatal herpes.

The diagnosis of IP can be confirmed by the mutation analysis of the IKBKG gene. But even in the absence of genetic studies in resource poor settings of our country, the combination of suspicious blaschkoid skin lesions, CNS manifestations with MRI changes of vasculopathy and eosinophilic skin infiltration in biopsy, is enough to diagnose IP, as per the recent update in the IP diagnostic criteria.<sup>14</sup>

**ACKNOWLEDGEMENTS**

We acknowledge the sincere efforts of Dr. Khushbu Chauahan and Dr. Komal Kapadia from the dermatology section and Dr. Pinkesh Herma from Radiology department. All of them helped a lot in making diagnosis of this case within short period of time.

*Funding: No funding sources*  
*Conflict of interest: None declared*  
*Ethical approval: Not required*

**REFERENCES**

- Ardelean D, Pope E. Incontinentia pigmenti in boys: A series and review of the literature. *Pediatr Dermatol.* 2006;23:523-7.
- Swinney CC, Han DP, Karth PA. Incontinentia pigmenti: A comprehensive review and update. *Ophthalmic Surg Lasers Imaging Retina.* 2015;46:650-7.
- Winterberg DH, Tijn VDA, Smitt JH, Winterberg S, Vomberg PP. Two neonates with vesicular skin lesions due to incontinentia pigmenti. *Ned Tijdschr Geneesk.* 2001;145(45):2178-82.
- Hadj-Rabia S, Froidevaux D, Bodak N, Hamel-Teillac D, Smahi A, Touil Y, et al. Clinical study of 40 cases of incontinentia pigmenti. *Arch Dermatol.* 2003;139(9):1163-70.
- Smahi A, Courtois G, Vabres P. Genomic rearrangement in NEMO impairs NF-kappaB activation and is a cause of incontinentia pigmenti. The International Incontinentia Pigmenti (IP) Consortium. *Nature.* 2000;405(6785):466-72.
- Dupati A, Egbers RG, Helfrich YR. A case of incontinentia pigmenti reactivation after 12-month immunizations. *JAAD Case Reports.* 2015;1(6):351-2.

7. Fusco F, Paciolla M, Conte MI. Incontinentia pigmenti: report on data from 2000 to 2013. *Orphanet J Rare Dis.* 2014;9:93.
8. Hadj-Rabia S, Rimella A, Smahi A. Clinical and histologic features of incontinentia pigmenti in adults with nuclear factor- $\kappa$ B essential modulator gene mutations. *J Am Acad Dermatol.* 2011;64(3):508-15.
9. Hubert JN, Callen JP. Incontinentia pigmenti presenting as seizures. *Pediatr Dermatol.* 2002;19:550-2.
10. Faloyin M, Lewitt J, Bercowitz E, Carrasso D, Tan J. All that is vesicular is not herpes: incontinentia pigmenti masquerading as herpes simplex virus in a newborn. *Pediatrics.* 2004;114:270-22.
11. Rodrigues V, Diamantino F, Voutsen O, Cunha MS, Barroso R, Lopes MJ, et al. Incontinentia pigmenti in the neonatal period. *BMJ Case Rep.* 2011;2011:3708.
12. Scheuerle AE, Ursini MV. Incontinentia pigmenti. In: Pagon RA, Adam MP, Ardinger HH. editors. *GeneReviews*®. Seattle, WA: University of Washington, Seattle. 1993-2016.
13. Narayanan MH, Sampathkumar R, Narayanan V. Handbook of clinical neurology. Incontinentia pigmenti (Bloch-ulzberger syndrome). In: Islam MP, Roach ES, editors. *Handb Clin Neurol.* 2015;132:271-80.
14. Minic S, Trpinac D, Obradovic M. Incontinentia pigmenti diagnostic criteria update. *Clin Genet.* 2014;85:536-42.
15. Jean-Baptiste S, O'Toole EA, Chen M. Expression of eotaxin, an eosinophil-selective chemokine, parallels eosinophil accumulation in the vesiculobullous stage of incontinentia pigmenti. *Clin Exp Immunol.* 2002;127(3):470-8.
16. Poziomczyk CS, Recuero JK, Bringhenti L, Maria FD, Campos CW, Travi GM, et al. Incontinentia pigmenti. *An Bras Dermatol.* 2014;89(1):26-36.
17. Basilius J, Young MP, Michaelis TC, Hobbs R, Jenkins G, Hartnett ME. Structural abnormalities of the inner macula in incontinentia pigmenti. *JAMA Ophthalmol.* 2015;133(9):1067-72.

**Cite this article as:** Dave HS, Berwal AK, Patel PM, Joshi T. Incontinentia pigmenti: a rare case of neurocutaneous disorder in the newborn. *Int J Contemp Pediatr* 2020;7:2239-42.