

Original Research Article

Retinopathy of prematurity- clinical profile on incidence, risk factors and outcome

Purva Shah, Ketan Gadhvi*, Bharat Muliya

Department of Pediatrics, C. U. Shah Medical College and Hospital, Surendranagar, Gujarat, India

Received: 16 August 2020

Accepted: 16 September 2020

***Correspondence:**

Dr. Ketan Gadhvi,

E-mail: dketangadhvi30@gmail.com

Copyright: © the author(s), publisher and licensee Medip Academy. This is an open-access article distributed under the terms of the Creative Commons Attribution Non-Commercial License, which permits unrestricted non-commercial use, distribution, and reproduction in any medium, provided the original work is properly cited.

ABSTRACT

Background: Retinopathy of prematurity is one of the important causes of preventable blindness in the world. Thereby timely screening, diagnosis and hence treatment is of utmost importance.

Methods: This study was done in the neonatal intensive care unit of tertiary hospital, Surendranagar. Study design being observational, data collected from clinical examination and records of the preterm babies <34 weeks and low birth weight babies <1.5 kg and further screened them for retinopathy of prematurity. The incidence of ROP in the neonatal intensive care unit (NICU), risk factors which predispose to ROP (Retinopathy of prematurity) and outcome of these cases were analysed.

Results: As per this study, ROP was found to be more common in <30 weeks gestation and <1 kg neonate, and found to be associated with oxygen exposure, blood product use, antenatal steroids and surfactant.

Conclusions: The analysis of the incidence and risk factors, will henceforth help in identifying and acting on time, thereby improving overall outcome of the preterm and low birth weight new-borns.

Keywords: Dexamethasone, Low birth weight, Oxygen, Preterm, Retinopathy of prematurity, Respiratory distress syndrome, Surfactant

INTRODUCTION

Retinopathy of prematurity (ROP) is a disease process mostly reported in preterm neonates with a wide spectrum, ranging from mild, transient changes in the retina with regression to severe progressive vasoproliferation, scarring, detachment of retina and blindness. If identified early, it can be treated successfully.^{1,2,3}

ROP is characterized by abnormal neovascular development in the retina of premature infants. These abnormal blood vessels are fragile and can leak or bleed, scarring the retina and pulling it out of position. This causes a tractional retinal detachment, which is the main cause of visual impairment and blindness in ROP.^{4,5,6}

The stages of ROP describe the ophthalmoscopic findings at the junction between the vascularized and avascular retina; stage 1 is a faint demarcation line, stage 2 is an elevated ridge, stage 3 is an extraretinal fibrovascular tissue, stage 4 is a subtotal retinal detachment, while stage 5 is a total retinal detachment. In addition, plus disease, which indicates significant vascular dilation and tortuosity observed at the posterior retinal vessels, may be present at any stage and reflects the increased blood flow through the retina.⁷

In 1942, Terry first described retrolental fibroplasia with implication of oxygen therapy as the causative agent. However, reports have found ROP in cases without oxygen therapy and even after oxygen therapy, not all premature infants develop ROP.^{8,9} Three factors have

shown consistent and significant association with ROP: low gestational age, low birth weight and prolonged exposure to supplementary oxygen following delivery.¹⁰

Other putative risk factors include mechanical ventilation, sepsis, intraventricular hemorrhage, surfactant therapy, anemia, frequent blood transfusions, and apnea.¹⁰⁻¹⁴ The precise roles of these factors individually in the progression of the disease have not yet been determined.¹⁵

The study was hence carried out to study the prevalence of ROP, identified through screening and thereby improving the outcome.

METHODS

Our study was a hospital based observational study, done in newborn intensive care unit of tertiary care hospital, Surendranagar, Gujarat. The study included newborns admitted in NICU between January 2019 and December 2019.

The newborns included pre terms <34 weeks, and birth weight <1.5kg (subjected at 4weeks or more of life).

Babies with ocular disorder which interfere with fundus examination and babies with congenital retinal abnormalities, were not included.

The concerned neonates were then screened for ROP after dilatation of pupils and examining by indirect ophthalmoscope. The extent of vascularization was noted. The positive newborns, were then differentiated by their various associations like oxygen exposure, antenatal steroids, surfactant and other clinical profile as mentioned in results section.

Statistical methods

The study was conducted in neonatal intensive care unit (NICU) of tertiary healthcare centre, CUSMC, Surendranagar. Target population being newborns admitted in our NICU fulfilling the above-mentioned inclusion criteria. Data thereby collected was analyzed using mean, standard deviation and percentage analysis.

Ethical clearance

CUSMC/IECSRCS(CR)14/2020/14/2776/20

RESULTS

Out of the 90 newborns screened, 35 came to be positive, with maximum being in stage 1 (Table 1) (Figure 1). ROP was found to be more common in <30weeks maturity newborns (Table 2). ROP was again found to be more common in <1kg newborns (Table 3). Among the ROP positive newborns, most newborns had oxygen exposure (Table 4).

Table 1: Incidence.

Total screened	90	
ROP+ve	35	
ROP-ve	55	
Stage	Number	Incidence
Stage 1	23	66%
Stage 2	8	23%
Preplus (stage 2)	6	75%
Plus (stage 2)	2	25%
Stage 3	3	8%
Stage 4	1	3%
Stage 5	0	0%
Total	35	-

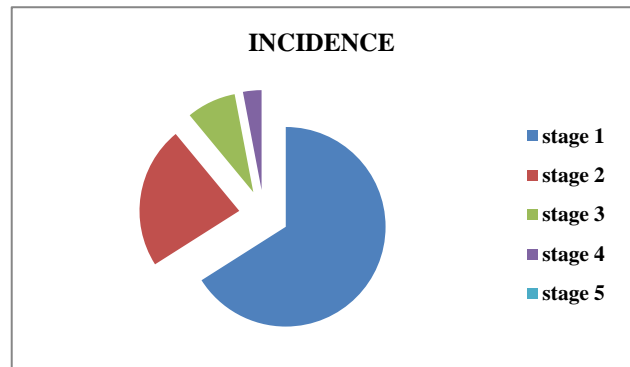


Figure 1: Incidence.

Table 2: According to gestational age.

Gestational age	ROP+ve
28-30 weeks	22 (63%)
31-34 weeks	13 (37%)
Total	35 (100%)

Table 3: Birth weight and ROP.

Birth weight	Rop+ve
<1 kg	22 (63%)
1-1.5 kg	13 (37%)
Total	35 (100%)

Table 4: Supplemental oxygen and ROP.

Supplemental oxygen	ROP+ve
Oxygen given	28 (80%)
Oxygen not given	7 (20%)
Total	35 (100%)

In the same way, blood products were found to be contributing for development of ROP. Exchange transfusion (6%), septicemia (20%), PDA (5%), hyperbilirubinemia (31%) were not found to be significant factors influencing development of ROP (Table 5).

Table 5: Blood product use and rop.

Blood products	ROP+ve
Used	24 (69%)
Not used	11 (31%)
Total	35 (100%)

Majority of ROP positive newborns had apnea episodes (Table 6). Majority of ROP patients, had respiratory distress syndrome (Table 7).

Antenatal steroids seem to play a role in decreasing incidence of ROP (Table 8). Out of 35 positive patients, 10 were given surfactant (Table 9).

Table 6: APNEA and ROP.

APNEA	ROP
Present	23 (66%)
Absent	12 (34%)
Total	35 (100%)

Table 7: RDS and ROP.

RDS	ROP+ve
Present	26 (74%)
Absent	9 (26%)
Total	35 (100%)

Table 8: Dexamethasone to mother and ROP.

Steroid to mother	Rop+ve
Given	6 (17%)
Not given	29 (83%)
Total	35 (100%)

Table 9: Surfactant and ROP.

Surfactant	ROP+ve
Given	10 (28.5%)
Not given	15 (71.5%)
Total	35 (100%)

DISCUSSION

Newborns with birthweight <1500g and <34 weeks were screened for ROP. In a recent article, Chawla et al have suggested the same screening criteria.⁹ As reported by Palmer et al, incidence and severity of ROP was closely related to lower birthweight and lower postconceptional age, as was seen in this study.²⁹

As regard the effect of low-gestational age on occurrence of ROP, we found it the most important risk factor in ROP. This was in agreement with the results of studies done by Shah et al, Karna et al, and Fortes et al.^{11,13,22} This was explained by immaturity of vascularization that induces an increased susceptibility of the retina to

oxidative damage and to a number of perinatal factors which include hyper and hypoxia, blood transfusions, and sepsis. Same comparisons were seen in this study.

Many risk factors have been reported to predispose to the development of ROP. Oxygen therapy, anemia, double volume exchange, packed cell volume transfusion, septicemia, apnea and clinical sepsis are important risk factors.^{10,13,17,18} In this study, oxygen administration, apnea, blood product transfusion were found to be significant risk factors.

Oxygen therapy was an independent risk factor for the development of ROP.^{11,17,28}

In this study, we found that the frequency of blood transfusions is an independent risk factor for development of ROP, and this agreed with Deepak et al.³² This can be explained by the fact that, adult RBCs are rich in DPG and adult hemoglobin which binds less firmly to oxygen, thus releasing excess oxygen to the retinal tissue.^{2,3}

This study observed a significant relation between respiratory distress syndrome and the development of ROP and related this to the fact that systemic hypoxia results in retinal hypoxia and more need for oxygen therapy. Seiberth et al found surfactant a significant risk factor.³⁴

In this study, surfactant was found to be an important factor, with lesser incidence in newborns with surfactant therapy.

CONCLUSION

Since ROP is essentially asymptomatic in the early stages, standards of practice now demand carefully timed retinal examination of at-risk infants for ROP by an ophthalmologist experienced in the examination of the retina, to minimize the risks of visual loss by these infants.

The data of this study suggest that low gestational age, oxygen therapy, frequency of blood transfusions, RDS, surfactant therapy, dexamethasone to mother are independent risk factors in the development of ROP. Doctors should take care of the presence of the additional risk factors when monitoring preterm infants. The analysis of risk factors for ROP development will help to understand and predict it in severe preterm infants.

The timely retinal screening of high-risk preterm infants is important to prevent the development of ROP.

Since ROP may produce serious sequelae up to complete blindness, all efforts must be made to prevent the development of advanced ROP through elimination of preterm births, changes in the neonatal care, and improvement in detection of threatening ROP markers.

Funding: No funding sources

Conflict of interest: None declared

Ethical approval: CUSMC/IECSRCS(C/HR)14/2020/14/2776/20

REFERENCES

- Coats DK, Aaron MM, Mohamed AH. Involution of retinopathy of prematurity after laser treatment: Factors associated with development of retinal detachment. *Am J Ophthalmol.* 2005;140:214-22.
- Fleck BW, Dangata Y. Causes of visual handicap in the Royal Blind School, Edinburgh, 1991 *Br J Ophthalmol.* 1994;78:421.
- Dominico R, Davis K, Davis O. Documenting the NICU design dilemma: Comparative patient progress in open-ward and single family room units. *J Perinatol.* 2011;31:281-8.
- Akçakaya A, Yaylali S, Akçay G. Screening for retinopathy of prematurity in a tertiary hospital in Istanbul: Incidence and risk factors. *J Pediatr Ophthalmol Strabism.* 2011;15:1-5.
- Fanaroff AA, Martin RJ, editors. Neonatal perinatal medicine. 7th ed. Louis: Mosby; 2002.676-745.
- Azad R, Chandra P. Retinopathy of prematurity. *J Indian Med Assoc.* 2005;103:370-2.
- International Committee for the Classification of Retinopathy of Prematurity. The International Classification of Retinopathy of Prematurity revisited. *Arch Ophthalmol.* 2005;123:991-9.
- Terry TL. Extreme prematurity and fibroblastic overgrowth of persistent vascular sheath behind each crystalline lens. *Am J Ophthalmol.* 1942;25:203-4.
- Chawla D, Agarwal R, Deorari A. Retinopathy of prematurity. *Indian J Pediatr.* Indian J Pediatr. 2008;75:73-6.
- Kim T, Sohn J, Yoon YH. Postnatal risk factors of retinopathy of prematurity. *Paediatr Perinat Epidemiol.* 2004;18:130-4.
- Shah VA, Yeo CL, Ling YL. Incidence, risk factors of retinopathy of prematurity among very low birth weight infants in Singapore. *Ann Acad Med Singapore.* 2005;34:169-78.
- Gupta VP, Dhaliwal U, Sharma R. Retinopathy of prematurity-risk factors. *Indian J Pediatr.* 2004;71:887-92.
- Karna P, Muttineni J, Angell L. Retinopathy of prematurity and risk factors: A prospective cohort study. *BMC Pediatr.* 2005;5:18.
- Englert A, Saunders A, Purohit D. The effect of anemia on retinopathy of prematurity in extremely low birth weight infants. *J Perinatol.* 2001;21:21-6.
- Imren A, Sibel O, Gursel Y. Risk Factors in the development of mild and severe retinopathy of prematurity. *J Americ Assoc Pediat Ophthalmol Strabis.* 2006;10:449-53.
- American Academy of Pediatrics Section on Ophthalmology; American Academy of Ophthalmology; American Association for Pediatric Ophthalmology and Strabismus. Screening examination of premature infants for retinopathy of prematurity. *Pediatr.* 2006;117:572-6.
- Taqi AM, Syed R, Chadry TA. Retinopathy of prematurity: Frequency and risk factors in a tertiary care hospital in Karachi, Pakistan. *J Pak Med Assoc.* 2008;58:186-90.
- Chen Y, Li X-x, Yin H, Gilbert C, Liang JH, Jiang YR, et al. Risk factors for retinopathy of prematurity in six neonatal intensive care units in Beijing, China. *Br J Ophthalmol.* 2008;92:326-30.
- Fortes JB, Barros CK, Lermann VL. Prevention of blindness due to retinopathy of prematurity at hospital de clinicas de porto alegre, Brazil: Incidence, risk factors, laser treatment and outcomes from 2002 to 2006. *Acta medica Lituanica.* 2006;13:130-6.
- Dammann O, Brinkhaus MJ, Bartels DB. Immaturity, perinatal inflammation, and retinopathy of prematurity: A multi-hit hypothesis. *Early Hum Dev.* 2009;1016:1-5.
- Fortes JB, Eckert GU, Procianny L. Incidence and risk factors for retinopathy of prematurity in very low and in extremely low birth weight infants in a unit-based approach in southern Brazil. *Eye (Lond).* 2009;23:25-30.
- Arroe M, Peitersen B. Retinopathy of prematurity: Review of a seven year period in a Danish neonatal intensive care unit. *Acta Paediatr.* 1994;83:501-5.
- Roberto F, Miguel AH, Ricardo JH. Screening for retinopathy of prematurity: Results of a 7-year Study of underweight newborns. *Arch Med Res.* 2007;38:440-3.
- Vinekar A, Dogra M, Sangtam T. Retinopathy of prematurity in Asian Indian babies weighting greater than 1250 gram at birth; ten years data from tertiary care center in a developing country. *Indian J Ophthalmol.* 2007;55:331-6.
- Chaudhari S, Patwardhan V, Vaidya U. Retinopathy of prematurity in a tertiary care center, incidence, risk factors and outcomes. *Indian Pediatr.* 2009; 46:219-24.
- Smith LE. Pathogenesis of retinopathy of prematurity. *Acta Paediatr Suppl.* 2002;91:26-8.
- Weinberger B, Laskin DL, Heck DE. Oxygen toxicity in premature infants. *Toxicol Appl Pharmacol.* 2002;181:60-7.
- Palmer AE, Hardy RJ, Dobson V Cryotherapy for Retinopathy of Prematurity Cooperative Group. Outcomes following Threshold Retinopathy of Prematurity. Final results from the multicenter trial of cryotherapy for retinopathy of prematurity. *Arch Ophthalmol.* 2005;123:311-8.
- Ikeda H, Kuriyama S. Risk factors for retinopathy of prematurity requiring photocoagulation. *Jpn J Ophthalmol.* 2004;48:68-71.
- Dutta S, Alaraop S, Narang A. Risk factors of threshold retinopathy of prematurity. *Indian Pediatr.* 2004;41:665-71.

31. Deepak C, Ramesh A, Ashok KD. Retinopathy of prematurity. *Indian J Pediatr.* 2008;75:73-6.
32. Hirano K, Morinobu T, Kirn H. Blood transfusion increases radical promoting non-transferrin bound iron in preterm infants. *Arch Dis Child Fetal Neonatal Ed.* 2001;84:188-93.
33. Darlow A, Hutchinson JL, Henderson S. Prenatal risk factors for severe retinopathy of prematurity among very preterm infants of the Australian and New Zealand Neonatal Network. *Pediatrics.* 2005;115:990-6.
34. Seiberth V, Lindarkomp O. Risk factors in retinopathy of prematurity: A multivariate statistical analysis. *Ophthalmologica.* 2000;214:131-5.

Cite this article as: Shah P, Gadhvi K, Muliya B. Retinopathy of prematurity- clinical profile on incidence, risk factors and outcome. *Int J Contemp Pediatr* 2020;7:2189-93.