

Case Report

Giant fetal lymphangioma with non-immune hydrops fetalis

**Jerin Monisha Paul, Prabhukumar Sakthigirisamy, Ilangumaran Lakshmanan*,
Sucindar Mullainathan, Saravanan Sambandam**

Department of Pediatrics, Rajah Muthiah Medical College Hospital, Chidambaram, Tamil Nadu, India

Received: 15 August 2020

Accepted: 11 September 2020

*Correspondence:

Dr. Ilangumaran Lakshmanan,
E-mail: drila1985@gmail.com

Copyright: © the author(s), publisher and licensee Medip Academy. This is an open-access article distributed under the terms of the Creative Commons Attribution Non-Commercial License, which permits unrestricted non-commercial use, distribution, and reproduction in any medium, provided the original work is properly cited.

ABSTRACT

Fetal lymphangioma is one of the rarest congenital malformation occurring in the newborn. We are reporting a giant fetal lymphangioma which may be the largest one so far reported in medical literature and its association with non immune hydrops fetalis. A late preterm 35+3 weeks gestation female neonate with birth weight of 3.8 kg was delivered via emergency caesarean section, for prevention of birth injuries in view of large for gestation. Baby had weak cry at birth. On examination a giant cystic mass extending from right hemithorax to right anterolateral abdominal wall measuring 25×12.5×9 cm was present. Systemic examination revealed respiratory distress and ascites. Neonate was admitted in NICU and started on supportive measures, despite which went into cardio respiratory arrest at second hour of life and revived with Cardiopulmonary resuscitation. Baby had second cardiopulmonary arrest at 9 hours of life and couldn't be revived. Antenatal ultrasound showed massive ascites, bilateral pleural effusion with cardiomegaly and multiseptated cystic swelling over right chest wall. Based on clinical and antenatal findings we made a diagnosis of Giant fetal lymphangioma with non-immune hydrops fetalis. Giant fetal lymphangioma is an antenatal diagnosis. Its association with non-immune hydrops fetalis is a bad prognostic indicator with high mortality.

Keywords: Fetal, Giant, Hydrops fetalis, Lymphangioma, Septate

INTRODUCTION

Fetal lymphangioma is one of the rarest congenital malformations seen in newborns. It is characterised by a thin walled cystic dilatation of lymphatic system due to complete or partial obstruction in the lymphatic channels. Most common site is posterior neck.¹ The incidence is 1/6000-16000 live birth.² According to literature, lymphangioma occurring over chest wall is uncommon and is mostly seen in later gestation.³ Lymphangiomas are classified into septate and non-septate, where septate and non-septate lymphangioma indicate complete and incomplete lymphatic obstruction respectively.⁴ Failure of lymphatic sacs to connect or drain into jugular veins causes lymphatic fluid stasis and eventually develops hydrops fetalis. Hydrops fetalis is presence of extracellular fluid in at least two fetal body compartments

like pleural, pericardial, peritoneal, skin edema with thickness >5 mm.⁵ We report a live female neonate with giant septate lymphangioma present over right chest and abdominal wall with features of non-immune hydrops fetalis.

CASE REPORT

A female neonat first born to non consanguineous marriage to 25 year old Rh+ve primigravida of gestation 35+3 weeks, with birth weight of 3.8 kg was delivered via emergency LSCS, for prevention of birth injuries in view of large for gestation. Baby had a weak cry at birth. APGAR at 1 and 5 minutes were 5/10 and 6/10 respectively. On examination, large cystic, non-pulsatile, transilluminate mass measuring 25×12.5×9 cm extending from right anterolateral hemithorax to right anterolateral

abdominal wall was present (Figure 1). No other external congenital anomalies were noted. Respiratory system examination revealed absent air entry over right hemithorax and reduced air entry over left hemithorax. Abdomen was uniformly distended, shiny with ascites. Bowel sounds were heard. Other systemic examinations were uneventful and were admitted in NICU.

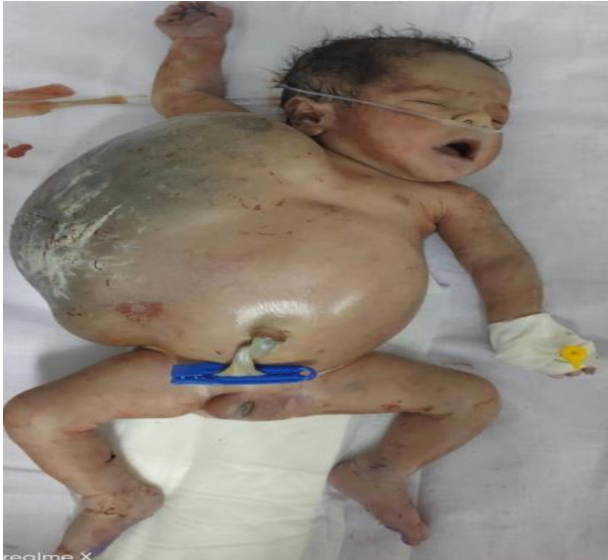

Figure1: Giant lymphangioma.

During NICU stay, neonate had respiratory distress and was started on CPAP with supportive measures. Baby went in for cardiopulmonary arrest at second hour of life and was revived with cardiopulmonary resuscitation, intubated and connected to mechanical ventilator. Intensive care support was continued. X-ray chest with abdomen revealed huge radio opaque mass over right hemithorax and abdomen with evidence of pleural effusion with ascites (Figure 2). Routine blood investigations were normal.

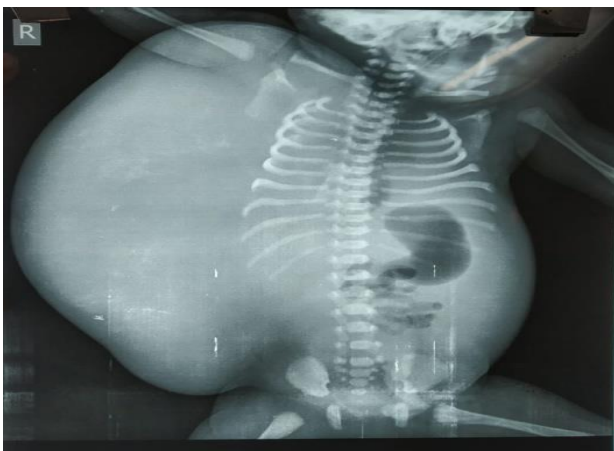

Figure 2: Chest X-ray with abdomen.

Antenatal scan done in last trimester at 35 weeks and 3 days showed large multi-septated cyst in anterior chest

wall and ascites with bilateral pleural effusion, cardiomegaly suggesting non immune hydrops (Figure 3). Dating scan done at 16 weeks of gestation was normal. Anomaly scan was not done. Family history revealed no congenital malformation or hydrops fetalis.

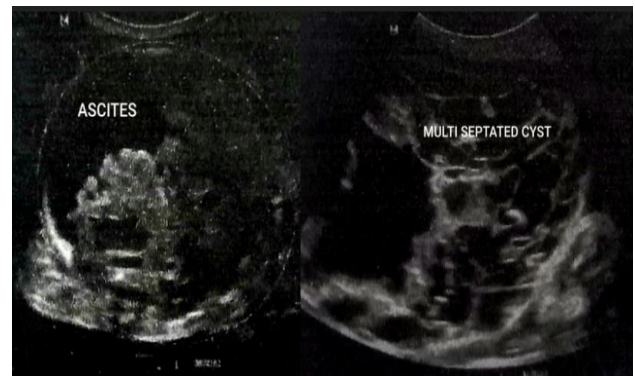


Figure 3: Antenatal ultrasonogram.

Based on clinical and radiological features with evidence of antenatal findings, we had made a diagnosis of Giant fetal lymphangioma with non immune hydrops fetalis. Baby went in for cardiopulmonary arrest at 9 hours of life and could not be revived.

DISCUSSION

In review of literature, the largest lymphangioma of size 14×9×9 cm was reported by Lu et al which was lesser than our case whose size was 25×12.5×9 cm, making it as the largest known mass over chest and abdominal wall at live birth.¹

Gedikbasi A et al observed bigger the volume of cyst, presence of septa and presence of hydrops worsens the outcome which was similar to our case study.⁶ He also reported hydrops developed in 17.1% and 54.5% of non septated and septated hygroma respectively ($p=0.007$).⁶ However in contrast to above findings, Lu et al showed septa and volume of cyst are not reliable prognostic indicators.¹ He noted association with chromosomal or structural abnormalities have bad prognosis.

Treatment of fetal lymphangioma is surgical excision but in our study, baby couldnot undergo surgery due to hemodynamic instability and respiratory compromise. In literature, one study, Gallagher et al reported intervention using sclerosing agents like bleomycin, 432 showed promising results in regression of hygroma, but its availability hinders its usage. Lu et al concluded multiseptated fetal lymphangioma with no chromosomal or structural abnormalities have good outcome and their index child had similar presentation, underwent surgery at 4th postnatal day of life and was followed till 18 months of age with no further abnormalities. Erosy et al showed good outcome with postnatal oral sirolimus, an antiproliferative drug which reduces the size of the lesion

significantly in a baby with fetal lymphangioma who had normal karyotyping and absence of hydrops fetalis.^{1,3,4}

According to Ali et al, Fouedjio et al and Ravikanth et al, most of the fetuses with lymphangioma associated with hydrops die antenatally. Kamble et al also observed when hydrops is present along with cystic hygroma, the mortality rate is near 100%. Whereas in our study, baby survived postnatally till 9 hours of life.^{2,7-9}

CONCLUSION

Fetal lymphangioma is an antenatal diagnosis. Its association with hydrops fetalis will have high mortality. Early diagnosis by antenatal anomaly scan plays a major role in deciding management. Early intervention may change the outcome.

ACKNOWLEDGEMENTS

Authors are thankful to Dr. R. Ramanathan, Dr. S. Ramesh and Dr. C. S. Balachandran for giving moral support and guidance.

Funding: No funding sources

Conflict of interest: None declared

Ethical approval: Not required

REFERENCES

1. Lu D, Wang Y, Zeng W, Peng B. Giant fetal lymphangioma at chestwall and prognosis: Case report and literature review. Taiwanese J Obstet Gynecol. 2015;54:62-5.
2. Kamble V, Bhatia T, Patil S. Cystic hygroma with hydrops fetalis: a rare case report. Int J Reprod Contracept Obstet Gynecol. 2014;3(3):847-50.
3. Ersoy AO, Oztas E, Saridogan E, Ozler S, Danisman N. An unusual origin of fetal lymphangioma filling right axilla. J Clin Diagn Res. 2016;10(3):QD09-11.
4. Gallagher PG, Mahoney MJ, Gosche JR. Cystic hygroma in the fetus and newborn. Semin Perinatol. 1999;23(4):341-56.
5. Kenneth M, Lopez S. Non immune hydrops fetalis. In: Eric CE, Anne R. Hansen CR. Stark MAR, eds. Cloherty and Stark's Manual of Neonatal Care. 8th ed. Netherlands: Wolters Kluwer; 2017:52-63.
6. Gedikbasi A, Gul A, Sargin A, Ceylan Y. Cystic hygroma and lymphangioma: associated findings, perinatal outcome and prognostic factors in live-born infants. Arch Gynecol Obstet. 2007;276:491-8.
7. Ali MK, Abdelbadee AY, Shazly SA, Othman ER. Hydrops fetalis with cystic hygroma: A case report. Middle East Fertil Soc J. 2012;17:134-5.
8. Fouedjio JH, Fouelifack FY, Ebune LJ. Antenatal diagnosis and management of nuchal cystic hygroma: A case report in the Yaounde central maternity, Cameroon. Clin Mother Child Health. 2011;8:1-3.
9. Ravikanth R, Prasannan R. Hydrops fetalis with septated cystic hygroma. Apollo Med. 2019;16:47-9.

Cite this article as: Paul JM, Sakthigirisamy P, Lakshmanan I, Mullainathan S, Sambandam S. Giant fetal lymphangioma with non-immune hydrops fetalis. Int J Contemp Pediatr 2020;7:2080-2.