

## Original Research Article

# Device closure of patent ductus arteriosus: analysis of cases in a Bangladeshi centre

Nurun N. Fatema<sup>1\*</sup>, Abul K. M. Razzaque<sup>2</sup>

<sup>1</sup>Department of Pediatric Cardiology, Lab Aid Cardiac Hospital, Dhaka, Bangladesh

<sup>2</sup>Department of Thoracic Surgery, Green life Medical College, Dhaka, Bangladesh

**Received:** 07 June 2020

**Accepted:** 15 June 2020

### \*Correspondence:

Dr. Nurun N. Fatema,

E-mail: colfatema@hotmail.com

**Copyright:** © the author(s), publisher and licensee Medip Academy. This is an open-access article distributed under the terms of the Creative Commons Attribution Non-Commercial License, which permits unrestricted non-commercial use, distribution, and reproduction in any medium, provided the original work is properly cited.

### ABSTRACT

**Background:** Transcatheter closure of Patent ductus arteriosus (PDA) has become the first-choice therapy for closure in patients of any age group. Authors reviewed the outcome of device closure in all age groups starting from neonate to adult.

**Methods:** From December 2014 to December 2019, 440 cases underwent transcatheter closure in a catheterization laboratory of a tertiary level cardiac hospital. Selection criteria were isolated PDA or PDA with associated conditions which can be managed in the same setting by an intervention. Exclusion criteria were proven Eisenmenger syndrome. A retrospective review of outcome and complications were recorded from computerized data records.

**Results:** Age of the patient varied from 10 days to 65 years. The median age was 3 years. Most of the patients were female (63%), weight varied from 1.8 kg to 75 kg. the median weight was 7.5 kg. Isolated PDA cases were 74.77%. Among syndromes, congenital rubella syndrome was common (7.5%), followed by Down Syndrome (6.36%). The narrowest PDA diameter varied for 1.8 mm - 14 mm with a median of 5 mm. Among duct occluders, 8x6 mm Cera™ was the commonest one used in the study population. Complete occlusion was observed in 99.55% of cases.

**Conclusions:** Transcatheter closure of PDA is considered safe and efficacious in all age groups. It is the gold standard now and replaced surgical option in most of the places.

**Keywords:** Complications, Outcome, Patent ductus arteriosus

### INTRODUCTION

Patent Ductus Arteriosus (PDA), a communication between the aorta and pulmonary artery, is a commonly encountered congenital heart disease in any age group.<sup>1</sup> Incidence is about 6 to 11 percent. Closing PDA by minimally invasive technique is now becoming the first choice of therapy for both the patient and the caregiver. The learning curve of the procedure is also short compared to other interventions. In newborns and young infants, challenges are different from that in adolescents and adults. In the young infant, the size of hardware and devices are of concern.<sup>2</sup> In adults, PDAs are often very large, and severe pulmonary hypertension and other

comorbidities are associated.<sup>3</sup> In small babies, PDA closure reduces the risk of death from heart failure and pulmonary hypertension, and in adults, it reduces the risk of endocarditis, arrhythmia, and mortality. With increased body growth in adolescents and adults, PDA changes its size, length, and twists around itself making it difficult to cross it during an intervention. In such cases snare assistance is required. Another important issue is device closure of large tubular PDA. In Bangladesh, especially in children with Congenital Rubella and Down syndrome, the incidence of tubular PDA is high and closure of this type of PDA needs a special skill and double-disc or specially designed devices.<sup>4</sup> For closure of PDA, most of the published data used Amplatzer duct

occluders (ADO I and ADO II).<sup>4,5</sup> In our series authors used Cera TM occluder of Lifetech Scientific in most of the cases, ADO II of AGA medical corporation, MFO of Lifetech scientific, muscular VSD device of Lifetech Scientific and AGA medical corporation and detachable PDA coil of cook cardiology in some cases. As patients age in this study varies from neonates to adults, many Off label methods and hardware were used as required. In this study, authors have compiled the outcome in such a heterogeneous group of population.

**METHODS**

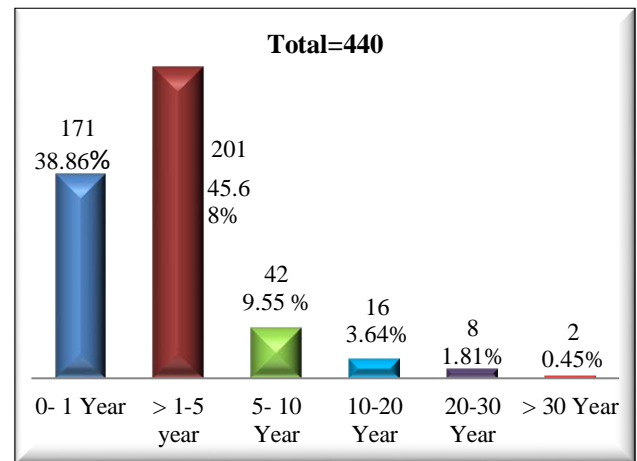
From December 2014 to December 2019, 440 patients were admitted to LabAid Cardiac Hospital with an intention for device closure. This hospital is the largest referral center for Percutaneous intervention in pediatric and grown up congenital heart diseases. All cases with a previous diagnosis of isolated PDA or PDA as major anatomical defects with others like atrial septal defect (ASD) secundum, coarctation of aorta (CoA) or pulmonary stenosis (PS) which also needs interventional management in same settings were included. After catheterization, the suitability of device closure in view of hemodynamic data was assessed, PDA diameter and device type, the size was selected based on Krichenko classification. Authors recorded simultaneous aortic and pulmonary artery (PA) pressure and if PA pressure was less than systemic, authors proceeded with device closure in young infants. In adults, balloon occlusion was performed to check the reduction in PA pressure or any evidence of a pulmonary hypertensive crisis. All cases of children less than 10 years were sedated properly with injection Midazolom 0.1 mg/ kg, Injection Ketamine 1mg/kg, and Injection phenobarbitone 10 mg/kg loading dose. For infants less than one-year general anesthesia was kept on standby. In adults, the procedure was performed in an awake condition. The antegrade approach was used to cross PDA in most of the cases but in some adolescents and adults, the retrograde approach was used. In most of the cases, both right femoral vein (RFV) and right femoral artery (RFA) were cannulated. In some cases crossing PDA was difficult and snare assisted technique was used. For PDA smaller than 2mm, coils were used and devices were used for more than PDA >2 mm. Duct occluders that were selected were 2 >mm larger than the narrowest PDA diameter. Devices used were detachable coils (Cook cardiology, USA), Heart& Cera Lifetech duct occlude (Life tech Scientific, Schenzhen Co Ltd), Konar - MFO-VSD occluder (Lifetech scientific Schenzhen Co Ltd), VSD muscular occluder(Lifetech Scientific), Cookon PDA occluder (Vascular Innovation, Thailand) ADOII (AGA Medical Corporation, USA) etc.

Authors used the recommended delivery system in some cases. In most of the young infants, authors used the delivery system of Cookon, Thailand as it was thin-walled with a capacious inner lumen which allowed up to 12x10 mm devices of any manufacturer through 6 French

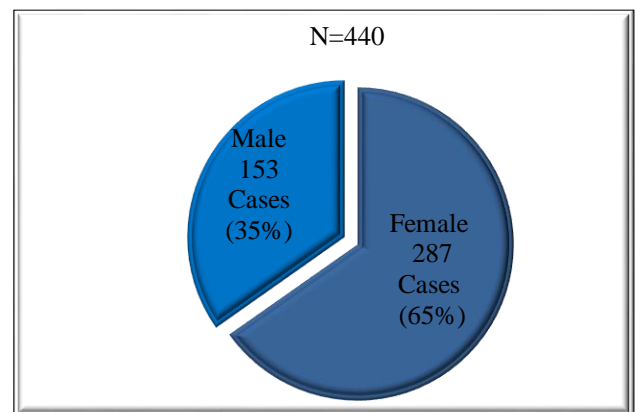
(Fr) sheath. For ADO II and MFO, authors preferred the coronary guide catheter of 5Fr and 6Fr depending on the weight of the patient and type of approach. For the arterial approach, 5Fr Catheter was used. All patients received Injection ceftriaxone 50 mg/kg, one dose in the catheterization laboratory, and another dose after 24 hours. Echocardiography was performed before discharge to see any residual shunt or embolization. Follow up was given at 1 month, 3-month, 9-month, 18 months, and 1 year thereafter for three years. Data were analyzed by MS Excel to see frequency, median, and t-test when applicable.

**RESULTS**

Figure 1 shows the age distribution of cases. Most of the patients were in >1-5 years age group (45.68%), less than one year were 38.86%, >5-10 years were 9.55%, >10-20 years were 3.645, >20-30 years were 1.81% and >30 years were 0.45%.



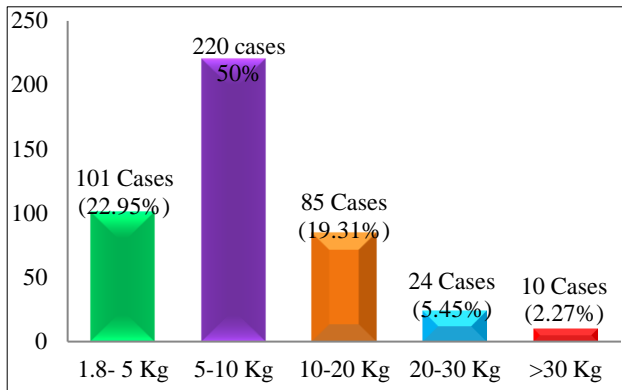
**Figure 1: Age distribution.**



**Figure 2: Sex distribution.**

Figure 2 shows the sex distribution. Females were 65% and males were 35%.

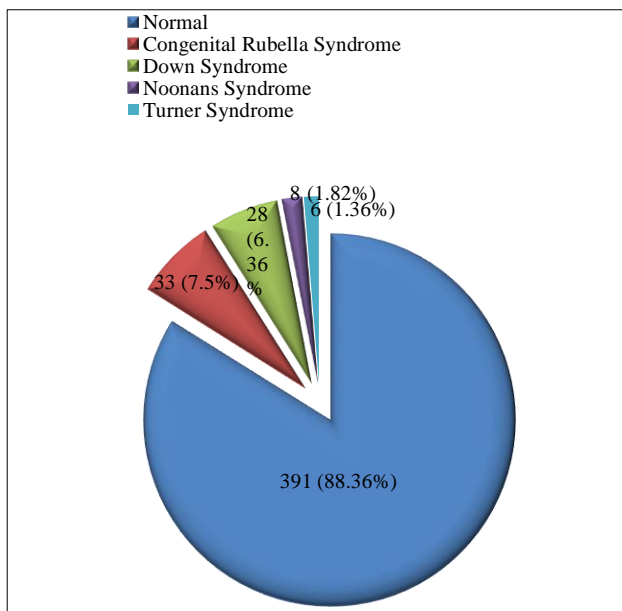
Figure 3 shows the weight distribution. Most of the cases (50%) weighted 5-10kg, 22.95% weighted 1.8-5 kg, 19.31% weighted 10-20 kg, 5.41% weighted 20-30 kg and 2.27% had weight more than 30 kg.



**Figure 3: Weight distribution.**

**Table 1: Association of other diseases with PDA (N=440).**

Disease	Number	Percentage
Isolated PDA	329	74.77
ASDII+ PDA	39	8.86
PDA+ COA	11	2.5
PDA+PS	24	5.45
PDA+ MVP AML	38	8.63
PDA + PM VSD	4	0.90



**Figure 4: Association with syndrome.**

Table 1 shows the association of other diseases with PDA. Isolated PDA was 74.77%. The most common association was atrial septal defect (ASD) secundum (8.86%) followed by mitral valve prolapse (MVP) of

anterior mitral leaflet (AML) in 8.63%, PS in 5.45%. CoA in 2.5% and ventral septal defect (VSD) in 0.9%.

Figure 4 shows the association with syndromes. Out of 75 cases, the most common association was with congenital Rubella syndrome (7.5%) followed by Down Syndrome in (6.36%), Noonans syndrome (1.82%) and Turner syndrome (1.36%).

Table 2 shows the angiographic data. Narrowest PDA diameter was >3 to 6mm in most of the cases (42.96%). It was 1.8-3 mm in 15.90% cases, >6-9 mm in 37.27 % cases, >9 to 14 mm in 3.87% cases.

Type A PDA was commonest according to Krichenko classification (47.5%), followed by type C (37.5%), type B (6.36%), type E (5.23%), and type D (3.41%). Most of the cases had both arterial and venous cannulation (84.32%), only arterial cannulation was performed in 9.09% and only venous in 6.59%. Procedure time was 60+28 minutes in 199(45.23%) cases. PVR was 4-6 W.U in most of the cases 189 (42.95%).

**Table 2: Angiographic data (N=440).**

Narrowest PDA diameter	No. (%)	Median/Mode
1.8- 3 mm	70 (15.90 )	5mm
>3- 6mm	189 (42.96 )	
>6 mm - 9 mm	164(37.27 )	
>9mm - 14 mm	17 (3.87)	
Krichenko classification of shape		
Type A	209 (47.5)	Type C
Type B	28 (6.36)	
Type C	165 (37.5)	
Type D	15 (3.41)	
Type E	23 (5.23)	
Approach of closure		
Arterial	40 (9.09)	Arterial and venous
Venous only	29 (6.59)	
Arterial and venous	371 (84.32)	
Procedure time (minutes)		
70±30	75 (17.05 %)	48
65±35	166 (37.73%)	
66±28	199 (45.23%)	
PVR wood units		
2 - 4	95 (21.59%)	5.5
4 - 6	189 (42.95%)	
>6	156 (35.45%)	

Table 3 shows the types of devices used. Among all sizes, 8x6 mm Cera™ duct occluder was the commonest device used. (29.77%). Duct occluders were used in 86.36% cases, ADOII in 3.64% cases, MFO-Konar VSD occluder in 4.77% cases, VSD muscular occluder in 0.45% cases.

**Table 3: Types of devices used (N=440).**

Type of devices used	Size	Number	Total
Duct occluder	5x3	12 (2.73%)	380 (86.36%)
	6x4	58 (13.18%)	
	8x6	131 (29.77%)	
	10x8	98 (22.27%)	
	12x 10	64 (14.55%)	
	14x12	11 (2.50%)	
	16x14	5 (1.14%)	
	18x16	1 (0.23%)	
ADOII	6x4	16 (3.64%)	16 (3.64%)
MFO	5x4	4 (0.91%)	21 (4.77%)
	6x4	15 (3.41%)	
	7x5	2 (0.45%)	
PDA Coil	5x4	18 (4.09%)	21 (4.77%)
	5x3	3 (0.69%)	
VSD muscular device	8 mm	1 (0.23%)	2 (0.45%)
	7mm	1 (0.23%)	

**Table 4: Complications and outcome (N=440).**

Variables	Number	Comments
Complete occlusion	436 (99.09%)	
Residual shunt after 1 month follow up/ After 06 month follow up.	02 (0.45%)/0	
Embolization	04 (0.91%)	One retrieved and coil occlusion done
Hypertensive crisis	06 (1.36%)	
Surgical closure	03 (0.68%)	Embolized Devices
Haemolysis	Nil	
Death after discharge	1 (0.23%)	Within 72 hours from milk aspiration
Arrhythmia	05 (1.14%)	
Persistent raised PA Pressure.	02 (0.45%)	
Eisenmenger syndrome	01 (0.23%)	Postponed and follow up.
Severe coarctation of aorta at 3 and 5 yr	02 (0.45%)	
Flow acceleration descending aorta	05 (1.14%)	
Flow acceleration LPA	05 (1.14%)	

Table 4 shows the outcome of the procedure and associated complications. Total 436 (99.09%) cases had complete PDA occluder immediately, 2 (0.45%) cases

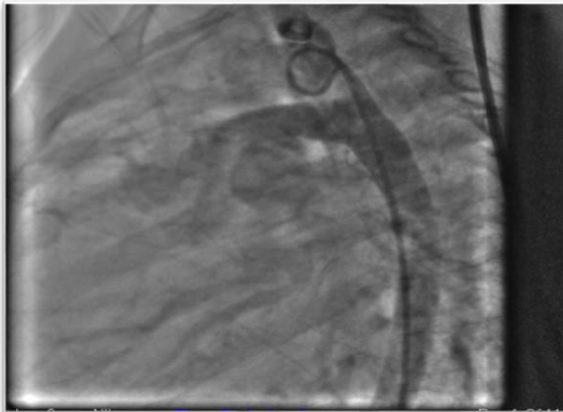
had residual shunt up to 6 months, four cases had device embolization, one was retrieved and coil was implanted immediately other three cases were sent for PDA ligation. One adult case was found as established Eisenmenger Syndrome and was kept on follow up. One patient of 14 months died within 24 hours of discharge for milk aspiration. Pulmonary hypertensive crisis was experienced in six cases and was managed successfully. Transient arrhythmia in five cases was also managed. Two (0.45%) cases had severe coarctation at two and five years follow up and balloon coarctoplasty performed. Five (1.14%) cases had flow acceleration through descending aorta and five (1.14%) had and left pulmonary arteries.

## DISCUSSION

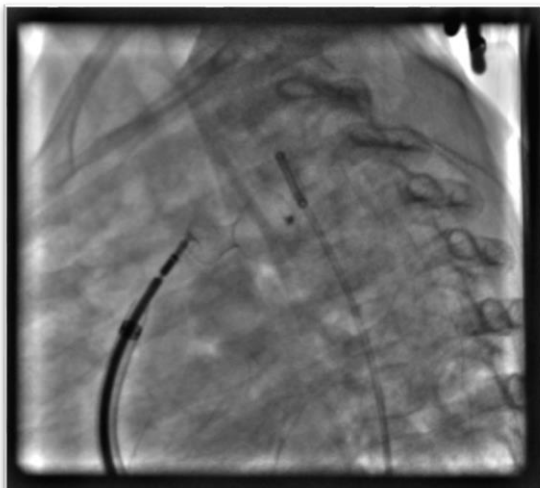
Since the first placement of Evalon Plug prosthesis in 1967 by Porstmann et al, several modifications of various kind of devices and delivery system has been done to set perfect hardware for the transcatheter closure of patent ductus arteriosus.<sup>6</sup> Diverse devices have been designed and later modification is done based on users' experience and outcome analysis.<sup>7</sup> Percutaneous closure of PDA has fewer complications than surgical closure and hospital stay is less and recovery is immediate.<sup>8,9</sup> So, efforts are made since last 50 years and earlier devices like Gianturco coil, Reidalcoil, Grifka bag, Cardeoseal are now replaced by single disc duct occluder for common cases and double-disc devices for tubular PDA.<sup>3</sup> In the 1990s (since 1992), coil occlusion with detachable coil was the most widely used option. Sommer et al introduced a novel approach of snare assisted technique for PDA less than 3mm in diameter.<sup>10</sup> But because of a residual shunt, it did not gain popularity. In one of the earliest studies conducted in University Hospital of Slovenia with Amplatzer Duct occluder (ADO) showed complete closure of 54 (98%) patient out of 55.<sup>11</sup>

Many other studies supported the evidence of more efficacy of complete closure with duct occluders.<sup>12-14</sup> But tubular PDA was not indicated for device closure initially. In Combined Military Hospital, Bangladesh, an effort of closing tubular PDA with duct occluders was practiced since 2007.<sup>1</sup> Reason was young infants with tubular PDA having severe pulmonary hypertension were often refused by cardiac surgeons considering very high risk (Figure 5). So Amplatzer duct occluders were used initially by forming an onion-like shape inside PDA shaft to exert pressure against the wall to remain stable. Later, CeraTM duct occluder was found to be softer to give onion-like shape. The good outcome of the first few cases led the team of CMH, Dhaka Bangladesh to convert it to routine practice. In this study, authors had a wide range of ages (10 days to 65 years, Figure 1) and whoever had PDA suitable for device closure was included. Most of the patients were female (65%) like other studies (Figure 2).<sup>15</sup> There is a wide range of weight variations starting from 1.8 kg in a preterm neonate to 75 kg in an adult. Other studies were carried out mainly on a specific group

and no comparative data with this study was found (Figure 3). Among associated lesions, ASD secundum was commonest (Table 1). In another study, VSD was the commonest associated lesion.<sup>16</sup> Congenital Rubella syndrome was the commonest syndrome in the study group. Incidence of PDA especially tubular PDA is common in this syndrome.<sup>3</sup> A study conducted in Sohag University hospital had a high incidence of Down syndrome.<sup>2</sup> PDA narrowest diameter varied for 1.8 to 14 mm, most of the patients had both arterial and venous cannulation and some patients required snare assistance from aortic end to cross PDA to pulmonary side. With experience, procedure, and fluoroscopy time had reduced and in uncomplicated cases, no hemodynamic calculation was performed routinely. The type of PDA device and the size were planned from aortogram (Table 2) as per Krinchenko classification.<sup>17</sup>



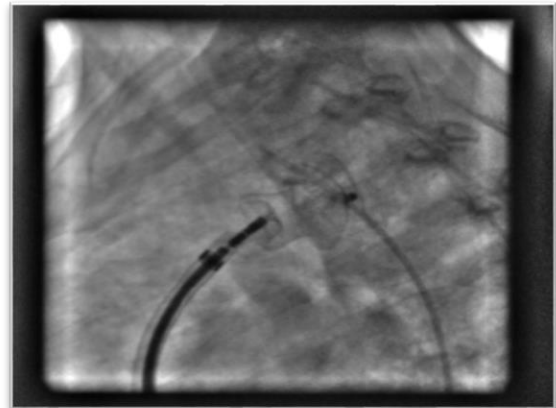
**Figure 5: Aortogram lateral view showed large PDA.**



**Figure 6: Aortogram showed complete occlusion of PDA with 8x6 mm device.**

Pulmonary vascular resistance was very high in large tubular PDA and large PDA and thorough hemodynamic studies were performed.<sup>18</sup> In small infants, either venous or arterial approach was used and ADOII, MFO and coil were preferred considering the size of the delivery

system. Special considerations for children with less than 2 kg were also taken in other studies.<sup>19</sup>



**Figure 7: Aortogram showed complete occlusion of PDA after implantation of 14x12 mm life tech device.**

In this study 8x6 mm Cera™ was used in 29.77% cases, VSD muscular device having double disc was used in two cases with very large PDA (Figure 6). Similar devices for large PDAs were used in other studies.<sup>20,21</sup> For newborn babies who need PDA closure urgently and weigh  $\geq 700$  gm, Amplatzer Piccolo Occluder (Abbott Structural Heart, Plymouth, MN, USA) can be used.<sup>22</sup> This device comes pre-loaded on a delivery wire, which has a soft floppy distal end with a micro screw attached at the tip.<sup>23</sup> In a study conducted by Masura et al, showed an immediate success rate of 99.55%. The remaining 0.45% were closed completely at one month follow up and remained closed thereafter.<sup>24</sup> In this study, PDA device closure was performed successfully in 436 cases (99.09%). In another study success rate was 97.4%.<sup>25</sup> Major complications like hemolysis, embolization, infective endocarditis, severe narrowing from mechanical obstruction at the level of descending aorta, or left pulmonary artery were analyzed (Figure 7). Four cases had embolization of device, one was retrieved, and coil occlusion was performed. Three went for surgical closure. Device embolization is a common complication. It varies from 0.3% to 16%.<sup>24-26</sup> In this study, it was 0.9%. One adult patient had Eisenmenger change and device closure was postponed and kept on follow up. Complications like mechanical obstruction to Aortic end or on the left pulmonary artery side were checked before deployment of the device. Two patients developed coarctation of aorta in follow up after 2 and 5 years and balloon dilation was performed. Five cases developed minor complications like mild left pulmonary artery stenosis in various levels of follow up, but no intervention was required. Five cases had flow acceleration through descending aorta. These minor complications correlate with other studies.<sup>24,27-30</sup> Transient arrhythmia was observed in six cases which were managed in the catheterization lab. Two patients still had moderate pulmonary hypertension and were on medication. One patient expired after discharge from the

aspiration of milk. This mortality was not related to the procedure.

## CONCLUSION

In conclusion, with careful planning and combined fluoroscopy and echocardiography guide, transcatheter closure of PDA can be safely and successfully performed in any age group provided there is no contraindication. From the experience of this study, authors can recommend the use of coil in <2 mm PDA. In newborns with large PDA, authors can use ADOII or MFO-Konar using a coronary guide catheter as the delivery system. New Amplatzer Piccolo devices can also be used in newborns. In young infants, authors can use a large device up to 12x10 mm by using Cookon delivery system. For closing large tubular PDAs in older children and adults, VSD muscular device is a good option.

## ACKNOWLEDGEMENTS

Authors would like to thank Mashiyat Mayisha Ahmad, second year medical student, University of Manchester, UK for her help with editing this paper. Authors are also grateful to Lab Aid Cath Lab team for their help with these cases.

*Funding: No funding sources*

*Conflict of interest: None declared*

*Ethical approval: Not required*

## REFERENCES

1. Fatema NN. Pattern of Congenital Heart Diseases and Treatment Options in a Bangladeshi Centre: Analysis of 6914 cases from Non-invasive Cardiac Laboratory. *Cardiovasc J*. 2017;9(2):97-105.
2. Ali S, El Sisi A. Transcatheter closure of patent ductus arteriosus in children weighing 10 kg or less: Initial experience at Sohag University Hospital. *J Saudi Heart Assoc*. 2016 Apr 1;28(2):95-100.
3. Sudhakar P, George OK. Contemporary outcome of percutaneous closure of patent ductus arteriosus in adolescents and adults. *Indian Heart J*. 2018; 70(2):308-15.
4. Fatema NN. Device Closure of Patent Ductus Arteriosus in Patient with Congenital Rubella Syndrome and Severe Pulmonary Hypertension: Report of Two Cases. *JAFMC Bangladesh*. 2011;7(1):43-5.
5. Kim Y, Choi JY, Lee JK, Sul JH, Lee SK, Park YH, et al. Mid-term result of the transcatheter occlusion of patent ductus arteriosus with Duct-Occluder device and procedure-related problems. *Korean J Pediatr*. 2004;47(1):36-43.
6. Porstmann W, Wierny L, Warnke H. Closure of persistent ductus arteriosus without thoracotomy. *Ger Med Mon*. 1967;12(6):259-61.
7. Pass RH, Hijazi Z, Hsu DT, Lewis V, Hellenbrand WE. Multicenter USA Amplatzer patent ductus arteriosus occlusion device trial: initial and one-year results. *J Am Coll Cardiol*. 2004;44(3):513-9.
8. Lee LK, Woodfin MY, Vadi MG, Grogan T, Ross PR, Applegate RL, et al. comparison of postoperative outcomes with PDA ligation in the OR versus the NICU: a retrospective cohort study on the risks of transport. *BMC Anesthesiol*. 2018;18(1):199.
9. Wang K, Pan X, Tang Q, Pang Y. Catheterization therapy vs surgical closure in pediatric patients with patent ductus arteriosus: a meta-analysis. *Clin Cardiol*. 2014;37(3):188-94.
10. Sommer RJ, Gutierrez A, Lai WW, Parness IA. Use of preformed nitinol snare to improve transcatheter coil delivery in occlusion of patent ductus arteriosus. *Am J Cardiol*. 1994;74(8):836-9.
11. Podnar T, Gavora P, Masura J. Percutaneous closure of patent ductus arteriosus: complementary use of detachable Cook patent ductus arteriosus coils and Amplatzer duct occluders. *Eur J Pediatr*. 2000;159(4):293-6.
12. Saliba Z, Aggoun Y, Hausse AO, Acar P, Bonnet D, Fraise A, et al. Percutaneous closure of patent ductus arteriosus with the Amplatzer duct occlude. *Archives des Maladies du Coeur et des Vaisseaux*. 2000 May;93(5):533-8.
13. Marwah A, Radhakrishnan S, Shrivastava S. Immediate and early results of closure of moderate to large patent arterial ducts using the new Amplatzer device. *Cardiol Young*. 2000;10(3):208-11.
14. Thanopoulos BV, Hakim FA, Hiari A, Goussous Y, Basta E, Zarayelyan AA, et al. Further experience with transcatheter closure of the patent ductus arteriosus using the Amplatzer duct occluder. *J Am Coll Cardiol*. 2000 Mar 15;35(4):1016-21.
15. Behjati-Ardakani M, Behjati-Ardakani MA, Hosseini SH, Noori N. Long-term results of transcatheter closure of patent ductus arteriosus in infants using amplatzer duct occluder. *Iran J Pediatr*. 2013;23(4):411-6.
16. Ullah M, Sultan M, Akhtar K, Sadiq N, Akbar H. Percutaneous transcatheter PDA device closure in infancy. *J Coll Physicians Surg Pak*. 2014;24(8):581-5.
17. Krichenko MD, Benson LN, Burrows P, Möes CA, McLaughlin P, Freedom RM. Angiographic classification of the isolated persistently patent ductus arteriosus and implications for percutaneous catheter occlusion. *Am J Cardiol*. 1989;63(12):877-80.
18. Park YA, Kim NK, Park SJ, Yun BS, Choi JY, Sul JH. Clinical outcome of transcatheter closure of patent ductus arteriosus in small children weighing 10 kg or less. *Korean J Pediatr*. 2010;53:1012-7.
19. Backes CH, Cheatham SL, Deyo GM, Leopold S, Ball MK, Smith CV, et al. Percutaneous Patent Ductus Arteriosus (PDA) Closure in Very Preterm Infants: Feasibility and Complications. *J Am Heart Assoc*. 2016;5(2):e002923.

20. Kumar SM, Subramanian V, Bijulal S, Krishnamoorthy KM, Sivasankaran S, Tharakan JA. Percutaneous closure of a moderate to large tubular or elongated patent ductus arteriosus in children younger than 3 years: is the ADO II appropriate?. *Pediatr Cardiol.* 2013;34(7):1661-7.
21. Butera G, De Rosa G, Chessa M, Piazza L, Delogu A, Frigiola A, et al. Transcatheter closure of persistent ductus arteriosus with the Amplatzer duct occluder in very young symptomatic children. *Heart.* 2004;90(12):1467-70.
22. Sathanandam S, Gutfinger D, O'Brien L et al. Amplatzer Piccolo Occluder clinical trial for percutaneous closure of the patent ductus arteriosus in patients  $\geq 700$  grams. *Catheterization and Cardiovascular Interventions.* 2020.
23. Sathanandam S. Transcatheter PDA closure using the Amplatzer Piccolo occluder device in premature infants less than 2 kg. *Real world Registry study.* 2018.
24. Masura J, Tittel P, Gavora P, Podnar T. Long-term outcome of transcatheter patent ductus arteriosus closure using Amplatzer duct occluders. *Am Heart J.* 2006;151(3):755.
25. Jang GY, Son CS, Lee JW, Lee JY, Kim SJ. Complications after transcatheter closure of patent ductus arteriosus. *J Korean Med Sci.* 2007;22(3):484-90.
26. Dimas VV, Takao C, Ing FF, Mattamal R, Nugent AW, Grifka RG, et al. Outcomes of transcatheter occlusion of patent ductus arteriosus in infants weighing  $\leq 6$  kg. *JACC Cardiovasc Interv.* 2010;3(12):1295-9.
27. Wang JK, Wu MH, Hwang JJ, Chiang FT, Lin MT, Lue HC. Transcatheter closure of moderate to large patent ductus arteriosus with the Amplatzer duct occluder. *Catheter Cardiovasc Interv.* 2007;69(4):572-8.
28. Al-Ata J, Arfi AM, Hussain A, Kouatli AA, Jalal MO. The efficacy and safety of the Amplatzer ductal occluder in young children and infants. *Cardiol Young.* 2005;15(3):279-85.
29. Lee CH, Leung YL, Chow WH. Transcatheter closure of the patent ductus arteriosus using an Amplatzer duct occluder in adults. *Jpn Heart J.* 2001;42(4):533-7.
30. El-Said HG, Bratincsak A, Foerster SR, Murphy JJ, Vincent J, Holzer R et al. Safety of percutaneous patent ductus arteriosus closure: an unselected multicenter population experience. *J Am Heart Assoc.* 2013;2(6):e000424.

**Cite this article as:** Fatema NN, Razzaque AKM. Device closure of patent ductus arteriosus: analysis of cases in a Bangladeshi centre. *Int J Contemp Pediatr* 2020;7:1481-7.