

Original Research Article

A prospective observational study of associated anomalies in hirschsprung's disease

Monali Madhukar Patole^{1*}, Mandar Madhukar Patole², Subhasish Paul³

¹Consultant, Department of Pediatric Surgery, Godrej Memorial Hospital, Mumbai, Maharashtra, India

²Consultant, Department of Oral and Maxillofacial Surgery, Godrej Memorial Hospital, Mumbai, Maharashtra, India

³Consultant, Department of Pediatrics, Charnock Hospital, Kolkata, West Bengal, India

Received: 04 October 2019

Revised: 08 November 2019

Accepted: 14 November 2019

*Correspondence:

Dr. Monali Madhukar Patole,

E-mail: drmonalimp@gmail.com

Copyright: © the author(s), publisher and licensee Medip Academy. This is an open-access article distributed under the terms of the Creative Commons Attribution Non-Commercial License, which permits unrestricted non-commercial use, distribution, and reproduction in any medium, provided the original work is properly cited.

ABSTRACT

Background: Hirschsprung's Disease (HSCR) is the commonest congenital gut motility disorder and is characterized by the absence of ganglion cells in a variable length of the distal gut. According to literature, HSCR may be associated with a chromosomal abnormality or other congenital anomalies in approximately 20% of cases. HSCR appeared to be a multifactorial malformation with low, sex dependent penetrance and variable expression according to the length of the ganglionic segment, suggesting the involvement of one or more gene(s) with low penetrance. So far, eight genes have been found to be involved in HSCR. This frequent congenital malformation now stands as a model for genetic disorders with complex patterns of inheritance. The objective of this study was to collect and study personal and family history and any information regarding known associated anomalies in patients diagnosed as Hirschsprung's disease.

Methods: Here author present a series of 89 consecutive HSCR patients who were admitted or attended the Pediatric Surgery OPD of in a tertiary care Government medical college, who were evaluated for associated malformations with the help of available non-invasive investigation.

Results: Congenital heart diseases and Down's syndrome were the two most common associated anomalies. Genitourinary anomalies, Limb anomalies and central nervous system anomalies were other associated anomalies.

Conclusions: This study confirmed the underestimation of certain associated anomalies in Hirschsprung patients, such as CNS anomalies. Based on the results of this study, in addition to meticulous general examination author suggest performing cardiologic assessment in patients diagnosed with Hirschsprung's disease based on clinical features and according to the standards of care adopted for the general population.

Keywords: Anterior sacral meningocele, Associated congenital anomalies, Cardiovascular anomalies, Down's syndrome, Genitourinary anomalies, Hirschsprung's disease

INTRODUCTION

Hirschsprung's Disease (HSCR) is the commonest congenital gut motility disorder and is characterized by the absence of ganglion cells in a variable length of the distal gut. This results in absent peristalsis in the affected bowel and it represents a frequent cause of Functional intestinal obstruction especially in the newborn period.¹ It occurs as a consequence of premature arrest of cranio-

caudal migration of neural crest derived neuroblasts (NCN) in the distal portion of the gut and is therefore described as a neurocristopathy.¹⁻³

Alterations of heterogeneous genetic pathways involved in the enteric nervous system development may interfere with the colonization process of NCN and represents a primary etiology both for HSCR and for the anomalies of other organs and systems that often come together.⁴

According to literature, HSCR may be associated with a chromosomal abnormality or other congenital anomalies in approximately 20% of cases.^{5,6}

In the last decades, the development of surgical approaches has dramatically decreased mortality and morbidity, which has allowed the emergence of familial cases. HSCR appeared to be a multifactorial malformation with low, sex dependent penetrance and variable expression according to the length of a ganglionic segment, suggesting the involvement of one or more gene (s) with low penetrance. So far, eight genes have been found to be involved in HSCR. This frequent congenital malformation now stands as a model for genetic disorders with complex patterns of inheritance. Objective was to collect and study personal and family history and any information regarding known associated anomalies in patients diagnosed as Hirschsprung's disease

METHODS

Institutional Review Board approval and waiver of consent were taken for the study. The study was done in department of pediatric surgery at NRS medical college, Kolkata. Patients attending at Pediatric Surgery OPD/ ER and admitted to Department of Pediatric Surgery, from January 2015 to December 2016 at NRSMC and H were included. Total number of patients with Hirschsprung disease admitted to Department of Pediatric Surgery, NRSMC and H during this study period, approximately around 100.

Inclusion criteria

- The presence of a reliable diagnosis of Hirschsprung' disease achieved with adequate pathological assessment.

Exclusion criteria

- Uncertain diagnosis and/or refusal to participate.

It was an institution based Prospective study, taking into consideration the age at presentation, history of the

patient and the parents, condition of the patient at the time of presentation, associated anomalies, diagnostic modalities and their results, operative or nonoperative procedure performed, histopathological report, postoperative morbidity and mortality (if any) and if related to associated anomaly.

The study tools used were Patients informed consent from their guardians, proforma for relevant history and clinical examination, Weight machine, measuring tape, Stethoscope, USG of whole abdomen, Cardiologic assessment with 2-D Echocardiography, Further specialist investigations based on clinical features. Investigations were performed basing on clinical features detected during the first detailed physical examination aimed at ruling out major gross abnormalities, including skull and facial malformations, cleft lip or palate, gross skeletal malformations, skin pigmentation disorders, external genitalia abnormalities, neurodevelopmental delay, etc. All information regarding other associated anomalies or syndromes reported by parents or patients were recorded.

Data collection and analysis was performed using SPSS, version 24.

RESULTS

Overall, 89 consecutive HSCR patients were admitted or attended the Pediatric Surgery OPD of Nil Ratan Sircar Medical college. 62 patients met the inclusion criteria, were enrolled and underwent the entire phenotype screening during the study period.). Descriptive statistical analysis was used to evaluate the results.

Males were 66% and females were 34%. Four (6.4%) hadTCSA, 12(19.25%) had L-HSCR, and 46(74.19%) had S- HSCR. A total of 12(19.35%) associated anomalies were detected in 62 patients as shown in table 1.

As shown in (Table 1), out of the 12 detected anomalies, 9 anomalies were found in short segment Hirschsprung's disease and 3 anomalies were found in long segment Hirschsprung's disease.

Table 1: Overall details of 62 HSCR disease patients and among them 12 patients with anomalies, who completed screening during the study period.

Patients, n=62	Associated anomalies	% among total 62 screened patients of Hirschsprung's disease	% among the total 12 anomalies found in Hirschsprung's disease patients
Limb anomalies	1	1.6% (out of 62 total)	8.33% (out of 12 anomalies)
CVS anomalies	4	6.4% (out of 62 total)	33.33% (out of 12 anomalies)
CNS anomalies	1	1.6% (out of 62 total)	8.33% (out of 12 anomalies)
Genitourinary anomalies	2	3.2% (out of 62 total)	16.66% (out of 12 anomalies)
Downs syndrome	4	6.4% (out of 62 total)	33.33% (out of 12 anomalies)

Major cardiovascular were detected or confirmed during phenotype screening in 4 patients. Cardiovascular anomalies were represented by septal defects (either atrial or ventricular) in all patients. Downs syndrome was detected in four (33.33%) of the patients All four patients were males. Two patients had long segment Hirschsprung’s disease and two patients had short segment Hirschsprung’s disease. One patient with long segment Hirschsprung’s disease had left sided cryptorchidism and one patient with short segment Hirschsprung’s disease had left sided cryptorchidism as shown in table 2.

Table 2: Associated genitourinary anomalies in HSCR.

ID	Sex	HSCR type	Associated anomalies (Genital Abnormalities)
35	M	S-HSCR	Left sided Cryptorchidism
52	M	L-HSCR	Left sided Cryptorchidism

One patient with short segment Hirschsprung’s disease had right hand polydactyly. During mobilization of the native rectum, author found an Incidental per-operative findings of anterior sacral meningocele during pull-through operation for Hirschsprung disease, Hirschsprung’s disease, neural tube defect no compressible whitish cystic pulsatile Cerebrospinal Fluid (CSF) filled mass (about 3.5 cm × 4 cm × 2 cm) at the hollow of sacrum at S2, S3, and S4 level (Figure 1).

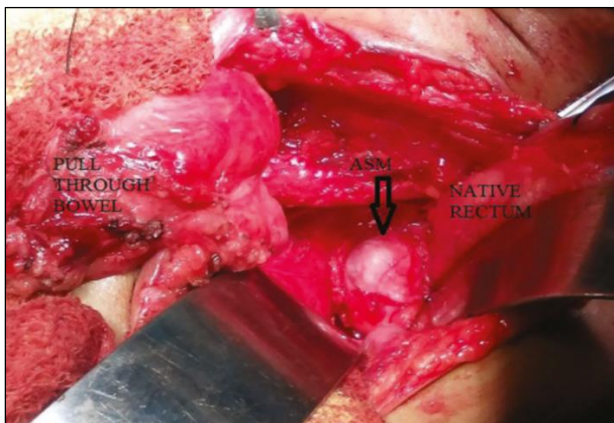


Figure 1: Intraoperative picture of anterior sacral meningocele associated with hirschsprung’s disease, an extremely rare association.

On aspiration, about 4 ml clear watery fluid aspirated and after meticulous dissection the mass was removed (Figure 2). The sacral hollow was repaired and it was reinforced with presacral fascia to prevent further CSF leakage. Endorectal pull through operation (Soave operation) was undertaken instead of modified Duhamel operation. Postoperative histopathology of that mass confirmed ASM. No neurological signs and symptoms were appeared during the follow-up period. Follow up

Magnetic Resonance Imaging (MRI) showed no mass lesion at the presacral area.

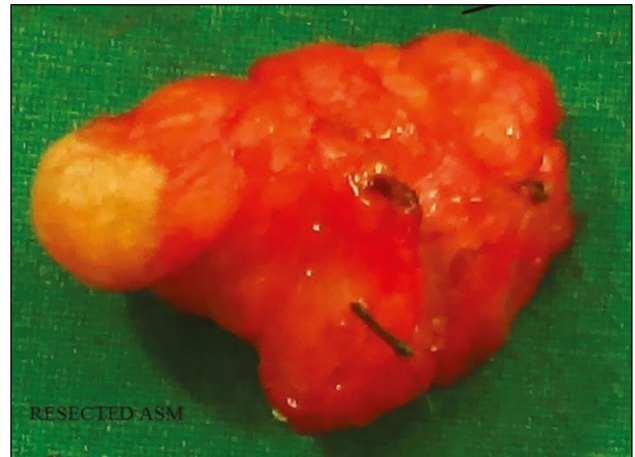

Figure 2: Hirschsprung’s disease-an extremely rare association.

DISCUSSION

This study showed male preponderance of 66.12%. There is a sex bias with a preponderance of affected males (7). S- HSCR comprised 74.19%, L-HSCR comprised 19.25% and TCSA was 6.45%. In a study by Pini Prato Aganglionosis was confined to the rectosigmoid colon (classic forms) in 74,5% of cases.⁸ S-HSCR is far more frequent than L-HSCR (80% and 20%, respectively).⁹ Author detected 12 associated anomalies in 62 patients (19.35%).

In a study by Pini Prato detected 112 associated anomalies in 61(57,5%) patients.⁸ In a study by Moore SW associated congenital anomalies occur in at least 5-32%.¹⁰ The percentage of Congenital Heart Disease (CHD) in this study was 33.33%. whereas the proportion of CHD in HSCR patients has been reported to be around 5%, according to literature.⁵ Among this study population, author had an overall detection rate of associated CHDs of 8.3%.¹¹ In a study by Pini Prato the percentage of congenital heart disease was 4.7%.⁸ In a study by Sachiyo Suita the percentage of Cardiac anomalies was 2.5%.¹²

In a study by Moore SW the percentage of cardiovascular anomalies in Hirschsprung’s disease is 4.99%.¹⁰ This is in accordance with the embryologic role of NCN in the development of both enteric nervous system and cardiac outflow septation.¹³ The percentage of genitourinary anomalies in this series was 16.66%. both the cases were cryptorchidism.in a study by Moore SW the genito-urinary tract 6.05%.¹⁰ In a study by Sachiyo Suita genitourinary tract anomaly of Undescended testis was found in 0.6%.¹² Downs syndrome comprised of 33.33%. In a study by Pini Prato the percentage of chromosomal abnormalities or syndromes was 8.5%.⁸ In a study by Sachiyo Suita the percentage of Down syndrome was 2.9%.¹² The percentage of limb anomalies in

this study was 8.33%. A series of rare syndromes with HSCR and distal limb anomalies (polydactyly or hypoplasia) have been reported. These are HSCR with polydactyly, unilateral renal agenesis, hypertelorism, and congenital deafness, HSCR postaxial polydactyly, and ventricular septal defects, HSCR hypoplasia of the distal phalanges and nails, and mild dysmorphic features, HSCR with preaxial polydactyly, heart defect, and laryngeal anomalies.¹⁴⁻¹⁷

The percentage of CNS anomalies in this study was 8.33%. In a study by Pini Prato the percentage of CNS anomalies was 2.3%.⁸ In a study by Moore SW the percentage of CNS anomalies was 5.12%. Anterior Sacral Meningocele (ASM) is a rare variant of neural tube defect.¹⁰ It occurs due to herniation of contents of spinal canal through anterior surface of sacrum and covered by meninges. HD is the second most common cause of neonatal lower gastrointestinal tract obstruction after Anorectal Malformations (ARM). Association of ARM and ASM is well documented, but association of ASM with HD could not be found in literature. Only one case of occipital meningocele is found in association with HD in literature.¹⁸ HSCR is a rare disease and the number of patients enrolled in such a relatively small timespan implies strong commitment and a multidisciplinary approach that deserve consideration.

It is evident that the implementation of a prospective multicenter research project is warranted.

In 1973, Bolande proposed the term neurocristopathy for syndromes or tumors involving Neural Crest (NC) cells. HSCR resulting from an anomaly of the Enteric Nervous System (ENS) of NC origin is therefore regarded as a neurocristopathy.⁶ HSCR occurs as an isolated trait in 70% of patients, is associated with a chromosomal abnormality in 12% of cases, and with additional congenital anomalies in 18% of cases.^{19,20} In the latter group of patients, some monogenic syndromes can be recognized. Isolated HSCR appears to be a multifactorial malformation with low, sex dependent penetrance, variable expression according to the length of a ganglionic segment and suggesting the involvement of one or more gene (s) with low penetrance.²¹

Isolated anomalies - A wide spectrum of additional isolated anomalies have been described among HSCR cases with an incidence varying from 5% to 30% according to series.^{8 9 11 104-107.}²²

No constant pattern is observed, and these anomalies include distal limb, sensorineural, skin, central nervous system, genital, kidney, and cardiac malformations. However, cardiac defects, mostly atrio- or ventricular septal defects, are found with an incidence of 5% of cases of HSCR, excluding patients with trisomy 21. Renal dysplasia or agenesis was found in 4.4% in a series of 160 HSCR cases and may still be underestimated (personal data). Genital anomalies including hypospadias

are reported in up to 2-3% of HSCR patients. Gastrointestinal malformations such as Meckel diverticulum, pyloric stenosis, single umbilical artery, inguinal hernia, or small bowel atresia are also found.^{23,24} Finally, facial dysmorphic features seem to be extremely frequent when looked for. These data highlight the importance of a careful assessment by a clinician trained in dysmorphology for all newborns diagnosed with HSCR. Skeletal x ray and cardiac and urogenital echographic survey should be systematically performed. The observation of one additional anomaly to HSCR should prompt chromosomal studies and/or molecular studies. The ENS is a complex and independent nervous system that is formed by precursors that migrate to the bowel from vagal, truncal, and sacral regions of the neural crest. Hirschsprung's disease of humans has been associated with a number of mutations, including RET, EDNRB, and EDN3. Hirschsprung's disease, however, is a multigenic abnormality that cannot be completely accounted for by known mutations. Each of the factors that are critical for the formation of the normal ENS are potential targets of mutations that might cause Hirschsprung's disease or other birth defects in humans. Future research should begin to reveal genes that, in their abnormality, cause hypoganglionosis, neuronal intestinal dysplasias, and intestinal dysganglionoses, as well more contributors to Hirschsprung's disease.²⁴

Hopefully, progress made in understanding the pathogenesis of Hirschsprung's disease and allied disorders will provide better means of treating these conditions and, better yet, preventing them.

CONCLUSION

Based on the results of this study, in addition to meticulous general examination author suggest performing cardiologic assessment in patients diagnosed with Hirschsprung's disease based on clinical features and according to the standards of care adopted for the general population.

Intestinal aganglionosis in HSCR patients represents the intestinal phenotype of a more complex syndrome driven by the interaction of neural crest maldevelopment and predisposing genetic background. This study confirmed the underestimation of certain associated anomalies in Hirschsprung patients, such as CNS anomalies. Conversely, 2D ECHO can be performed according to guidelines applied to the general population or in case of patients with suspected clinical features or chromosomal abnormalities. The investigation of genetic background of patients with associated anomalies might be the next step to explore this intriguing multifactorial congenital disease.

Funding: No funding sources

Conflict of interest: None declared

Ethical approval: The study was approved by the Institutional Ethics Committee

REFERENCES

1. Dasgupta R, Langer JC. Hirschsprung disease: *CurrProblSurg Curr Probl Surg.* 2004;41(12):942-88
2. Whitehouse FR, Kernohan JW. Myenteric plexus in congenital megacolon: study of eleven cases. *Archives Int Med.* 1948;82(1):75-111.
3. Kenny S E, Tam P K H, Garcia-Barcelo M, Phil M. Hirschsprung's disease. *Semin Paediatr Surg.* 2010;19(3):194-200.
4. Panza E, Knowles CH, Graziano C, Thapar N, Burns AJ, Seri M, et al. Genetics of human enteric neuropathies. *Progress Neurobiol.* 2012;96(2):176-89.
5. Das K, Alladi A, Kini U, Babu MK, Cruz AJ. Hirschsprung's disease, associated rare congenital anomalies. *Ind J Pediatr.* 2001 ;68(9):835-7.
6. Bolande RP. The neurocristopathies: a unifying concept of disease arising in neural crest maldevelopment. *Human Pathol.* 1974;5(4):409-29.
7. Badner JA, Sieber WK, Garver KL, Chakravarti AR. A genetic study of Hirschsprung disease. *Am J Human Genetics.*1990;46(3):568.
8. Prato AP, Rossi V, Mosconi M, Holm C, Lantieri F, Griseri P, et al. A prospective observational study of associated anomalies in Hirschsprung's disease. *Orphanet J Rare Dis.* 2013;8(1):184.
9. Passarge E. The genetics of Hirschsprung's disease: evidence for heterogeneous etiology and a study of sixty-three families. *New Engl J Med.* 1967;276(3):138-43.
10. Moore SW. The contribution of associated congenital anomalies in understanding Hirschsprung's disease. *Pediatr Surg Intern.* 2006;22(4):305-15.
11. Tuo G, Pini Prato A, Derchi M, Mosconi M, Mattioli G, Marasini M. Hirschsprung's disease and associated congenital heart defects: a prospective observational study from a single institution. *Frontiers Pediatr.* 2014;2:99.
12. Suita S, Taguchi T, Ieiri S, Nakatsuji T. Hirschsprung's disease in Japan: analysis of 3852 patients based on a nationwide survey in 30 years. *J Pediatr Surg.* 2005;40(1):197-202.
13. Scholl AM, Kirby ML. Signals controlling neural crest contributions to the heart. *Wiley Interdisciplinary Reviews: Systems Biol Med.* 2009;1(2):220-7.
14. Santos HE, Mateus JO, Leal MJ. Hirschsprung disease associated with polydactyly, unilateral renal agenesis, hypertelorism, and congenital deafness: a new autosomal recessive syndrome. *J Med Genetics.* 1988;25(3):204-5.
15. Laurence KM, Prosser R, Rucker I, Pearson JF, Richard C. Hirschsprung's disease associated with congenital heart malformation, broad big toes, and ulnar polydactyly in sibs: a case for fetoscopy. *J Med Genetics.* 1975;12(4):334-8.
16. Al-Gazali LI, Donnai D, Mueller RF. Hirschsprung's disease, hypoplastic nails, and minor dysmorphic features: a distinct autosomal recessive syndrome?. *J Med Genetics.* 1988;25(11):758-61.
17. Huang T, Elias ER, Mulliken JB, Kirse DJ, Holmes LB. A new syndrome: heart defects, laryngeal anomalies, preaxial polydactyly, and colonic aganglionosis in sibs. *Genetics Med.* 1999;1(3):104.
18. McLone DG. Normal and abnormal early development of the nervous system. *Pediatr Neurosurg: Surg Developing Nervous System.* 1994:3-9.
19. Neilson IR, Yazbeck S. Ultra short Hirschsprung's disease: myth or reality. *J Pediatr Surg.* 1990;25(11):35-8.
20. Torfs C. An epidemiological study of Hirschsprung's disease in a multiracial California population. In *Third International Meeting: Hirschsprung's disease and related neurocristopathies Evian, France.* 1998; 2004.
21. Badner JA, Sieber WK, Garver KL, Chakravarti AR. A genetic study of Hirschsprung disease. *Am J Human Genetics.* 1990;46(3):568.
22. Ikeda K, Goto S. Additional anomalies in Hirschsprung's disease: an analysis based on the nationwide survey in Japan. *Zeitschrift für Kinderchirurgie.* 1986;41(05):279-81.
23. Whalen TV Jr, Asch MJ. Report of two patients with hypertrophic pyloric stenosis and Hirschsprung's disease. Coincident or common etiology? *Am Surg.* 1985;51: 480-1.
24. Hirschsprung's disease and allied Disorders. 3rd ed. Prem Puri, AL Holschneider. 2019

Cite this article as: Patole MM, Patole MM, Paul S. A prospective observational study of associated anomalies in hirschsprung's disease. *Int J Contemp Pediatr* 2020;7:112-6.