

Case Report

Neurocognitive outcome in young child with Isovaleric Acidemia

Mangesh Prakash Narwade, Nusrat R. Inamdar*, Anupama V. Mauskar, Minal Wade, Ankita Shah

Department of Pediatrics, HBTMC and DR R N Cooper Hospital, Mumbai, Maharashtra, India

Received: 28 September 2019

Accepted: 04 October 2019

***Correspondence:**

Dr. Nusrat R Inamdar,

E-mail: nusratinamdar@gmail.com

Copyright: © the author(s), publisher and licensee Medip Academy. This is an open-access article distributed under the terms of the Creative Commons Attribution Non-Commercial License, which permits unrestricted non-commercial use, distribution, and reproduction in any medium, provided the original work is properly cited.

ABSTRACT

Isovaleric Acidemia (IVA) is inherited as an autosomal recessive trait, caused by the deficiency of the enzyme isovaleryl CoA dehydrogenase. It has the prevalence of 1 in 62,500 (in parts of Germany) to 1 in 250,000 live births (in the United States). Acute episodes of metabolic decompensations may occur, which may mimic sepsis, ketosis or shock. Early diagnosis & early initiation of treatment has been reported to correlate with a good neurocognitive outcome. This is case of child presenting in Paediatric emergency department with fever, vomiting, increased respiratory activity and lethargy. Child had GCS score of 8/15, acidotic breathing, hypotonia with hyporeflexia. Sepsis screen, metabolic work up and neuroimaging were all normal except for high anion Gap acidosis with ketosis. So further neurometabolic screening work up was done in view of persistent metabolic acidosis, developmental delay, and bad obstetric history in mother. It revealed increased excretion of isovalerylglycine 1 (IVG 1), Isovalerylglycine 2 (IVG2) Lactate, 3-Hydroxypropionate (3HP) and 3-Hydroxybutyrate (3 HB). Serum lactate 358.54 (control 1.1-208.1) confirming the diagnosis of Isovaleric Acidemia. After recovery from the acute attack, the patient was advised low-protein diet (1.0-1.5 g/kg/24 hrs.) and carnitine (100 mg/kg/24 hrs. orally) supplements. On follow up child is asymptomatic & showing neurological improvement as he started achieving further developmental milestones during 6 months follow up.

Early diagnosis and early treatment of IVA cases definitely results in favorable outcome and better prognosis. But chronic intermittent cases presenting late should not be neglected, proper medical management can reverse neuromotor consequences in them also.

Keywords: Acidosis, Developmental delay, Isovaleric acidemia, Medical management, Newborn Screening, Neurocognitive outcome

INTRODUCTION

Isovaleric Acidemia (IVA) is inherited as an autosomal recessive trait. The gene (IVD) has been mapped to chromosome 15q15.1 and many disease-causing mutations have been identified.¹ The prevalence of the condition is estimated from 1 in 62,500 (in parts of Germany) to 1 in 250,000 live births (in the United States).² Isovaleric acidemia, an inborn error of leucine catabolism, is caused by mutations in the isovaleryl-CoA dehydrogenase (IVD) gene, resulting in the accumulation

of derivatives of isovaleryl-CoA including isovaleryl (C5)-carnitine, the marker metabolite used for newborn screening (NBS).³ With evolving technologies, Prenatal diagnosis is also possible for IVA.⁴

The pathogenesis of the disease is still not fully understood. This condition is caused by the deficiency of the enzyme isovaleryl CoA dehydrogenase. The leucine catabolism is affected. Mechanisms thought to be involved include the induction of oxidative stress through accumulating metabolites as seen in the rat brain cortex

the reduction of Na⁺, K⁺-ATPase activity by free isovaleric acid as shown in synaptic membranes from the cerebral cortex in young rats.^{5,6}

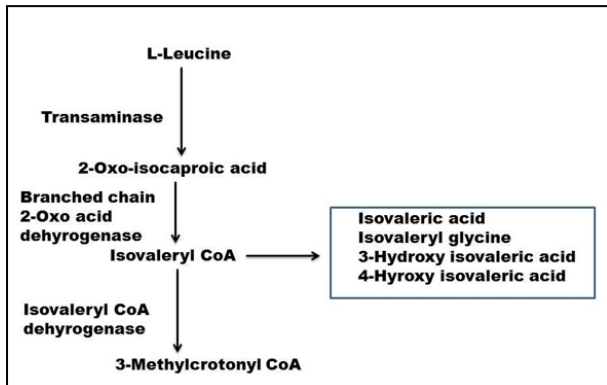


Figure 1: Catabolic pathway of leucine.

The intermediate metabolites that may be increased are shown in the box (Figure 1).

There are two forms of the disease

- Acute form appear in two weeks of life with lethargy, vomiting and dehydration.
- Chronic intermittent form occurs after stress or a high protein intake during later childhood.

Infants who survive this acute episode will go on to have the chronic intermittent form later in life. In both forms, acute episodes of metabolic decompensations may occur with stress/infection.⁷ Early initiation of treatment in IVA, i.e., starting therapy during the first weeks of life, was shown to decrease the frequency of severe ketoacidosis crises and was associated with an overall good clinical outcome and early diagnosis of IVA has been reported to correlate with a good neurocognitive outcome.^{8,9}

CASE REPORT

A 20 months old male child born of non-consanguineous marriage with history of two undiagnosed sibling deaths, with developmental age of 12 to 14 months, presented with fever, vomiting, increased respiratory activity and lethargy noticed 6-8 hours prior to admission. On examination GCS score was 8/15, acidotic breathing & the characteristic “sweaty feet” odor of body was present. Blood pressure was more than 90thcentile. Generalized hypotonia with hyporeflexia was noted, other systemic examination was within normal limit. Laboratory investigations revealed blood sugar levels of 90 mg/dl with severe metabolic acidosis on ABG; with high Anion Gap of 32. Chest x-ray was normal. CSF study was normal, CT scan brain was also normal. There was no laboratory evidence of end organ involvement. Metabolic screening profile of dried blood spot (TMS) and urine sample (GCMS) were sent, after parental consent. Child was managed in PICU with Intravenous fluids, antibiotics

and bicarbonate therapy. Child gradually showed improvement in the sensorium and activity during 1st 24 hours, but normalization of acidosis and ketosis took 5 days. Gas Chromatography/ Mass Spectrometry(GC/ MS) study of Urine sample showed increased excretion of isovalerylglycine 1 (IVG 1), Isovalerylglycine 2 (IVG2) Lactate, 3-Hydroxypropionate (3HP) and 3 Hydroxybutyrate(3HB). Serum lactate 358.54 (control 1.1-208.1). These reports confirmed diagnosis of Isovaleric Acidemia. The treatment of acute metabolic decompensation was done, with antibiotics, bicarbonate infusion and provision of calories with intra venous fluids for rehydration and to stop catabolic phase.

After recovery from the acute attack, the patient was advised low-protein diet (1.0-1.5 g/kg/24 hrs.) and carnitine (100 mg/kg/24 hrs. orally) supplements.

Child development has been followed up using Developmental Assessment Scale for Indian Infants (DASII) in developmental OPD regularly.

At the time of discharge, chronological age of the child was 1 year 8months with DASII assessment showing Apathetic Behaviour, Moderate Developmental delay with Developmental Motor Quotient of 66 and Developmental Mental Quotient of 62, mother was also explained about stimulation therapy along with importance of taking supplements regularly and diet modification. On follow up child is well and gaining weight. Child has shown neurological improvement as well as started achieving further developmental milestones. On recent follow up at chronological age of 2year 3months DASII assessment showed Playful and interactive Behaviour, Significant improved Development with Developmental Motor Quotient of 80 and Developmental Mental Quotient of 84.

DISCUSSION

Our child has presented with vomiting, lethargy, metabolic acidosis, increased anion gap and ketosis. These findings are similar to those found in case report of two cases of IVA by Narayanan MP.¹⁰ Because of such presentation it can be mistaken for sepsis or Diabetic ketoacidosis. He had also found hyperglycemia in two cases, which was not there in our case.

In this study we thought of doing metabolic screening in view of persistent metabolic acidosis, developmental delay, bad obstetric history in mother and normal sepsis screen and CSF/ neuroimaging study. We confirmed the diagnosis with Urine GCMS, which is confirmatory test for IVA.¹

As there are two forms of disease, acute form may prove lethal in early infancy. Diagnosis made within few days of birth were associated with more severe disease and mortality of 33%, whereas children diagnosed later and who had milder symptoms showed lower mortality rate of 3%.⁸

This case looks like chronic intermittent form, which got manifested due to acute infection.

Isovaleric acidemia (IVA), an inborn error of leucine catabolism, which can be diagnosed by newborn screening (NBS). Introduction of tandem mass spectrometry (TMS) allows the detection of elevated levels of C5-carnitine in dried blood spots. In urine, the elevation of isovaleryl glycine (IVG) confirms the metabolic diagnosis of IVA. Diagnosis can be confirmed by measurement of the enzyme activity in cultured skin fibroblasts or by the identification of the mutant gene.³ Prenatal diagnosis may be accomplished by measuring IVG in amniotic fluid, by enzyme assay in cultured amniocytes, or by identification of the mutant gene.⁴ Analysis of available evidence by Dionisi-Vici et al, showed a more than four times higher incidence of IVA in the screened population as compared to clinical diagnosis.¹¹

Our patient though presented with low GCS but improved with medical treatment. If patient is not treated on time then patient may progress to coma and death due to cerebral edema or cerebral haemorrhage.¹²

Early diagnosis and early treatment definitely results in favorable outcome as has been found in a three year follow up study of Narayanan et al.¹⁰

Study by Vardhan Patel also reported normal neuromotor outcome at 18 months in case of IVA diagnosed in first week of life managed with special formula in infancy with glycine and carnitine supplements.¹³

In contrast to these studies, our case presented late and had significant developmental delay at the time of presentation but with dietary modification (protein restriction), supplementation of carnitine showed significant improvement. Both his Motor Development Quotient and Mental Development Quotient almost normalized from moderately low within span of 6 months. Child's development is assessed using Developmental Assessment Scale for Indian Infants.

CONCLUSION

Early diagnosis and early treatment of IVA cases definitely results in favourable outcome and better prognosis, but chronic intermittent cases presenting late should not be neglected. Such cases do have developmental delay, but fatality rate is low, also proper medical management can reverse neuromotor consequences resulting in improved development and better outcome.

ACKNOWLEDGEMENTS

Authors would like to thank Dean and Head of the department for permitting to publish our case findings. We wish to thank the patient's parents and family for kindly agreeing to share the clinical information.

Funding: No funding sources

Conflict of interest: None declared

Ethical approval: Not required

REFERENCES

1. Vockley J, Ensenauer R. Isovaleric acidemia: new aspects of genetic and phenotypic heterogeneity. *Am J Med Genet Part C Semin Med Genet.* 2006 May 15;142C(2):95-103.
2. Ensenauer R, Vockley J, Willard JM, Huey JC, Sass JO, Edland SD, et al. A common mutation is associated with a mild, potentially asymptomatic phenotype in patients with isovaleric acidemia diagnosed by newborn screening. *Am J Human Genet.* 2004 Dec 1;75(6):1136-42.
3. Rezvani I, Rosenblatt DS. Valine, leucine, isoleucine, and related organic acidemias. *Nelson Textbook of Pediatrics 17th ed Philadelphia: Saunders.* 2004:409-33.
4. Schlune A, Riederer A, Mayatepek E, Ensenauer R. Aspects of newborn screening in isovaleric acidemia. *Internat J Neonatal Screening.* 2018 Mar;4(1):7.
5. Solano AF, Leipnitz G, Bortoli GM, Seminotti B, Amaral AU, Fernandes CG, et al. "Induction of oxidative stress by the metabolites accumulating in isovaleric acidemia in brain cortex of young rats". *Free Radical Res.* 2008;42(8):707-15.
6. Ribeiro CA, Balestro F, Grando V, Wajner M. Isovaleric acid reduces Na⁺, K⁺-ATPase activity in synaptic membranes from cerebral cortex of young rats. *Cellular Molecular Neurobiol.* 2007 Jun 1;27(4):529-40.
7. Vaidyanathan K, Narayanan MP, Vasudevan DM. Organic acidurias: an updated review. *Ind J Clin Biochem.* 2011 Oct;26(4): 319-25.
8. Grünert SC, Wendel U, Lindner M, Leichsenring M, Schwab KO, Vockley J, et al. Clinical and neurocognitive outcome in symptomatic isovaleric acidemia. *Orphanet J Rare Dis.* 2012 Dec;7(1):9.
9. Narayanan MP, Vaidyanathan K, Vasudevan DM. Clinical outcome of major organic acidemias- a three years follow-up study. *J Pediatr Biochem.* 2012 Sep;2(03):169-76.
10. Narayanan MP. Isovaleric Aciduria a Case Report of Two Patients. *Acta Scie Paed.* 2019 Aug;2(8):45-48.
11. Dionisi-Vici C, Deodato F, Röschinger W, Rhead W, Wilcken B. 'Classical' organic acidurias, propionic aciduria, methylmalonic aciduria and isovaleric aciduria: long-term outcome and effects of expanded newborn screening using tandem mass spectrometry. *J Inherited Meta Dis.* 2006 Apr;29(2-3):383-9.
12. Fischer AQ, Challa VR, Burton BK, McLean WT. Cerebellar hemorrhage complicating isovaleric acidemia: a case report. *Neurol.* 1981 Jun 1;31(6):746-8.

13. Patel V, Yadav S, Sahni M. A Rare Case of Inborn Error of Metabolism-Isovaleric Acidemia. IAIM, 2017;4(12):214-7.

Cite this article as: Narwade MP, Inamdar NR, Mauskar AV, Wade M, Shah A. Neurocognitive outcome in young child with Isovaleric acidemia. Int J Contemp Pediatr 2019;6:2716-9.