

## Review Article

# Collodion baby-congenital ichthyosis: clinical review

Rahul Choudhary<sup>1</sup>, Garima Sachdeva<sup>2\*</sup>, Gaurav Katoch<sup>1</sup>, Rakesh Kumar<sup>3</sup>

<sup>1</sup>Department of Paediatrics, North DMC Medical College & Hindu Rao Hospital, Delhi, India

<sup>2</sup>Department of Obstetrics and Gynaecology, North DMC Medical College & Hindu Rao Hospital, Delhi, India

<sup>3</sup>Department of Paediatrics, Himalayan Institute of Medical Sciences, Jolly Grant, Dehradun, Uttarakhand, India

**Received:** 11 July 2019

**Revised:** 13 September 2019

**Accepted:** 03 October 2019

### \*Correspondence:

Dr. Garima Sachdeva,

E-mail: [gsachdeva25@gmail.com](mailto:gsachdeva25@gmail.com)

**Copyright:** © the author(s), publisher and licensee Medip Academy. This is an open-access article distributed under the terms of the Creative Commons Attribution Non-Commercial License, which permits unrestricted non-commercial use, distribution, and reproduction in any medium, provided the original work is properly cited.

### ABSTRACT

Collodion baby is a rare form of congenital ichthyosis in which the entire body is covered by a parchment-like membrane. These neonates are at the risk of dehydration, sepsis, electrolyte disturbances, and temperature instability. It is inherited in autosomal recessive manner. We report a case of Collodion baby, born of a consanguineous marriage. Here, we present a short review of this condition and the various methods available for the prenatal diagnosis. A literature search was done using PubMed, Medline, and Google Scholar databases using the mesh terms “Ichthyosis”, “collodion baby”, “collodion membrane”, “Congenital ichthyosiform erythroderma”, and “Lamellar ichthyosis”.

**Keywords:** Autosomal recessive, Congenital ichthyosiform erythroderma, Collodion, Ectropion, Ichthyosis, Lamellar ichthyosis Prenatal screening

### INTRODUCTION

Ichthyosis term is derived from “ichthy”, which is a Greek word, meaning fish. It is used to describe a group of skin disorders in which the skin is covered with scales. Collodion baby is an extremely rare condition which is inherited in the autosomal recessive manner.

Collodion baby is a form of congenital ichthyosis, which is characterized by the presence of cellophane/parchment-like membrane which covers the entire body.<sup>1</sup> It is extremely rare dermatological condition with the reported incidence is around an incidence of 1 in 50,000-1 in 100,000 live births.<sup>1</sup> Due to loss of the normal function of the skin, these children are at the risk of increase trans-epidermal water loss (TEWL).<sup>2</sup> This makes these children prone to dehydration, hypothermia, and infection.<sup>3</sup>

This results in profound contraction abnormalities of face- eyes, ears, and mouth. Other features include the presence of ectropion (eversion of the eyelids), eversion of the lips (eclabion), abnormalities in the development of face and mouth, anonychia (absence of finger and/or toe-nails, hypoplastic fingers, and limited joint mobility.<sup>3</sup>

They have poor sucking, erythema, and oedema of the skin. These babies are at high risk for temperature instability (hypo/hyperthermia), respiratory difficulties, dehydration, electrolyte imbalances resulting in seizures, malnutrition and skin infection. These neonates are mostly born premature and the most common cause of death being dehydration and septicemia.<sup>3</sup>

It is autosomal recessive disorder. It has been linked with mutations in multiple genes like transglutaminase (TGM), ABCA12, ALOX12B, ALOXE3, NIPAL4, PNPLA1 and CYP4F22.<sup>4,5</sup>

## REVIEW OF LITERATURE

### Method of search

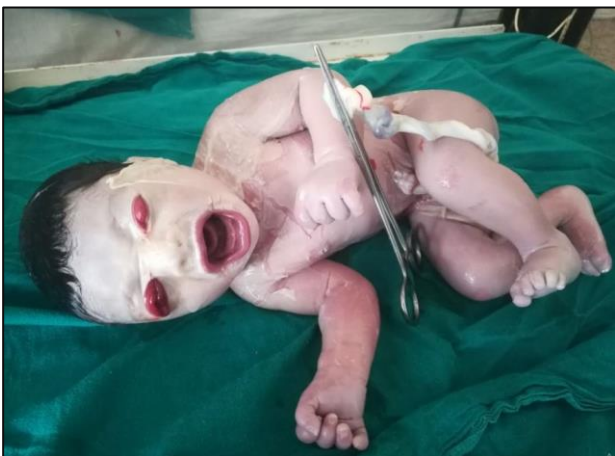A thorough literature search was done using PubMed, Medline, and Google Scholar databases using the mesh terms “Ichthyosis”, “collodion baby”, “collodion membrane”, “Congenital ichthyosiform erythroderma”, and “Lamellar ichthyosis”.

## DISCUSSION

Collodion baby is a rare type of genodermatosis, affecting both sexes equally. These neonates are most born prematurely with a cellophane/ parchment-like membrane encasing the entire body.

### Clinical presentation

Collodion baby is a form of congenital ichthyosis, which is characterized by the presence of cellophane/ parchment-like membrane which covers the entire body.<sup>4</sup> This results in profound contraction abnormalities of face- eyes, ears, and mouth. Other features include the presence of ectropion (eversion of the eyelids), eversion of the lips (eclabion), abnormalities in the development of face and mouth, anonychia (absence of finger and/or toe-nails, hypoplastic fingers, nose, and auricular cartilage, pseudo-contractions of limbs, and limited joint mobility.<sup>5</sup> Figure 1 shows a similar baby with thick hyper keratinized scaly skin with ectropion, eclabium, underdeveloped eyes and ears. The collodion membrane sometimes leads to restricted pulmonary function, digital vascular constriction, distal ischemia of the limbs, hyperhidrosis, poor sucking, erythema, and edema of the skin. These babies are at high risk for temperature instability (hypo/hyperthermia), respiratory difficulties, hypernatremic dehydration, electrolyte imbalances resulting in seizures, malnutrition, failure to thrive, and skin infection. These neonates are mostly born premature and the most common cause of death being dehydration and septicemia.<sup>5</sup>



**Figure 1: Collodion baby**

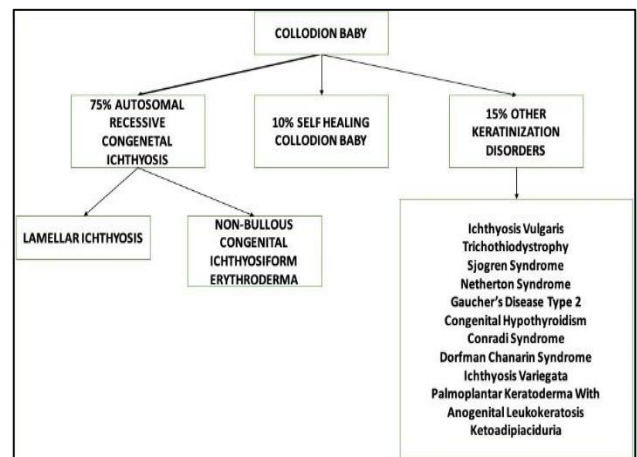
### Pathogenesis and genetic basis

The collodion membrane is formed due to the epidermal cornification. It occurs due to the genetic defect in the keratinocyte protein and lipid metabolism.<sup>6</sup> Multiple genes have been identified to take part in the pathogenesis. Most common of these genes, is TGM1 (transglutaminase 1), mapped on the chromosome 14q12.<sup>7</sup> Other genes include ABCA12, ALOX12B, ALOXE3, NIPAL4, PNPLA1, and CYP4F22.<sup>8,9</sup> These are inherited in the autosomal recessive fashion.

### Phenotypic variations of collodion baby

Collodion baby is a phenotypic diagnosis shared by different types of ichthyosis in early stages.<sup>10</sup> It is autosomal recessive disorder. It has been linked with mutations in multiple genes like transglutaminase (TGM), ABCA12, ALOX12B, ALOXE3, NIPAL4, PNPLA1, and CYP4F22.<sup>4,5</sup> Ichthyosis term is derived from “ichthy”, which is a Greek word, meaning fish. It is used to describe a group of skin disorders in which the skin is covered with scales. Collodion baby is an extremely rare condition which is inherited in the autosomal recessive manner. It is not possible to predict the final phenotypic appearance in babies born with a collodion membrane. The presence of collodion membrane is the initial expression of various forms of ichthyosis and it is not possible to ascertain the severity at the initial presentation.

Most of them (around 75%) evolve into NBCIE (nonbullous congenital ichthyosiform erythroderma) or LI (lamellar ichthyosis). Both NBCIE and LI have a similar presentation at birth and equally affects males and females.<sup>1</sup> They can be differentiated only after infancy when LI presents with brown plate-like scales on non-erythematous base while NBCIE is characterized by generalized erythroderma with overlying fine white scales.<sup>4</sup> Although, both LI and NBCIE have a normal life span, symptoms of LI remain severe throughout life while NBCIE improves after puberty.<sup>4</sup>



**Figure 2: Differential diagnosis of the collodion baby**

A new phenotype “self-healing collodion syndrome (SCHB)” has also been notified which presents in around 10% of the collodion babies.<sup>11</sup> These babies spontaneously shed their collodion membrane resulting in normal/ near-normal skin. Remaining 15% develop into various hyperkeratotic skin disorders. Figure 2 describes the various differential diagnosis of the collodion baby.

### **Diagnosis**

The diagnosis of collodion baby is primarily clinical. In case of doubt, one can go for a skin biopsy. We can analyze the activity of the enzyme transglutaminase on culture or by immunofluorescence on a cut section of the skin biopsy specimen.<sup>12</sup>

### **Treatment**

As the most common presentation of collodion baby is autosomal recessive congenital ichthyosis, it justifies the need of genetic counselling and prenatal diagnosis in the affected families. The earliest diagnosis is possible at around 10-12<sup>th</sup> weeks of gestation by using genomic PCR on chorionic villous sample or at 15-18<sup>th</sup> weeks by doing amniocentesis.<sup>9</sup> At around 18-20<sup>th</sup> weeks’ gestation fetoscopy and fetal skin biopsy can be done. Fetal skin biopsy can also help in detecting the ultrastructural abnormalities. Routine skin biopsy is not recommended.<sup>9</sup> However, if it is done transglutaminase-1 activity in frozen skin sections can be done. If molecular testing is done, the TGM1 gene should be first analysed.<sup>10</sup> If this is negative, then ALOX12B, ALOXE3, and NIPAL4 gene analysis can be done.<sup>8</sup> The prenatal diagnosis of this disease is now possible by identifying premature keratinization at the 18-20-week scan. In this era, when three, and four-dimensional real-time sonography is available, it is possible to identify the characteristic features of HI in these fetuses. These include identification of eversion of eyelids (ectropion), eversion of lips (eclabium), poor development of nostrils and ears, short fetal foot length, in-curved toes, clenched fists, and polyhydramnios. However, this phenotypic presentation is often late which may result in a delayed/ missed diagnosis of the disease.<sup>11</sup>

The management strategy should focus on providing protection to the skin barrier, control of infections, maintenance of fluid, and electrolyte balance, and early initiation of retinoid therapy.<sup>13</sup> The normal barrier function of the skin is lost in these babies. They are prone to infection, and excessive water loss resulting in hypernatremic dehydration and the inability to regulate body temperature.<sup>3</sup> These babies are mostly born premature and due to the high rates of mortality 10-20%, these children should be managed in the neonatal intensive care unit (NICU).<sup>14</sup> Topical emollients help in softening the skin, thus allowing for appropriate movement and deeper respiration by the infant. These children should be kept in an incubator with humidity in the range of 50-60% which is reasonable to decrease

trans-epidermal water loss. Humidification more than this can result in the growth of moulds and pseudomonas. Impaired sweating in these children can result in overheating, so the temperature of the incubator should be kept slightly lower (32-34 degree Celsius) to maintain body temperature.<sup>14</sup> Close monitoring should be done for electrolyte disturbances and for the signs and symptoms of sepsis. Appropriate intervention should be done to manage skin contractures and maximize mobility.<sup>14</sup>

Ectropion is a common finding in these children. Adequate lubrication of the exposed eye should be done to prevent damage. Persistent ectropion should be managed surgically or medically with periocular retinoids like tazarotene.<sup>15</sup> The use of systemic retinoids accelerates the shedding of hyperkeratotic plates and improves scaling. Together with enhanced moisturization, electrolyte monitoring in the early neonatal period, sepsis prevention and physiotherapy, long-term survival of 81% has been reported.

In the neonatal period, morbidity and mortality depend on the complications related to the collodion membrane like dehydration, electrolyte imbalances, sepsis, and respiratory compromise.<sup>12</sup> The neonate in the present case also succumbed to these complications. However, if the neonate survives these complications, later on, the prognosis depends on the definitive cause of the collodion baby.

### **Role of genetic counselling and prenatal diagnosis**

As the most common presentation of collodion baby is autosomal recessive congenital ichthyosis, it justifies the need of genetic counselling and prenatal diagnosis in the affected families. The earliest diagnosis is possible at around 10-12<sup>th</sup> weeks of gestation by using genomic PCR on chorionic villous sample or at 15-18<sup>th</sup> weeks by doing amniocentesis.<sup>12</sup> At around 18-20<sup>th</sup> weeks’ gestation fetoscopy and fetal skin biopsy can be done. Fetal skin biopsy can also help in detecting the ultrastructural abnormalities. Routine skin biopsy is not recommended.<sup>12</sup> However, if it is done transglutaminase-1 activity in frozen skin sections can be done. If molecular testing is done, the TGM1 gene should be first analysed.<sup>16</sup> If this is negative, then ALOX12B, ALOXE3, and NIPAL4 gene analysis can be done.<sup>11</sup>

The prenatal diagnosis of this disease is now possible by identifying premature keratinization at the 18-20-week scan. In this era, when three, and four-dimensional real-time sonography is available, it is possible to identify the characteristic features of HI in these fetuses. These include identification of eversion of eyelids (ectropion), eversion of lips (eclabium), poor development of nostrils and ears, short fetal foot length, in-curved toes, clenched fists, and polyhydramnios. However, this phenotypic presentation is often late which may result in a delayed/ missed diagnosis of the disease.<sup>17</sup>

## CONCLUSION

Collodion baby is a rare congenital disorder. The prognosis of the disease depends on the initial neonatal management. Collodion baby is a phenotypic diagnosis shared by different types of ichthyosis in early stages. Early diagnosis and multi-disciplinary approach are required to prevent long term morbidity and mortality. Genetic counselling in the families with children affected with congenital ichthyosis will help inform the patients about the risk of recurrence in the subsequent pregnancies, and make them aware about the possible strategy for undergoing prenatal diagnosis in the subsequent pregnancies.

## ACKNOWLEDGEMENTS

Authors would like to thank the parents of the newborn for their immense co-operation and for allowing us to publish the case and the photograph.

*Funding: No funding sources*

*Conflict of interest: None declared*

*Ethical approval: Not required*

## REFERENCES

- Dyer JA, Spraker M, Williams M. Care of the newborn with ichthyosis. *Dermatol Thera*. 2013;26(1):1-5.
- Buyse L, Graves C, Marks R, Wijeyesekera K, Alfaham M, Finlay AY. Collodion baby dehydration: the danger of high transepidermal water loss. *Brit J Dermatol*. 1993;129(1):86-8.
- Taïeb A, Labrèze C. Collodion baby: what's new. *J Europe Acade Dermatol Venereol*. 2002;16(5):436-7.
- Cortina WJ, Cruz MJ, Villalobos OA, Espinoza MA. Ictiosis congénita (feto arlequín). *Bol Med Hosp Infant Mex*. 1975;32:699-702.
- Moskowitz DG, Fowler AJ, Heyman MB, Cohen SP, Crumrine D, Elias PM, et al. Pathophysiologic basis for growth failure in children with ichthyosis: an evaluation of cutaneous ultrastructure, epidermal permeability barrier function, and energy expenditure. *J Pediatr*. 2004;145(1):82-92.
- Akiyama M, Shimizu H, Yoneda K, Nishikawa T. Collodion baby: ultrastructure and distribution of cornified cell envelope proteins and keratins. *Dermatol*. 1997;195(2):164-8.
- Sharma D, Gupta B, Shastri S, Pandita A, Pawar S. Collodion Baby with TGM1 gene mutation. *Internat Medi Case Repor J*. 2015;8:205.
- Grall A, Guaguere E, Planchais S, Grond S, Bourrat E, Hausser I, et al. PNPLA1 mutations cause autosomal recessive congenital ichthyosis in golden retriever dogs and humans. *Nat Genet*. 2012;44(2):140-7.
- Rimoin L, Graham Jr JM. Ichthyotic skin disorders in the neonate. *Clini pediatr*. 2012;51(8):796-800.
- Jasper KM, Gaudreau P, Cartee TV, Reilly BK. "Collodion baby": A unique challenge for newborn hearing screening. *Ameri J Otolaryngol*. 2016;37(3):263-4.
- Vahlquist A, Bygum A, Gånemo A, Virtanen M, Hellström-Pigg M, Strauss G, et al. Genotypic and clinical spectrum of self-improving collodion ichthyosis: ALOX12B, ALOXE3, and TGM1 mutations in Scandinavian patients. *J Investigat Dermatol*. 2010;130(2):438-43.
- Fatnassi R, Marouen N, Ragmoun H, Marzougui L, Hammami S. Collodion baby: clinical aspects and role of prenatal diagnosis. *Pan African Medi J*. 2017;26:118.
- Rossi G, Mesia D. Management of harlequin ichthyosis in low-income countries. *Annal Tropi Paediatr*. 2011;31(3):247-9.
- Oji V, Traupe H. Ichthyosis: clinical manifestations and practical treatment options. *Am J Clin Dermatol*. 2009;10(6):351-64.
- Chakraborti C, Tripathi P, Bandopadhyay G, Mazumder D. Congenital bilateral ectropion in lamellar ichthyosis. *Oman J Ophthalmol*. 2011;4(1):35.
- Cao X, Lin Z, Yang H, Bu D, Tu P, Chen L, et al. New mutations in the transglutaminase 1 gene in three families with lamellar ichthyosis. *Clinic Experi Dermatol: Experi Dermatol*. 2009;34(8):904-9.
- Ahmed H, O'Toole EA. Recent advances in the genetics and management of harlequin ichthyosis. *Pediatric Dermatol*. 2014;31(5):539-46.

**Cite this article as:** Choudhary R, Sachdeva G, Katoch G, Kumar R. Collodion baby-congenital ichthyosis: clinical review Int J Contemp Pediatr 2019;6:2746-9.