

Original Research Article

Ultrasound guided hydrostatic enema reduction of acute intussusception: guidelines in therapy and review of the institutional experience

Vivek Parameswara Sarma*

Department of Paediatric Surgery, SAT Hospital, Government Medical College Thiruvananthapuram, Kerala, India

Received: 05 May 2019

Revised: 02 December 2019

Accepted: 06 December 2019

*Correspondence:

Dr. Vivek Parameswara Sarma,
E-mail: vivsarma@gmail.com

Copyright: © the author(s), publisher and licensee Medip Academy. This is an open-access article distributed under the terms of the Creative Commons Attribution Non-Commercial License, which permits unrestricted non-commercial use, distribution, and reproduction in any medium, provided the original work is properly cited.

ABSTRACT

Background: In this review, author analyzed the cases of Acute Intussusception that underwent Ultrasound guided hydrostatic reduction during a one-year period. Author reviewed this treatment protocol and guidelines of non-operative and surgical therapy. The procedure followed and guidelines of therapy were reviewed and are detailed in the study.

Methods: Retrospective analysis of the hospital data of all patients who were treated for acute Intussusception during the period of January 2017 to December 2017 was done. All records including admission data, investigations, procedure records, preoperative details and operation notes, where applicable, post procedure recovery data and incidence of recurrence were studied. Inclusion criteria included confirmed sonological diagnosis of Intussusception verified by the treating paediatric surgeon, availability of all necessary records and absence of other co-morbidities. Exclusion criteria included age more than 2 years, children who had other major systemic disease, doubtful sonological diagnosis and postoperative intussusception. The paediatric surgeon himself performed the procedure in the dedicated ultrasound suite.

Results: The study was done in the mother and child wing of a medical college which is a tertiary referral centre catering to more than 200 cases of Intussusception per year. The records of 194 cases of Intussusception were available for analysis, of which only 176 could be included in the study. The age group included is 3 months to 3 years. The mean age was 11 months. The sex incidence was 94 cases in males and 82 in females.

Conclusions: Ultrasound guided hydrostatic reduction is a safe, effective and convenient modality for treatment of acute Intussusception, which can be performed by the treating Paediatric surgeon himself with requisite training and exposure.

Keywords: Honeycomb sign, Hydrostatic reduction, Intussusception, Target sign, Ultrasound guided

INTRODUCTION

The various options available for non-operative treatment of Intussusception include Ultrasound guided hydrostatic saline enema reduction, Fluoroscopy guided Air insufflation (Pneumatic reduction) and Fluoroscopy guided hydrostatic Barium saline enema reduction.¹⁻³

Ultrasound guided hydrostatic reduction has various merits compared to other non-operative modalities, which are analyzed here. Ultrasound guided hydrostatic saline enema reduction has been the standard therapy at authors institution since nearly 2 decades. Objective of the study was in this review; author analyzed the cases of Acute Intussusception that underwent Ultrasound guided

hydrostatic reduction during a one-year period. Author reviewed treatment protocol and guidelines of non-operative and surgical therapy. The procedure followed and guidelines of therapy were reviewed.

METHODS

Retrospective analysis of the hospital data of all patients who were treated for acute Intussusception during the period of January 2017 to December 2017 was done. All records including admission data, investigations, procedure records, preoperative details and operation notes, where applicable, post procedure recovery data and incidence of recurrence were studied.

Inclusion criteria

- Confirmed sonological diagnosis of Intussusception verified by the treating paediatric surgeon, availability of all necessary records and absence of other co-morbidities.

Exclusion criteria

- Age more than 2 years, children who had other major systemic disease, doubtful sonological diagnosis and post-operative intussusception. The paediatric surgeon himself performed the procedure in the dedicated ultrasound suite.

The study was done in the mother and child wing of a medical college which is a tertiary referral centre catering to more than 200 cases of Intussusception per year. The records of 194 cases of Intussusception were available for analysis, of which only 176 could be included in the study.

A detailed description of the standard procedure of hydrostatic reduction and the unusual types of Intussusception are included in the study. Most of patients presented early in the course of the disease due to the high awareness of the entity among referring physicians and the low threshold for an ultrasound abdomen. The treating Paediatric surgeon/resident, who is trained in basic sonology, performed the procedure himself/herself in a dedicated ultrasound suite.

The standard guidelines followed in the management are summarized here:

Pretreatment assessment of feasibility of non-operative treatment - favorable factors

- Short history (less than 24 hours)
- Age group less than 2 years
- No clinical features of advanced intestinal obstruction (bilious vomiting/ severe bleeding per rectum)
- Absent abdominal signs (distension/ tenderness/ guarding)

- Absent radiological signs (obstructive pattern on X ray)
- Absence of systemic complications

Contraindications for non-operative treatment of Intussusception

- History greater than 24-48 hours
- Clinical evidence of advanced intestinal obstruction [Severe bleeding per rectum, Abdominal distension, Abdominal tenderness and guarding, Poor general condition (acute circulatory failure/ dyselectrolytemias)]
- Radiological evidence of advanced intestinal obstruction [X ray abdomen showing multiple small bowel air fluid levels with sparse gas in colon-feature of advanced Intussusception / small bowel Intussusception]
- Age of child more than 5 years (high probability of lead point)
- Diagnosis of small bowel Intussusception (post-operative etc.)

The procedure of Ultrasound guided hydrostatic saline enema reduction (institutional protocol)

Preparation of the patient

The diagnosis, planned therapy, success rate and possibility of need for surgery should be discussed with the care takers of the child and informed consent is obtained. Child should be kept nil per orally and nasogastric tube inserted if child is vomiting. Parenteral fluids, preferably Normal saline, is started. Hemogram and serum electrolytes should be assessed. The child is sedated with Inj. Pethidine (0.5 mg/kg IM) and Inj. Promethazine (0.5 mg/kg IM)/ Inj Midazolam (0.1 mg/kg slow IV).

The necessary equipments

Foley's catheter-16 Fr, Normal saline-1 liter warmed to body temperature, Macro infusion set, Inj. Hyoscine, Inj Midazolam

The procedure

Confirm the presence and site of the mass on USS. Insert the Foley's catheter into rectum and inflate the bulb gently to 30 ml. infuse the NS at 3 feet height from the patient. Hold the child's legs together at knee. Watch for the gradual reduction by the filling up of colonic loops proximally with saline and the retrograde movement of the mass along the colon. Make sure that the saline is flowing freely, and no leakage of saline is present through anus (Figure 1, 2).

The extent of progression and presence of bowel wall edema can also be assessed. The mass becomes more

prominent of infusing saline for hydrostatic reduction, and this can be used to clarify the diagnosis in a doubtful situation. The terminal part of reduction at the caecum is usually the most difficult and takes the maximum time. The child will usually strain severely, and flow of saline will be slow at this point. Inj Hyoscine can facilitate reduction of the terminal part of Intussusception.

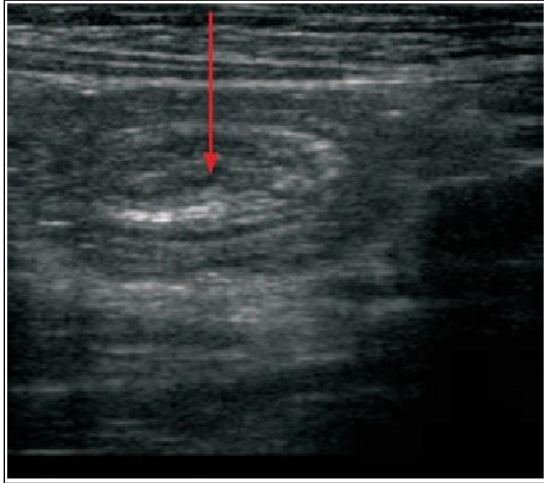


Figure 1: Ultrasound demonstration of Target sign/Donut sign.

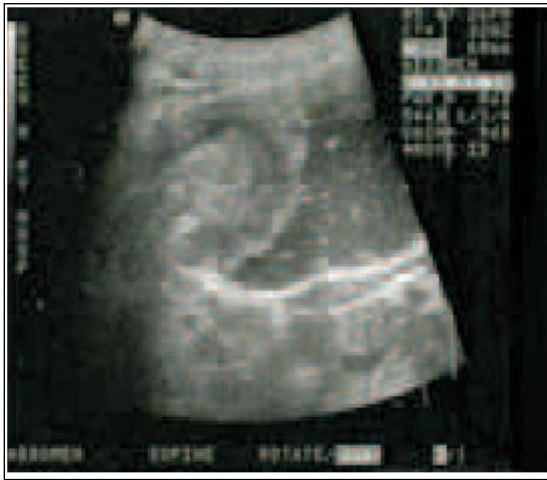

Figure 2: Ultrasound demonstration of the movement of mass with saline infusion.

The features of reduction of Intussusception

- The child suddenly becomes comfortable and asymptomatic
- Normal saline flows freely
- Disappearance of the 'Target' sign
- Appearance of filled small bowel loops ('Honeycomb' sign)
- Disappearance of the previously filled colonic loops

The absence of colonic loops to decompress or failure of small bowel loops to fill freely should alert to the

possibility of incomplete reduction of Intussusception. (Figure 3).

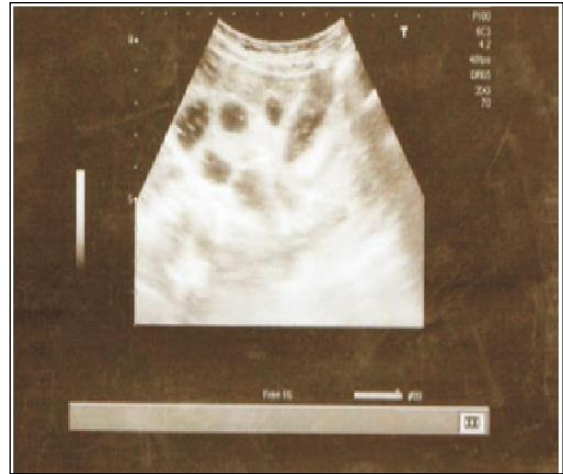

Figure 3: Ultrasound demonstration of the honeycomb sign of reduction of intussusception.

Concluding the procedure

It is advisable to wait for the small bowel loops to fill well before stopping the infusion. Empty the fluid in the colon by gravity drainage of the infusion set. Deflate the Foley's catheter bulb and remove after 5-10 minutes. The child is kept NPO for 6 hours and closely monitored.

Difficult reduction or non-reduction

The features are persistence of the mass at the same initial point or very slow movement of the mass. The mass can also commonly be static at the caecum with difficulty in reduction at the most terminal part. The bowel wall is commonly edematous, and reduction does not progress. Typically, in a difficult reduction, the free flow of saline absent and the child continues to strain severely.

Repeated attempts at reduction

If some movement of the mass was present initially/ mass reduced till the caecum initially, and the child has no abdominal signs; repeat attempt at reduction can be done after about 2 hours. Parenteral Antibiotics are started. More than 3 attempts at hydrostatic reduction are not tried and proceeding with hydrostatic reduction for more than 6 hours is not advisable. In a child older than 2 years, more than 2 attempts are not advisable.

The following factors are predictive of less likelihood of successful hydrostatic reduction

- Persistence of the mass at the initial point
- The mass does not move proximally
- The proximal colonic loops do not fill up
- The mass does not reduce beyond the caecum
- Severe bowel wall edema

- Absence of free flow of saline
- Child strains continuously

Causes of non-reduction of Intussusception

- Ischemic intestine
- Edematous intestine
- Presence of a lead point (Meckel's diverticulum is the commonest/ small bowel lesions like lymphoma)³
- Ileo-ileo-colic intussusception (Compound intussusception)¹⁻³

Indications to proceed to surgery

- Any contraindication to non-operative treatment (previously listed).
- When there is no movement of mass from initial position, with no flow of the saline infusion.^{3,4}
- When the mass does not move beyond the caecum on attempted reduction.
- Failure of 3 attempts at reduction

RESULTS

The various aspects of the study and the observations are summarized in Tables (1 to 8), which summaries the clinical presentation, treatment options used, attempts at hydrostatic reduction, incidence of recurrence, surgical findings and the post procedure recovery.

Table 1: Clinical presentation of Intussusception, noted as per admission records.

Clinical presentation	No. of cases (total 176)
Abdominal pain, vomiting	176
Red currant jelly stools	90
Palpable abdominal lump	84
Mass palpable per rectum	3
X-ray evidence of intestinal obstruction	11
Systemic complications (Hypotension/ Acute circulatory failure/ Major dyselektrolytemia/ Seizures)	9

Table 2: Treatment modality used for Intussusception.

Treatment of intussusception	No. of cases (total 176)
Non operative - US guided Hydrostatic enema reduction	152
Surgical - Laparotomy	24

The most common clinical presentation was abdominal pain and vomiting followed by red currant jelly stools and palpable abdominal lump. 152/176 (86%) patients underwent US guided Hydrostatic enema reduction, while 24/176 (14%) required surgical exploration.

Table 3: Attempts required at hydrostatic reduction of Intussusception.

Attempts at hydrostatic reduction	No. of cases (total 152)
Single attempt	106
Two attempts	46

106/152 (70%) cases that underwent US guided Hydrostatic enema reduction could be reduced in a single attempt, while 46/152 (30%) required 2 attempts. None of the cases underwent three attempts.

Table 4: Incidence of recurrence of Intussusception during the immediate post- treatment period (before one week).

Recurrence of intussusception	No. of cases (total 176)
After hydrostatic reduction	24
After laparotomy	0

Incidence of recurrence of Intussusception during the immediate post- treatment period (before one week) after hydrostatic reduction was 14% (24/176). There were no recurrences after laparotomy.

Table 5: Surgical treatment of Intussusception.

Surgery for intussusception	No. of cases (total 24)
Primary laparotomy (without trial of hydrostatic reduction)	11
Laparotomy after failed trial of hydrostatic reduction	13

11/24 cases underwent Primary laparotomy (without trial of hydrostatic reduction) while 13/24 cases underwent Laparotomy after failed trial of hydrostatic reduction. The most common intra-operative finding at laparotomy was Classical ileo-colic intussusception (Figure 4) (17/24), followed by ileo-ileo-colic intussusception and Ileo-ileo-colic with Lead point (Meckel's diverticulum).

Table 6: Intra operative findings in cases that underwent either primary laparotomy or laparotomy after trial of USG hydrostatic enema reduction.

Intra-operative findings	No. of cases (total 24)
Classical ileo-colic intussusception	17
Ileo-ileo-colic (Compound) intussusception	4
Ileo-ileo-colic with Lead point (Meckel's diverticulum)	3
Additional ileo-ileal component	2
Mesenteric adenitis	18

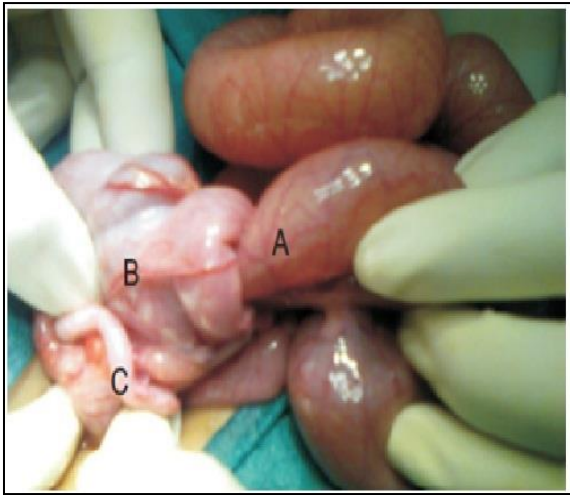


Figure 4: Classical Ileo-colic Intussusception with A. Ileum B. Cecum C. Vermiform Appendix.

Table 7: Recovery after hydrostatic reduction.

Post procedure recovery	No. of cases (total 152)
Mean time of initiation of oral feeds	After 6 hours
Mean duration of hospital stay	48 hours
Recurrence	24
Post procedure loose stools	46

Post procedure recovery was unremarkable with no significant complications in majority of patients.

Table 8: Recovery after surgery for Intussusception.

Post operative recovery	No. of cases (total 24)
Initiation of oral feeds	After 24-72 hours
Duration of hospital stay	5-10 days
Passage of blood in stool	2-8 days
Prolonged ileus (>24 hours)	5
Wound infection	2
Recurrence	0

After laparotomy for intussusceptions also, there were no major complications.

DISCUSSION

Advantages of Ultrasound guided hydrostatic saline enema reduction

- Easy and reproducible technique.
- No radiation exposure to the patient or surgeon, which is vital considering that all alternatives involve risk of radiation, especially to a young infant, and the risk to the bystander and repeated radiation exposure to the surgeon.^{4,5}
- Lesser risk of bowel perforation.^{4,5}

- High success rate comparable to other techniques of non-operative treatment.^{5,6}
- Repeated attempts are easier.

The most difficult part of the procedure which can be learned only from experience is the declaration of the end point of trial of hydrostatic reduction and the decision to proceed to surgery.

Complicated intussusception

Although it is uncommon with the advent of early USS diagnosis, cases of intussusception do still present with complications like dehydration, acute circulatory failure, hypotension and dyselectrolytemias-mainly hyponatremia and hypokalemia (due to third space loss and bleeding).^{6,7} The possibility of presence of ischemic intestine should also be considered. These patients require resuscitation and stabilization prior to any intervention.

Optimization of fluid and electrolyte balance is vital. After stabilization, if abdominal signs are absent, a trial of non-operative treatment can be given. In the presence of clinical/ radiological evidence of advanced intestinal obstruction, laparotomy should be done after stabilization.^{7,8}

Recurrent Intussusception

Recurrence can occur following non operative treatment or operative treatment. A high index of suspicion is required to make the diagnosis. Two more trials of non-operative treatment can be given in the absence of abdominal signs or complications.⁸

Specific situations with regard to Intussusception

Small bowel intussusception and compound intussusception (Ileo- ileo-colic Intussusception)

clinically this should be suspected in children with early onset of abdominal distension, bilious vomiting and systemic complications. An X ray will show features of distal small bowel obstruction with multiple central air fluid levels and sparse gas in colon. An ileo- ileal intussusception cannot be seen or reduced by USS guidance and Ileo-ileo-colic Intussusception should be considered in all cases of difficult reduction.⁹ Treatment is essentially surgical.

Post-operative Intussusception

This usually occur mainly after retroperitoneal surgeries like Nephroureterectomy for Wilm's tumor/Pyeloplasty. Classical presentation is with features of early onset intestinal obstruction and needs a high index of suspicion for diagnosis. The intussusception is usually jejuno-jejunal or ileo-ileal. An X ray will show features of small bowel obstruction. The treatment is surgical.¹⁰

Intussusception with mass prolapsed per rectum

This has to be distinguished clinically from rectal prolapse. Although it is usually advanced and requires laparotomy, non-operative treatment may still be possible if the mass can be reduced back into the rectum and Foley's bulb be inflated in the rectum. A short history and absence of abdominal signs or systemic complications favour a trial of non-operative treatment.

CONCLUSION

Ultrasound guided hydrostatic reduction is a safe, effective and convenient modality for non-operative treatment of acute Intussusception, which can be performed by the treating Paediatric surgeon with requisite training and exposure.

Funding: No funding sources

Conflict of interest: None declared

Ethical approval: Not required

REFERENCES

1. Liu SJ. Enema reduction of intussusception by hydrostatic pressure under ultrasound guidance: a report of 377 cases. J Pediatr Surg. 1988 Sep 1;23(9):814-8.
2. Khong PL, Peh WC, Lam CH, Chan KL, Cheng W, Lam WW, et al. Ultrasound-guided hydrostatic reduction of childhood intussusception: technique and demonstration. Radiographics. 2000;20(5):1-.
3. Daneman A, Navarro O. Intussusception. Pediatr Radiol. 2003;33(2):79-85.
4. Sarin YK, Rao JS, Stephen E. Ultrasound guided water enema for hydrostatic reduction of childhood intussusception-a preliminary experience. Ind J Radiol Imaging. 1999;9(2):59.
5. Hameed S. Ultrasound guided hydrostatic reduction in the management of intussusception. Ind J Pediatr. 2006;73(3):217-20.
6. Henry PY, Joseph JS. Childhood intussusception-Saline hydrostatic reduction under ultrasound guidance: a prospective study. J Ind Assoc Pediatr Surg. 2000;5(2):51.
7. Van den Ende ED, Allema JH, Hazebroek FW, Breslau PJ. Success with hydrostatic reduction of intussusception in relation to duration of symptoms. Archiv Dis Childhood. 2005;90(10):1071-2.
8. González-Spínola J, Del Pozo G, Tejedor D, Blanco A. Intussusception: the accuracy of ultrasound-guided saline enema and the usefulness of a delayed attempt at reduction. J Pediatr Surg. 1999;34(6):1016-20.
9. Eklöf OA, Johanson L, Löhr G. Childhood intussusception: hydrostatic reducibility and incidence of leading points in different age groups. Pediatric Radiol. 1980;10(2):83-6.
10. Del-Pozo G, Albillos JC, Tejedor D, Calero R, Rasero M, de-la-Calle U, et al. Intussusception in children: current concepts in diagnosis and enema reduction. Radiographics. 1999;19(2):299-319.

Cite this article as: Sarma VP. Ultrasound guided hydrostatic enema reduction of acute intussusception: guidelines in therapy and review of the institutional experience. Int J Contemp Pediatr 2020;7:305-10.