

Case Report

Acute kidney injury in a critically ill influenza: a H1N1 infected child

Dinesh Kumar Jayapalan, Sangeetha Geminiganesan*, Shruthi Parthasarathy,
Niranjana Varadharaju, Nithya Bhaskar

Department of Pediatrics, Sri Ramachandra Hospital, Porur, Chennai, Tamil Nadu, India

Received: 04 April 2019

Accepted: 02 May 2019

*Correspondence:

Dr. Sangeetha Geminiganesan,
E-mail: drdeenu03@yahoo.com

Copyright: © the author(s), publisher and licensee Medip Academy. This is an open-access article distributed under the terms of the Creative Commons Attribution Non-Commercial License, which permits unrestricted non-commercial use, distribution, and reproduction in any medium, provided the original work is properly cited.

ABSTRACT

Influenza H1N1 infection is a globally recognized epidemic and is known for several extra-pulmonary complications. Here, for the first time we report a case of a six-year old male child with severe H1N1 infection with acute kidney injury. The child was referred to our center with fever, chills, cough and cold for 2 days. Investigations revealed H1N1 infection with deranged LFT and RFT with anuria. Child was subjected to mechanical ventilation and received higher antibiotics in addition to oseltamivir. The child underwent 13 cycles of hemodialysis and renal profile normalized after a period of 35 days. Our case highlights the importance of recognizing extra-pulmonary complications of H1N1 infection in the pediatric population and the preparation required by healthcare practitioners to reduce the associated mortality.

Keywords: Acute Renal failure in H1N1 infection, Complication of H1N1 infection, H1N1 in children

INTRODUCTION

H1N1 influenza A infection has remained a major epidemic issue in India for several years. From 2009 to 2018, over 10000 deaths have been reported.^{1,2} Although the primary clinical manifestation is through respiratory illness, the true burden of influenza infection is likely much larger, as it is also known to affect other organ systems apart from the respiratory tract. Extra pulmonary manifestations of H1N1 could be due to the unique viral pathogenesis and/or the status of the affected individual like age, co-morbidities and genetic predisposition. Extra-pulmonary complications of cardiac, neurologic, ocular, renal, musculoskeletal, hepatic, hematologic, and endocrine nature are reported to manifest in the acute phase.³ Here, we report a rare case of H1N1 infection with extra-pulmonary complication presenting as Acute Kidney Injury (AKI) in a 6-year old child.

CASE REPORT

A six-year old male child was referred to our center with high-grade fever, cough and coryza for two days with normal nutritional status. He also had reduced urine output and painless cola-urine for a day. He did not have history of skin lesions, sore throat, dysuria and seizures. On examination, he was tachypneic with a heart rate of 120/min, respiratory rate of 50/min, saturation of 90% in room air, and BP of 130/90 mmHg (Table 1).

He also had intercostal and subcostal retractions. On auscultation, he had bilateral wheeze and crepitations. Baseline blood investigations revealed normal platelets, leucopenia (3100 cells/cumm) with polymorphic predominance (70%), and elevated C reactive protein (1.2 gm/dL). Chest X-ray revealed bilateral diffuse opacities sparing left upper lobe, suggestive of acute respiratory distress syndrome. H1N1 RT-PCR investigation of throat

swab was positive (he was not vaccinated for influenza A). In view of worsening respiratory distress, he was kept under mechanical ventilation and treated with oseltamivir and piperacillin-tazobactam which was stopped after ensuring the sterile blood culture report. In parallel, his renal parameters were elevated (blood urea nitrogen-53 mg/dL, serum creatinine-4.7 mg/dL) with metabolic acidosis. Proteinuria of 3+ and plenty of RBC/HPF were noted in urine routine. USG showed normal kidney sizes with increased echogenicity and ascites. Since the child was anuric for over 6 hours, he was initiated on hemodialysis through the right femoral venous access using double lumen 9 Fr hemodialysis catheter. Renal biopsy revealed acute tubular injury with acute interstitial nephritis (Figure 1).

Table 1: Parameters of the child at the time of admission.

| Parameters | Values |
|---|--------|
| APACHE II score | 34 |
| ARDS | Yes |
| PaO ₂ /FIO ₂ , mm Hg | 170 |
| Initial mean arterial pressure, mm Hg | 55 |
| Heart rate, per min | 120 |
| Temperature, F | 100 |
| C-reactive protein, mg/dL | 9.6 |
| pH | 7.2 |
| Bicarbonate, mEq/L | 19 |
| White blood cell count, ×10 ³ /mm ³ | 3100 |
| Platelet count, ×10 ³ /μL | 1.47 |
| Creatinine, mg/dL | 4.7 |
| Bilirubin, mg/dL | 0.92 |
| AST, U/L | 4820 |
| ALT, U/L | 6110 |
| Sodium, mmol/L | 126 |
| Potassium, mmol/L | 4.3 |

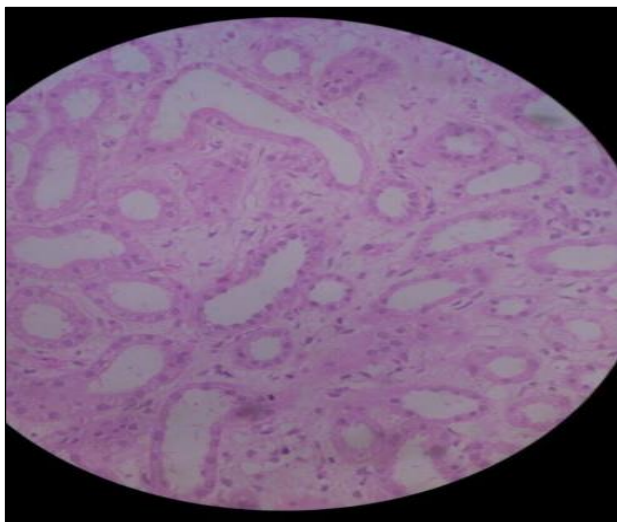


Figure 1: Renal biopsy showing disruption of epithelial lining of the tubules with intestinal oedema.

A total of 13 cycles of hemodialysis was done over a period of 3 weeks, and the child started making urine after 5 sessions of hemodialysis. His urine output gradually improved and his renal parameters normalized in the subsequent weeks.

At the end of 3 weeks, his blood urea nitrogen recovered to 14 mg/dL and serum creatinine of 0.4 mg/dL. During the course, the child also had acute liver injury for which he was treated with N-Acetyl cysteine, which resumed liver function to normalcy after a week. After 4 weeks of illness the child completely recovered and is observed to be doing well on subsequent follow-ups with normal blood pressure and renal functions.

DISCUSSION

Influenza typically presents with abrupt onset of fever, malaise, myalgia, headache, and dry cough. Respiratory tract manifestations include tracheitis, bronchitis, and pneumonia. Commonly, serious complications of influenza are pulmonary in nature and include primary viral pneumonia and pneumonia due to secondary bacterial infection. AKI due to H1N1 infection has been previously reported in older patients with co-morbidities such as diabetes and obesity.⁴⁻¹⁰

To authors knowledge, Authors report the first case AKI due to H1N1 infection on a previously healthy child. A recent comprehensive review on extra-pulmonary complications of influenza infections showed that the most commonly reported ones include that of cardiac and neurological nature.¹⁰ Renal complications are less commonly reported, although not rare, and include presentations such as AKI, acute glomerulonephritis, minimal change disease, and acute tubulointerstitial nephritis. A prospective observational cohort study conducted in adult ICU settings revealed that influenza-associated AKI was observed in 18% to 66% of the patients. Of these, 18% to 60% of the patients required continuous renal replacement therapy.^{5,7-9}

Patients with influenza-associated AKI had a higher Acute Physiology and Chronic Health Evaluation II score (APACHE), a higher Sequential Organ Failure Assessment score (SOFA), need for mechanical ventilation, greater incidence of shock, and greater incidence of multiorgan dysfunction syndrome and co-infection.⁷ Indeed, the child described in this report had high APACHE score and required mechanical ventilation and dialysis support. The risk factors for the development of influenza-associated AKI include obesity, presence of chronic kidney disease prior to illness, older age, and increased severity of illness at admission.^{4,6,10}

All of the studies on the epidemic H1N1 virus unanimously report AKI only on older individuals, between 44 and 66 years, and to our knowledge this is the first report of AKI in a previously healthy 6-year old

pediatric individual.⁴⁻¹⁰ Naturally, questions on the etiology of the extrapulmonary impact in a pediatric context remain to be addressed. The child had no previous reported kidney or respiratory illness and did not have obesity. The child, however, did present with severe respiratory illness (APACHE score of 32) at the time of admission, suggesting that the severity of illness at the time of presentation could be the more critical factor over others in predisposition towards renal impact. Similar to other influenza viruses, H1N1 affects primarily the upper and lower respiratory tract. Several pathophysiologic mechanisms may account for development of AKI in critically ill H1N1 patients. To begin with, acute tubular injury could be caused by decreased renal perfusion secondary to hypovolemia or due to renal constriction frequently associated with severe influenza infection.¹¹ Rhabdomyolysis may also contribute to AKI development, as studies have reported viral pneumonia with rhabdomyolysis and acute renal failure.^{12,13} This is also substantiated by several studies that have shown moderate correlation of increased creatine kinase levels with AKI, a definite marker of rhabdomyolysis.^{4,6,13,14} Although creatine kinase levels was not measured for the child in this report, creatinine levels were found to be very high, at levels as seen with AKI.^{4,6,9}

The high levels of serum creatinine are not typically considered as correlative with rhabdomyolysis in young muscular men.¹⁵ Since the child in this report is too young to be considered young muscular male, there is good likeliness that the high creatinine concentration observed in the child could be directly due to rhabdomyolysis. Direct viral injury to the kidneys would be the easiest explanation for AKI as a complication of influenza infection; but evidence remains scanty to support this notion.³ Though disease management is mainly supportive, it emerges to be a critical learning from this episode. In all the reports, renal replacement therapy upon influenza infection was typically associated with mechanical ventilation, extended ICU stay, and ECMO.⁴⁻¹⁰

Furthermore, several reports have shown that higher mortality is correlated with influenza-associated acute renal injury.^{5,7-10} Being a tertiary care centre, intensive care with all the aforementioned features could be extended to the child discussed in this report to ensure complete recovery. Enhanced investment of resources, including health care practitioners and expanded capacity is suggested to healthcare policy-makers to reduce mortality due to the seasonal influenza epidemics.

Funding: No funding sources

Conflict of interest: None declared

Ethical approval: Not required

REFERENCES

1. Seasonal Influenza (H1N1)-State/UT wise, Year-wise number of cases and death from 2010 to 2017

- Delhi: National Center for Disease Control. Available at: <https://ncdc.gov.in/showfile.php?lid=275>.
2. Seasonal Influenza (H1N1)- State/UT - wise, Year-wise number of cases and deaths from 2011-2018 Delhi: National Center For Disease Control. Available at: <https://ncdc.gov.in/showfile.php?lid=280>.
3. Sellers SA, Hagan RS, Hayden FG, Fischer WA 2nd. The hidden burden of influenza: A review of the extra-pulmonary complications of influenza infection. *Influenza Other Respir Viruses.* 2017;11(5):372-93.
4. Bagshaw SM, Sood MM, Long J, Fowler RA, Adhikari NK, Canadian Critical Care Trials Group HNC. Acute kidney injury among critically ill patients with pandemic H1N1 influenza A in Canada: cohort study. *BMC Nephrol.* 2013;14(1):123.
5. Demirjian SG, Raina R, Bhimraj A, Navaneethan SD, Gordon SM, Schreiber MJ, et al. 2009 influenza A infection and acute kidney injury: incidence, risk factors, and complications. *Am J Nephrol.* 2011;34(1):1-8.
6. Jung JY, Park BH, Hong SB, Koh Y, Suh GY, Jeon K, et al. Acute kidney injury in critically ill patients with pandemic influenza A pneumonia 2009 in Korea: a multicenter study. *J Crit Care.* 2011;26(6):577-8.
7. Martin-Loeches I, Papiol E, Rodriguez A, Diaz E, Zaragoza R, Granada RM, et al. Acute kidney injury in critical ill patients affected by influenza A (H1N1) virus infection. *Crit Care.* 2011;15(1):R66.
8. Nin N, Lorente JA, Soto L, Rios F, Hurtado J, Arancibia F, et al. Acute kidney injury in critically ill patients with 2009 influenza A (H1N1) viral pneumonia: an observational study. *Intensive Care Med.* 2011;37(5):768-74.
9. Pettita V, Webb SA, Bailey M, Howe B, Seppelt IM, Bellomo R. Acute kidney injury in patients with influenza A (H1N1) 2009. *Intensive Care Med.* 2011;37(5):763-7.
10. Tignanelli CJ, Wiktor AJ, Vatsaas CJ, Sachdev G, Heung M, Park PK, et al. Outcomes of Acute Kidney Injury in Patients with Severe ARDS Due to Influenza A(H1N1) pdm09 Virus. *Am J Crit Care.* 2018;27(1):67-73.
11. Sood MM, Rigatto C, Zarychanski R, Komenda P, Sood AR, Bueti J, et al. Acute kidney injury in critically ill patients infected with 2009 pandemic influenza A (H1N1): report from a Canadian Province. *Am J Kidney Dis.* 2010;55(5):848-55.
12. Abe M, Higuchi T, Okada K, Kaizu K, Matsumoto K. Clinical study of influenza-associated rhabdomyolysis with acute renal failure. *Clin Nephrol.* 2006;66(3):166-70.
13. Ayala E, Kagawa FT, Wehner JH, Tam J, Upadhyay D. Rhabdomyolysis associated with 2009 influenza A(H1N1). *JAMA.* 2009;302(17):1863-4.

14. Fearnley RA, Lines SW, Lewington AJ, Bodenham AR. Influenza A-induced rhabdomyolysis and acute kidney injury complicated by posterior reversible encephalopathy syndrome. *Anaesthesia*. 2011;66(8):738-42.
15. Bosch X, Poch E, Grau JM. Rhabdomyolysis and acute kidney injury. *N Engl J Med*. 2009;361(1):62-72.

Cite this article as: Jayapalan DK, Geminiganesan S, Parthasarathy S, Varadharaju N, Bhaskar N. Acute kidney injury in a critically ill influenza: a H1N1 infected child. *Int J Contemp Pediatr* 2019;6:1760-3.