

Case Report

Rett syndrome: a neurodevelopmental disorder

Setu Dagli^{1*}, Arpita Thakker Adhikari², Mona Gajre²

¹Student, ²Department of Pediatrics, Epilepsy and Developmental Pediatrics, Lokmanya Tilak Municipal Medical College and General Hospital, Mumbai, Maharashtra, India

Received: 03 April 2019

Accepted: 02 May 2019

*Correspondence:

Dr. Setu Dagli,

E-mail: setudagli1905@gmail.com

Copyright: © the author(s), publisher and licensee Medip Academy. This is an open-access article distributed under the terms of the Creative Commons Attribution Non-Commercial License, which permits unrestricted non-commercial use, distribution, and reproduction in any medium, provided the original work is properly cited.

ABSTRACT

Rett Syndrome is a rare genetic disorder caused by a mutation on the *MECP2* gene on the X chromosome. It classically presents with neuroregression, loss of purposeful hand use, stereotypical involuntary hand wringing movements, an ataxic gait and acquired microcephaly with a large proportion of patients developing seizures. The authors present the case of a 3.5 year old girl with severe global developmental delay and regression, loss of purposeful hand use and an ataxic gait for 2 years and seizures since 5 days along with microcephaly with involuntary hand movements but no classic wringing movements with no significant findings on MRI and EEG and diagnosed with Rett Syndrome on the basis of genetic testing.

Keywords: Neuroregression, Microcephaly, *MECP2* gene

INTRODUCTION

Rett syndrome is a rare genetic disorder first described by Andreas Rett in Vienna in 1966.¹ He published his findings in several German medical journals, but it did not gain wide circulation. It gained worldwide recognition only in 1983 after it was published by Bengt Hagberg, a Swedish child neurologist and his colleagues in the journal, *Annals of Neurology*.²

Rett Syndrome is a pervasive developmental disorder with a classic behavioral pattern caused by a genetic mutation most commonly on the *MECP2* gene on the X chromosome.³ It is a progressive disorder with severe mental and physical handicap and is one of the most common causes of mental retardation only affecting the girl child. It is characterized by apparently normal development till 6-18 months of age followed by a short period of developmental stagnation and then rapid regression in all domains. Some children also present

with autism like features, seizures and acquired microcephaly. Stereotypical hand movements are classically seen preceded by loss of purposeful hand use. These characteristics indicate abnormal development in the cortex. One of the leading hypothesis states that *MECP2* dysfunction caused due to mutation in the transcriptional repression domain and the Methyl CpG binding domain results in disruption of gene expression during development.⁴ Brain tissue is more susceptible to a difference in levels of *MECP2* expression. Till date more than 390 pathogenic variants of *MECP2* have been found out of which missense and nonsense variation account for the majority of the variants.⁴

It has also been shown that *MECP2* is involved in gene splicing and abnormalities in these functions could be a cause of the pathophysiology seen in Rett Syndrome.⁴ Awareness of such rare yet significant disorders are of paramount importance for effective and timely management of these children.

CASE REPORT

A 3.5 year old girl, 1st by birth order, born out of a non-consanguineous marriage, with a normal birth and an uncomplicated antenatal and postnatal period, presented with chief complaints of neuro regression, involuntary hand movements and difficulty walking with frequent falls since 2 years and seizures since 5 days.

She achieved all her milestones till the age of 8 months: i.e. standing with support by 8 months, speaking monosyllables by 6 months, adequate social interaction and making eye contact. After the age of 8 months her mother noticed developmental delay followed by regression with loss of eye contact and poor social interaction. She also had loss of purposeful hand use and involuntary hand movements including tapping her head and mouth with her hands accompanied by excessive, inconsolable crying. The child had difficulty while walking and she suffered from frequent falls. The child's mother noted normal cognition till 8 months followed by cognitive decline. The child was completely dependent on her parents for activities of daily living

She had severe global developmental delay (Global DQ: 16.6%) with progressive motor and cognitive regression. Gross motor developmental age was 1 year, fine motor: 8 months, social 4 months, language 5 months. The delay and regression were significantly more in language, social and cognitive domains compared to motor domains (Figure 1).

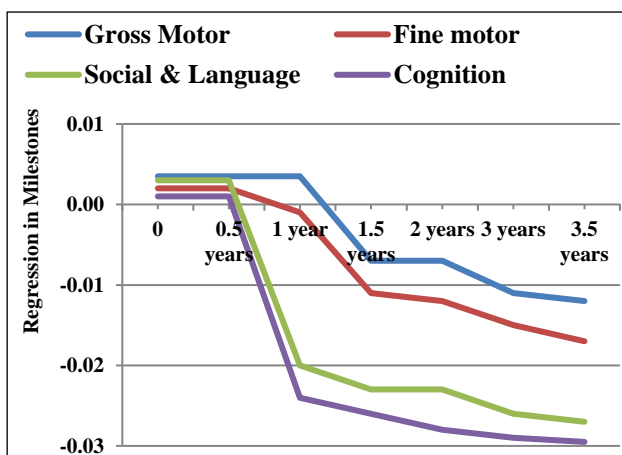


Figure 1: Differential developmental delay and regression showing greater regression in social, language and cognitive domains.

The child developed seizures 5 days ago which were 4-5 episodes per day, in the form of generalized stiffening of whole body with a staring look and impaired awareness lasting for 1 minute with post ictal drowsiness for 5 minutes. Seizures were well controlled with anti-epileptics.

On examination, the child was irritable and not interested in her surroundings. Her height was 96cm and weight was 13.5 kg, both normal for age (as per WHO standards). She had microcephaly with a head circumference of 43cm (< -3SD for age). Central nervous system examination revealed hypotonia and a power >3/5 in all 4 limbs with preserved superficial and deep reflexes. She had an ataxic gait, poor fine motor coordination and involuntary hand movements associated with incomprehensible vocalizations.

In view of a female child with neuroregression with loss of purposeful hand use with an ataxic gait and acquired microcephaly, a clinical diagnosis of Rett's Syndrome was made.

Genetic testing revealed a pathologic variant of the *MECP2* gene consistent with the diagnosis of Classic Rett Syndrome. MRI brain and EEG were normal. Treatment focused on genetic counselling for the parents and regular sensory integration, speech and occupational therapy. The child is on regular follow up and is compliant with the therapy and has shown a gradual improvement in gross motor skills.

DISCUSSIONS

Classic Rett syndrome is a progressive neurodevelopmental disorder primarily affecting girls. It is a rare syndrome, affecting 1 in 9000-10000 females.³ The syndrome presents in 4 stages. The patients usually have normal development till the age of 6 to 18 months after which there is developmental stagnation and delay for a short period of time (stage I), followed by rapid developmental regression in motor, language and social domains (stage II). This is followed by stage III which is a long period of stability. During the period of developmental regression stereotypical hand wringing movements are observed with loss of purposeful hand use. This is characteristic of Rett syndrome. Our patient however did not have the classic hand wringing movements but rather had hand tapping movements over the head and mouth.

During this period about 90% of the patients develop seizures.⁵ Seizures were well controlled in our patient but are intractable in *CDKL5* mutation variant of Rett Syndrome. The parents often complain of screaming fits and excessive inconsolable crying. Most girls also have growth failure with acquired microcephaly with 74% of the girls developing osteopenia before the age of 20.^{6,7}

Stage IV, also called the late motor deteriorating stage usually occurs after 10 years of age and includes scoliosis, muscle weakness and increased muscle tone with abnormal posturing of arms and legs. There may be improvement of eye gaze and decreased repetitive hand movements.⁸

Treatment usually focusses on adequate physical therapy and treatment of symptoms. Most patients of Rett syndrome typically survive till adulthood but the prevalence of sudden death is high.⁸ Death usually occurs due to T wave and QT interval abnormalities.⁹ Diagnosis is by genetic testing. MRI and EEG changes are not unique for Rett syndrome and thus are not diagnostic. Classic Rett syndrome is diagnosed by a pathogenic variant of the *MECP2* gene. Other *MECP2* related disorders include Variant Rett Syndrome and mild learning disabilities. It is found that genetic loss of the *MECP2* gene causes changes in the locus coeruleus leading to decreased level of norepinephrine in the cerebral cortex and hippocampus resulting in CNS dysfunction.¹⁰ A pathogenic variant of the *MECP2* gene is almost always lethal in males with the exception being those with 47XXY karyotype.¹¹ *MECP2* disorders are inherited in a simplex manner, as a de novo pathogenic variant. Very rarely can a *MECP2* variant can be inherited from a mother with favorable skewing of X chromosome inactivation, which leads to minimal signs in the mother, but she becomes a carrier leading to a 50% chance of her offspring inheriting it. Prenatal testing is available for those who are known to be at a risk if a pathogenic variant of the *MECP2* has been identified in the family. Prenatal diagnosis is also offered to couples who have had a child with a variant of *MECP2*. Rare instances of variants of Rett syndromes are seen with pathogenic mutations of *CDKL5* gene in which seizures predominate with signs appearing before that age of 6 months and the *FOXG1* gene causing congenital Rett syndrome.^{12,13}

CONCLUSION

Any young girl presenting with developmental regression more in the social and language domain, microcephaly and loss of purposeful hand use should be evaluated for Rett syndrome as an early diagnosis and prompt initiation of physical and speech therapy is imperative for a good quality of life.

ACKNOWLEDGEMENTS

Authors would like to thank Dr. Jayshree Mondkar, Dean of the institution for permitting to publish and Dr. Radha Ghildiyal, Head of Department of Pediatrics for her encouragement.

Funding: No funding sources

Conflict of interest: None declared

Ethical approval: Not required

REFERENCES

1. Rett A. On an unusual brain atrophy syndrome in hyperammonemia in childhood. *Wien Med Wochenschr*. 1966;116(37):723-6.

2. Hagberg B, Aicardi J, Dias K, Ramos O. A progressive syndrome of autism, dementia, ataxia, and loss of purposeful hand use in girls: Rett's syndrome: report of 35 cases. *Ann Neurol*. 1983;14(4):471-9.
3. Glaze DG. Neurophysiology of Rett syndrome. *J Child Neurol*. 2005 Sep;20(9):740-6.
4. Christodoulou J, Ho G. *MECP2*-Related Disorders. In: Adam MP, Ardinger HH, Pagon RA, JHL Bean, Stephens K, Amemiya A. *GeneReviews*®. Seattle:Seattle (WA): University of Washington; 1993-2019.
5. Steffenburg U, Hagberg G, Hagberg B. Epilepsy in a representative series of Rett syndrome. *Acta Paediatr*. 2001;90(1):34-9.
6. Motil KJ, Schultz RJ, Wong WW, Glaze DG. Increased energy expenditure associated with repetitive involuntary movement does not contribute to growth failure in girls with Rett syndrome. *J Pediatr*. 1998;132(2):228-33.
7. Leonard H, Thomson MR, Glasson EJ, Fyfe S, Leonard S, Bower C, et al. A population-based approach to the investigation of osteopenia in Rett syndrome. *Dev Med Child Neurol*. 1999;41(5):323-8.
8. Hagberg B. Clinical manifestations and stages of Rett syndrome. *Mental Retard Develop Disabilities Res Rev*. 2002;8(2):61-5.
9. Kerr AM, Julu PO. Recent insights into hyperventilation from the study of Rett syndrome. *Arch Dis Child*. 1999;80(4):384-7
10. Berridge CW, Waterhouse BD. The locus coeruleus-noradrenergic system: Modulation of behavioural state and state-dependent cognitive processes. *Brain Res Rev*. 2003;42(1):33-84.
11. Hoffbuhr K, Devaney JM, LaFleur B, Sirianni N, Scacheri C, Giron J, et al. *MECP2* mutations in children with and without the phenotype of Rett syndrome. *Neurology*. 2001;56(11):1486-95.
12. Weaving LS, Christodoulou J, Williamson SL, Friend KL, McKenzie OL, Archer H, et al. Mutations of *CDKL5* cause a severe neurodevelopmental disorder with infantile spasms and mental retardation. *Am J Hum Genet*. 2004;75(6):1079-3.
13. Ariani F, Hayek G, Rondinella D, Artuso R, Mencarelli MA, Spanhol-Rosseto A, et al. *FOXG1* is responsible for the congenital variant of Rett syndrome. *Am J Hum Genet*. 2008;83(1):89-93.

Cite this article as: Dagli S, Adhikari AT, Gajre M. Rett syndrome: a neurodevelopmental disorder. *Int J Contemp Pediatr* 2019;6:1757-9.