

Case Report

Meconium pseudocyst revisited

Bhavana Malhotra¹, Nishant Mittal^{2*}, Abhishek Jha³, N. K. Mittal⁴

¹Department of Pediatrics, Jawaharlal Nehru Medical College, Belgaum, Karnataka, India

²Department of Pediatrics, Medanta the Medicity Hospital, Gurugram, Haryana, India

³Consultant Radiologist, Jeevandeep Diagnostic Centre, Sonapat, Haryana, India

⁴Senior Consultant Pediatrician and Director, Mittal Nursing Home, Sonapat, Haryana, India

Received: 25 March 2019

Revised: 31 May 2019

Accepted: 10 June 2019

*Correspondence:

Dr. Nishant Mittal,

E-mail: nishumamc@gmail.com

Copyright: © the author(s), publisher and licensee Medip Academy. This is an open-access article distributed under the terms of the Creative Commons Attribution Non-Commercial License, which permits unrestricted non-commercial use, distribution, and reproduction in any medium, provided the original work is properly cited.

ABSTRACT

Meconium peritonitis is defined as a sterile chemical or foreign-body peritonitis that is caused by escape of meconium from the intestinal tract into the peritoneal cavity during the fetal or perinatal period. Although meconium peritonitis is indicative of intrauterine perforation of the intestine, it may occur as early as the 4th to 6th month of INTRA NATAL life and as late as several hours after birth. It can be classified into three pathological variations: fibro-adhesive; cystic and generalized. The cystic type has a meconium filled pseudocyst that may rupture in the peritoneal cavity. Intra-abdominal calcification is pathognomonic for the diagnosis. Here, author reported a classical case of meconium peritonitis with pseudocyst formation, which was treated successfully conservatively.

Keywords: Meconium pseudocyst, Peritonitis, Intrauterine perforation, Perforation

INTRODUCTION

Meconium peritonitis with pseudocyst formation is a rare entity and can be lethal. The estimated incidence is about 1 in 35,000 live births.^{1,2} Since, some cases occurring in utero may resolve or maybe clinically in apparent at birth the actual frequency may be higher.³⁻⁷ The etiology can be categorized as perforation with obstruction, including stenosis, atresia, volvulus, extrinsic congenital band, meconium ileus, and internal hernia, or perforation without obstruction, such as appendicitis, Meckel's diverticulum, vascular insufficiency and ruptured ulcer.⁸ Intra-abdominal calcification is recognized as a pathognomonic presentation either by X-ray or ultrasound.⁹ There is paucity of information regarding the natural history of meconium peritonitis. Therapy is empiric since some cases improve and may even resolve in utero. Most authors recommend expectant

management unless it is complicated. In the neonate with meconium peritonitis the perforation may either have sealed off completely in utero or may seal in the neonatal period or may require surgical repair.

Prior to labor the meconium is sterile, so the perforation does not translate into bacterial contamination. However, contamination can occur after delivery.⁹

Treatment consists of elimination of the gastrointestinal tract for continued leakage. The surgical indications are intestinal obstruction or persistent leakage of the meconium into the peritoneal cavity, which may result in progressive abdominal distension and subsequent respiratory distress or sepsis.¹⁰ The principles of the surgery are to treat the underlying pathology and restore intestinal continuity, with preservation of at least 50% of intestinal length. Previously the surgical mortality has

been high, at up to 60%. Despite improvements in antenatal diagnosis, neonatal intensive care and postoperative management, the overall mortality is still estimated to be 11%.

CASE REPORT

A 32 weeks gestation male baby, with birth weight of 1.45 kg, born to second para by normal vaginal delivery at a primary health centre presented to us. He developed groaning and tachycardia immediately after birth and hence was referred to NICU. Baby was received pulseless and in a sick state 5 hours after birth. Baby was resuscitated with normal saline bolus, inotropes (Dopamine, Dobutamine, epinephrine) CPAP and antibiotics (sepsis screen positive). For the initial 7 days the clinical condition was unstable. After 1 week, he shows signs and improvement and was weaned off oxygen and inotropes.

Physical examination at the time of presentation revealed a firm and mobile lump of size measuring approximately 20-30 mm just above the umbilicus to the left of midline in left paraumbilical region.

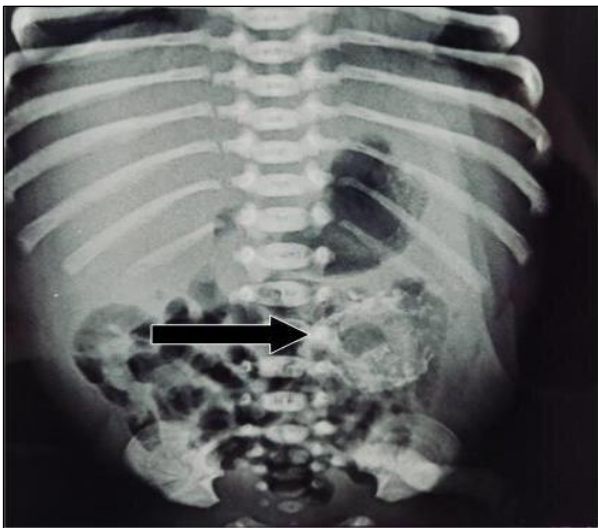


Figure 1: Plain supine abdominal radiograph calcified intra-abdominal lesion(black arrow) in left paraumbilical region.

Plain radiograph of the neonate in supine position showed a calcified lesion (Figure 1). Since baby was not tolerating feeds, contrast study was done to see the patency of bowel. The dye was noted to pass completely without any narrowing or obstruction (Figure 2). NEC was thought of, but radiological and laboratory findings were not supportive. Ultrasonographic study confirmed the possibility of a meconium pseudocyst, as there were calcifications and entrapment of air within the lesion. The lesion showed no obvious communication with gut loops (Figures 3 and 4).

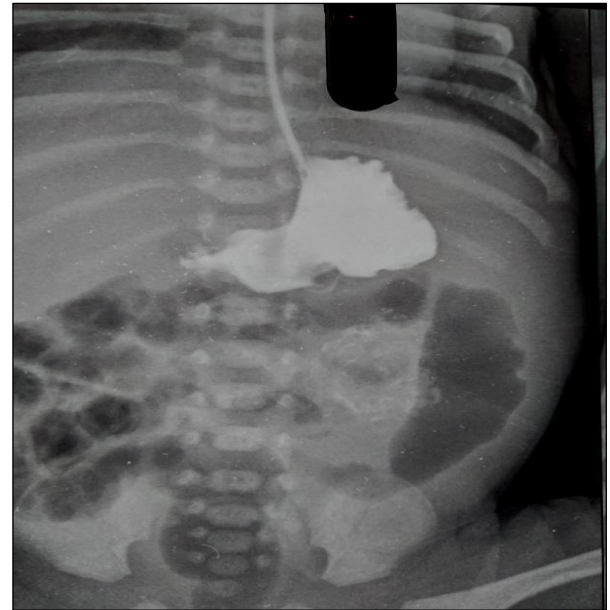


Figure 2: Upper GI contrast study normal passage of contrast into the small bowel through the infant feeding tube.

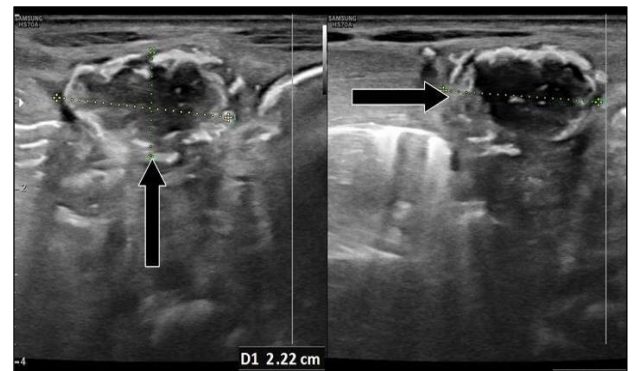


Figure 3: High Frequency transducer images of sonography calcified lesion with posterior acoustic shadowing, which is seen separate from the gut which is air filled.

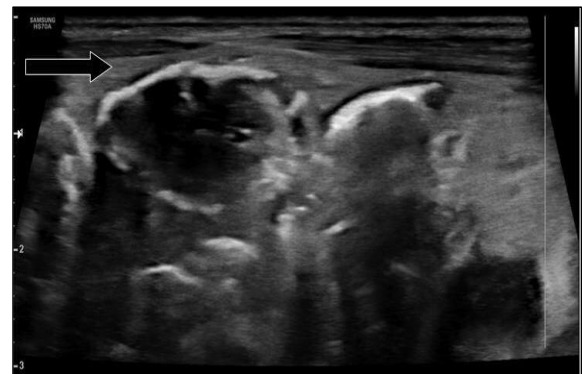


Figure 4: Another high frequency sonographic image calcified lesion with posterior acoustic shadowing.

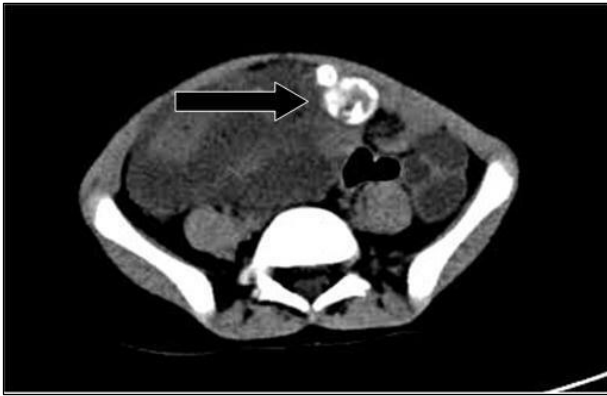

Figure 5: Small calcified lesion in the left para umbilical region seen in close relation to small bowel but separate from it. It is seen just beneath the abdominal wall.

Plain CT Abdomen reinforced the above findings (Figure 5). In our case, there was no clinical sign of peritonitis. Passage of meconium was not delayed, and no bilious vomiting or bilious aspirate was seen. There was no communication of cyst with bowel lumen. Though there was initial intolerance of feeds but once the baby started tolerating feeds after 8 days, feeding was advanced at a normal rate without any complications. Follow up ultrasound after one month showed shrinking of cyst.

DISCUSSION

Morgagni first described Meconium peritonitis in 1761 and more comprehensively by Simpson in 1838.¹¹ The clinical course ranges from spontaneous healing to rapid fatality, depending on the timing of perforation and if the perforation persists after birth. Postnatal surgical intervention to relieve the intestinal obstruction or close the perforation and restore the intestinal continuity is usually necessary.

Since the 1980s, antenatal diagnosis by maternal sonography has added to the diagnostic yield. Antenatal diagnosis of meconium peritonitis is believed to reduce the mortality rate from 50% to 11% and predict postnatal surgery in 50% of those with meconium pseudocyst. A fetal intraperitoneal cystic mass that shows high T1 and low T2 signals in prenatal magnetic resonance imaging is considered pathognomonic of meconium pseudocyst. In our case the findings of sonography, postnatal plain radiograph and ultrasonography, all suggested possibility of meconium pseudocyst with calcification. From the embryologic point of view, meconium formation begins about the 3rd month of gestation. Intestinal peristalsis begins about the 5th month of gestation and the meconium fills the entire intestine.

In western countries 15-40% of infants with diagnosis of meconium peritonitis are reported to have meconium ileus and cystic fibrosis. In particular, cystic fibrosis is considered non-existent in oriental people, except in a

few cases of gene mutation. Our case showed no clinical evidence of cystic fibrosis and hence not investigated for the same. In 1943, Agerty and associates were the first to record survival of a patient with meconium peritonitis treated surgically. Since then several reports of survival after surgery for meconium peritonitis have been published. However, there is no standardized operative procedure for meconium peritonitis. The purpose of surgery is to establish intestinal continuity and to preserve at least 50% of the intestinal length. Underlying pathologic processes should also be corrected.

In general, meconium peritonitis can be classified into three pathological variations: fibro-adhesive; cystic and generalized.¹² In the fibro-adhesive type, the perforation usually seals off before birth as a result of an intensive fibroblastic reaction. Subsequent obstruction is caused by adhesions. Surgery aims to achieve adhesiolysis and resection of the non-viable intestine, but dissection is usually difficult. In the cystic type, the perforation generally remains open. By opening the cyst and finding the perforation, the cause of the obstruction can be determined. Decortication must be done to dissect the cyst from the entrapped intestine. After an adequate length of intestine is freed, the non-viable or severely entrapped intestine can be resected, followed by bowel exteriorization. In the generalized type, the perforation occurs in the perinatal period and results in wide dissemination of meconium in the peritoneal cavity. In conclusion, the successful conservative management in our case was possible because of the cyst being fibro-adhesive in nature, and prompt radiological confirmation. No obvious bowel communication was another prognostically favourable factor.

Funding: No funding sources

Conflict of interest: None declared

Ethical approval: Not required

REFERENCES

1. Lorimer WS, Ellis DG. Meconium peritonitis. *Surg.* 1966;60:470-475.
2. Foster MA, Nyberg DA, Mahony BS, Mack LA, Marks WM, Raabe RD. Meconium peritonitis: Prenatal sonographic findings and their clinical significance. *Radiol.* 1987;165:661-5.
3. Zerhouni S, Mayer C, Skarsgard ED. Can we select fetuses with intra-abdominal calcification for delivery in neonatal surgical centres?. *J Pediatr Surg.* 2013;48:946-50.
4. Zangheri G, Andreani M, Ciriello E, Urban G, Incerti M, Vergani P. Fetal intra-abdominal calcifications from meconium peritonitis: sonographic predictors of postnatal surgery. *Prenat Diagn.* 2007;27:960-3.
5. Pelizzo G, Codrich D, Zennaro F, Dell'oste C, Maso G, D'Ottavio G, et al. Prenatal detection of the cystic form of meconium peritonitis: no issues for delayed post-natal surgery. *Pediatr Surg Int.*

- 2008;24:1061-5.
6. Saleh N, Geipel A, Ulrich G, Heep A, Heydweiller A, Bartmann P, et al. Prenatal diagnosis and postnatal management of meconium peritonitis. *J Perinat Med*. 2009;37: 535-8.
 7. Nam SH, Kim SC, Kim DY, Kim AR, Kim AS, Pi SY, et al. Experience with meconium peritonitis. *J Pediatr Surg*. 2007;42:1822-5.
 8. Uchida K, Koike Y, Matsushita K, Nagano Y, Hashimoto K, Otake K, et al. Meconium peritonitis: Prenatal diagnosis of a rare entity and postnatal management. *Intractable Rare Dis Res*. 2015;4:93-7.
 9. Chan KL, Tang MH, Tse HY, Tang RY, Tang PK. Meconium peritonitis: prenatal diagnosis, postnatal management and outcome. *Prenat Diagn*. 2005;25:676-82.
 10. Nam SH, Kim SC, Kim DY, Kim AR, Kim KS, Pi SY. Experience with meconium peritonitis. *J Pediatr Surg*. 2007;42(11):1822-5.
 11. Forouhar F. Meconium peritonitis. Pathology, evolution, and diagnosis. *Am J Clin Pathol*. 1982;78:208-13.
 12. Tibboel D, Gaillard JL, Molenaar JC. The Microscopic type of meconium peritonitis. *Z Kinderchir*. 1981;34(1):9-16.

Cite this article as: Malhotra B, Mittal N, Jha A, Mittal NK. Meconium pseudocyst revisited. *Int J Contemp Pediatr* 2019;6:1753-6.