

Case Report

Femoral hypoplasia-unusual facies syndrome: a rare clinical entity

Vinaya Lichade, Poonam Wade*, Prachi Gandhi, Shruti Saxena, Sushma Malik

Division of Neonatology, Department of Pediatrics, T. N. Medical College and B. Y. L. Ch. Nair Hospital, Mumbai, Maharashtra, India

Received: 11 October 2018

Accepted: 29 November 2018

***Correspondence:**

Dr. Poonam Wade,

E-mail: poonamwade@gmail.com

Copyright: © the author(s), publisher and licensee Medip Academy. This is an open-access article distributed under the terms of the Creative Commons Attribution Non-Commercial License, which permits unrestricted non-commercial use, distribution, and reproduction in any medium, provided the original work is properly cited.

ABSTRACT

Femoral hypoplasia-unusual facies syndrome (FH-UFS) is a disorder with multisystem involvement comprising predominantly of craniofacial dysmorphism with bilateral hypoplastic femurs. The exact etiology of this disorder is unknown, however maternal infections, drug and radiation exposure, oligohydramnios has been implicated. In affected children born to non-diabetic mothers, a genetic contribution is suspected; however, no chromosomal or gene mutations have been identified so far. The syndrome closely resembles with caudal dysplasia or syringomyelia which occur due to insufficient mesoderm in the caudal part of the embryo leading to lumbosacral defects, renal agenesis, and dysplastic lower limbs, however they lack craniofacial dysmorphism. The pathogenesis of FH-UFS involves poor development of subtrochanteric portion of the femoral cartilage. This results in shortening of proximal femur. Maternal diabetes justifies the teratogenic effect of hyperglycemia and ketones on fetus leading to dysmorphic features in fetus. Here, we are reporting a female neonate with characteristic phenotypic features of FH-UFS. She had cleft lip and palate, low set ears, retrognathia and micrognathia, dolichocephaly with bilateral femoral hypoplasia with talipes deformity of both feet. Karyotype was normal (46XX). Renal and cranial ultrasounds were normal. The 2D Echo revealed small 0.3mm PDA.

Keywords: Caudal dysplasia syndrome, Craniofacial dysmorphism, Femoral hypoplasia, Sirenomelia

INTRODUCTION

Femoral hypoplasia- unusual facies syndrome (FH-UFS) is a rare disorder which was first described by Daentl et al in 1975 and is characterized by femoral hypoplasia and cranio-facial dysmorphism and it is more common in females.¹⁻³ Other systemic anomalies like cardio-vascular, Genito- urinary may also be associated. It has variable expressivity, with majority being sporadic and a few cases of autosomal dominant inheritance have been reported.⁴ Specific etiology of this syndrome is unknown but association with maternal diabetes, drug exposure, viral infection, radiation, focal ischemia and oligohydramnios have been reported.^{4,5} FH-UFS closely resembles caudal dysplasia syndrome or sirenomelia

which is characterized by lumbosacral defects, lower limb dysplasia, renal agenesis but do not have any facial anomalies.

Caudal dysplasia syndrome and sirenomelia have strong association with maternal diabetes. Children with FH-UFS have short stature due to short femurs. Affected patients frequently have hypoplastic fibulae and acetabular, as well as hypoplastic femurs.⁶ Other vertebral anomalies like hemivertebrae, synostosis, scoliosis spina bifida occulta are seen up to 35% of patients.⁶ We are reporting a female neonate with cranio-facial dysmorphism of FH-UFS which included cleft palate, cleft lip, low set ears, retrognathia, prominent occiput, dolichocephaly, and bilateral femoral hypoplasia.

CASE REPORT

A full-term, low birth weight female neonate (1.96 kg) was born of non-consanguineous marriage to a 28-year-old primiparous mother with gestation of 37 weeks by caesarian section. There was no history of maternal diabetes mellitus, oligohydramnios, drug intake or radiation exposure during pregnancy. Antenatal ultrasound done at 20 weeks of gestation, revealed a femoral length of 15.3 corresponding to 14-16 weeks of gestation, and rest of the anthropometric parameters corresponded 18 to 20 weeks. Repeat ultrasound in third trimester, at 35 weeks of gestation suggested femoral and mandibular hypoplasia, with femoral length of 26 mm corresponding to 18 weeks of gestation and other fetal anthropometric parameters were gestation appropriate.

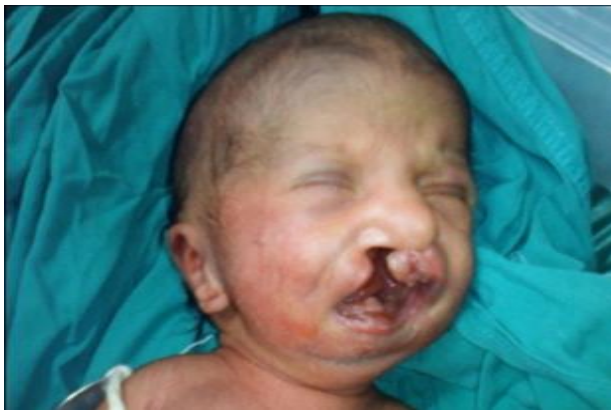

Figure 1: Phenotypic features of the baby with FH-UFS showing cleft lip, cleft palate and low set ears.

At birth, baby cried immediately, was active, eutermic with HR-140/min regular, RR-46/min regular. The head circumference was 34 cm and length were 36.5 cm. On examination dysmorphic facies (Figure 1) were noted which included cleft palate and cleft lip, low set ears, retrognathia prominent occiput and dolichocephaly with normal upper limbs. Lower limbs showed bilateral short femur with flexion and adduction deformity (Figure 2).

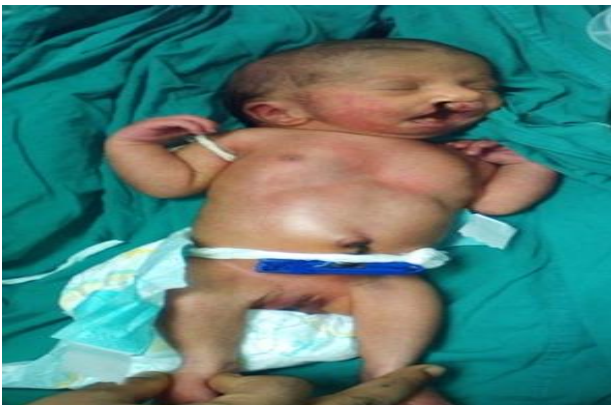

Figure 2: Phenotypic features of the baby with FH-UFS showing facial dysmorphism, normal upper limbs and hypoplastic femurs.

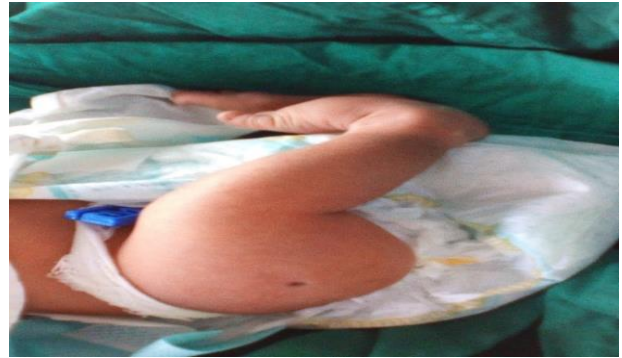

Figure 3: Thigh pit and talipes equines deformity of feet.

On lateral aspect of both thighs' pits were present (Figure 3). Spine and genitalia were normal. Cardiorespiratory and central nervous system examination were normal. Radiographic imaging of lower limbs (Figure 4 and 5) showed hypoplastic femurs. Renal and cranial ultrasound were normal.

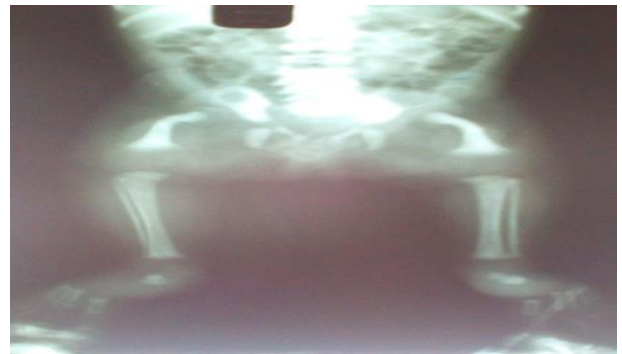


Figure 4: X ray lower limbs showing bilateral hypoplastic femurs.

The 2D Echo revealed small 0.3mm PDA. Chromosome analysis suggested a normal female 46 XX Karyotype. In view of the above findings a diagnosis Femoral hypoplasia- unusual facies syndrome (FH-UFS) was made. Patient had an uneventful stay at the hospital and was discharged with a plan to do limb lengthening surgery later.

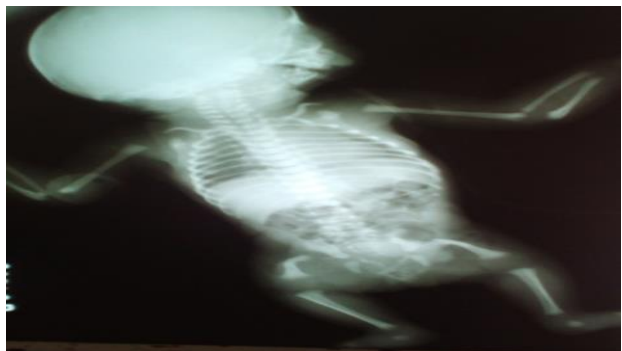


Figure 5: X ray Lower image showing bilateral hypoplastic femurs and normal upper limbs.

DISCUSSION

Femoral Hypoplasia-Unusual facies syndrome is characterized by bilateral femoral hypoplasia, facial dysmorphism like cleft palate, cleft lip, micrognathia, long philtrum, thin upper lip with short broad tipped nose, low set ears and variable involvement of fibula and tibia, club foot.⁷ Pelvic abnormalities include hypoplastic acetabulae and dysplastic sacrum. Absence of the femur is a rare finding in FH-UFS.⁸ Visceral abnormalities like polysplenia, a single pelvic or inferiorly placed kidney(s), anorectal agenesis and septate urinary bladder are reported.⁹ Other anomalies like as ventricular septal defect with valvular and infundibular pulmonic stenosis, pilonidal sinus, agenesis of labia majora were also seen.^{10,11} The severity and clinical expression of this entity appears to be variable. Vertebral abnormalities like scoliosis, hemivertebrae, synostosis, spina bifida occulta, mal-segmentation of sacrum have been documented in up to 35% of patients with this syndrome.¹² The etiology is unknown but association with maternal diabetes is remarkable.⁷ Maternal diabetes justifies the teratogenic effect of hyperglycemia and ketones on fetus leading to dysmorphic features in fetus.¹ The pathogenesis of FH-UFS involves poor development of subtrochanteric portion of the femoral cartilage. This results in shortening of proximal femur. Infants born to maternal diabetes are known to have neural tube defects, caudal regression, femoral hypoplasia, cardiac and renal anomalies however craniofacial anomalies are rare in infants of diabetic mothers. Hereditary nature of syndrome with autosomal dominance inheritance is also suggested in few instances. Antenatal ultrasound can diagnose femoral growth arrest as early as 13 weeks of gestation.⁴ In our patient antenatal ultrasound at 18 weeks of gestation showed femoral and mandibular hypoplasia. Subtrochanteric portion of the femoral cartilage is poorly developed resulting in proximal segment being shorter than normal femur.¹³ Other conditions which closely resembles to FH-UFS are caudal dysgenesis or sironemelia.^{1,12,14} This condition is characterized by urogenital and lower limb malformations, but craniofacial anomalies are always absent. Our patient had characteristic facial defects like cleft lip and palate, retrognathia and low set ears which differentiated it from sironemelia. Therapy involves multidisciplinary approach with limb lengthening surgery and surgical corrections of various anomalies like cleft lip & palate. Prognosis of patients with FH-UFS depends on severity of associated congenital anomalies.

CONCLUSION

Femoral hypoplasia-unusual facies syndrome is very rare clinical entity. Prenatal sonography is an important diagnosis tool for the detection of femoral hypoplasia. A multidisciplinary health care team involving pediatrician, orthopaedic surgeon, plastic surgeon, cardiologist, neurologist genetics and craniofacial surgeon is required

for management of child with femoral hypoplasia-unusual facies syndrome.

Funding: No funding sources

Conflict of interest: None declared

Ethical approval: Not Required

REFERENCES

1. Palit S, Ghosh S, Basu M, Mondal AK, Gayan S, Sengupta A. Femoral hypoplasia-unusual facies syndrome with atypical features-a rare case report. *J Anat Soc Ind.* 2004;53(1):22-4.
2. Daentl DL, Smith DW, Scott CI, Hall BD, Gooding CA. Femoral hypoplasia-unusual facies syndrome. *J Pediatr.* 1975;86:107-11.
3. Johnson JP, Carey JC, Gooch WM, Petersen J, Beattie JF. Femoral hypoplasia-unusual facies syndrome in infants of diabetic mothers. *J Pediatr.* 1983;102:866-72.
4. Paladini D, Maruotti GM, Sglavo G, Penner I, Leone F, D'Armiento MR, et al. Diagnosis of femoral hypoplasia-unusual facies syndrome in the fetus. *Ultrasound Obstet Gynecol.* 2007;30(3):354-8.
5. Burn J, Winter RM, Baraitser M, Hall CM, Fixsen J. The femoral hypoplasia- unusual facies syndrome. *J Med Genet.* 1984;21(5):331-40.
6. Gorlin RJ, Cohen Jr MM, Hennekam RC. *Syndromes of the head and neck.* Oxford University Press; 2001.
7. Rekiq M, Sghir M, Ksibi I, Said W, Saida J, Kessomtini W. Femoral hypoplasia-unusual facies syndrome: A case report and literature review. *J Med Res.* 2016;2:141-3.
8. Trabelsi M, Monastiri K, Hammami A, Touzi C, Ben Hariz M, Gharbi HA, et al. Femoral hypoplasia with facial dysmorphism: about a new observation. *Ann Pediatr.* 1989;36(10):693-6.
9. DePalma L, Duray PH, Popeo VR. Femoral hypoplasia-unusual facies syndrome: autopsy findings in an unusual case. *Pediatr Pathol.* 1986;5(1):1-8.
10. Goldberg RB, Fish B, Cohen MM Jr, Shprintzen RJ. Bilateral femoral dysgenesis syndrome: a case report. *Cleft Palate J.* 1978;15(4):386-9.
11. Jones KL, Jones MC, del Campo M. *Smith's Recognizable Patterns of Human Malformation.* 7th ed. Philadelphia: Saunders; 2013:350-352.
12. Squiers MT, Rideout M, Laub Jr D. Femoral-facial syndrome. *Eplasty.* 2014;14.
13. Garcia VD, Aragon VCR, Trevino AMG, Rivera SG. Femoral hypoplasia- unusual facies syndrome: A case report. *Chil Pediatr.* 2016;87(1):59-62.
14. Shenoy SR, Mondal D, Upadhyay MR, Gupta BK, Mahar J. Femoral hypoplasia with unusual facies syndrome. *J Clin Diagn Res.* 2017;11(8):SD03-04.

Cite this article as: Lichade V, Wade P, Gandhi P, Saxena S, Malik S. Femoral hypoplasia-unusual facies syndrome: a rare clinical entity. *Int J Contemp Pediatr* 2019;6:227-9.