

## Case Report

# Vascular ring, an uncommon presentation of BRUE in newborns

Sneha Singh Dhruw\*, Abhishek Saini, Sourabh Singh

Department of Neonatology, Babylon Children's Hospital, Jaipur, Rajasthan, India

**Received:** 16 August 2018

**Accepted:** 17 September 2018

**\*Correspondence:**

Dr. Sneha Singh Dhruw,

E-mail: [snehadhruw@gmail.com](mailto:snehadhruw@gmail.com)

**Copyright:** © the author(s), publisher and licensee Medip Academy. This is an open-access article distributed under the terms of the Creative Commons Attribution Non-Commercial License, which permits unrestricted non-commercial use, distribution, and reproduction in any medium, provided the original work is properly cited.

### ABSTRACT

Vascular rings are a group of anomalies caused by abnormal embryologic development of the branchial arch system. They can lead to variable degrees of respiratory problems or feeding difficulties by forming a complete or partial ring compressing the trachea, the bronchi, and the oesophagus. Vascular rings not being so common, a missed diagnosis is much more common. Hence a high degree of suspicion along with appropriate imaging study is required to make a diagnosis. This case report describes an uncommon acute presentation of a vascular ring in newborn as a brief resolved unexplained event (BRUE).

**Keywords:** BRUE, Newborn, Vascular ring

## INTRODUCTION

Vascular rings are recognized as uncommon but not rare cardiovascular malformations. They are group of anomalies caused by abnormal embryologic development of the branchial arch system. Vascular ring is unusual congenital condition in which the anomalous configuration of the arch, associated vessels or both surrounds the trachea and oesophagus forming a complete or incomplete ring around them.<sup>1</sup> It accounts for less than 1% of all congenital heart problems. The condition occurs as often in males as females. Some infants with vascular ring may also have another congenital heart problem. The first report named "vascular ring" was published by Gross in the *New England Journal of Medicine* in 1945.

These anomalies are characterized by symptoms depending on compression of the trachea, oesophagus or both. The symptoms seen with vascular rings can be quite varied. They may occasionally be noted in the newborn, but more often are recognized later. A high index of

suspicion is required for early diagnosis. This case report describes an uncommon acute presentation of a vascular ring in newborn as brief resolved unexplained event.

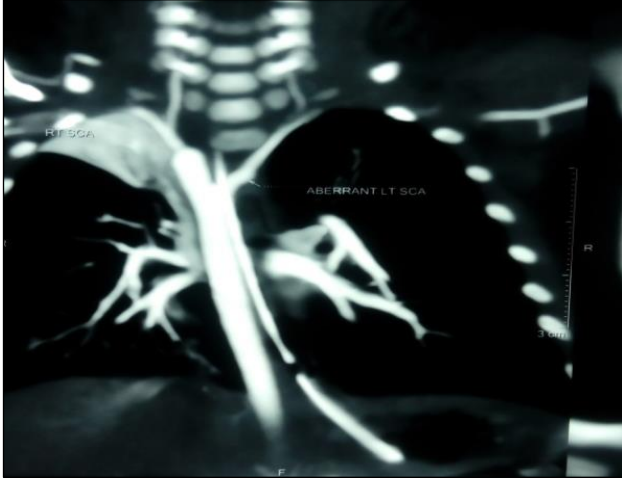
## CASE REPORT

We report a case of 44-day old twin I, preterm (28 weeks)/ male/birth weight 1.228 kg/ diamniotic diachronic twin spontaneous vaginal delivery born to 25-year-old G2A1 mother, out of non- consanguineous marriage. G1 was spontaneous miscarriage at 8 weeks.

Present pregnancy was IUI conception with h/o PIH, GDM and PROM and has received one dose of antenatal steroid before delivery. Antenatal scans were normal. On day 3 baby developed abdominal distension, feed intolerance. Septic screen was positive, started on antibiotics required ventilator support for 2 days along with inotropic support. Blood culture was negative. Gradually baby reached full feed anti reflux medication was started in view of suspected reflux and baby was shifted to ward. On day 36 baby had an episode of brief

resolved unexplained event requiring bag and mask ventilation.

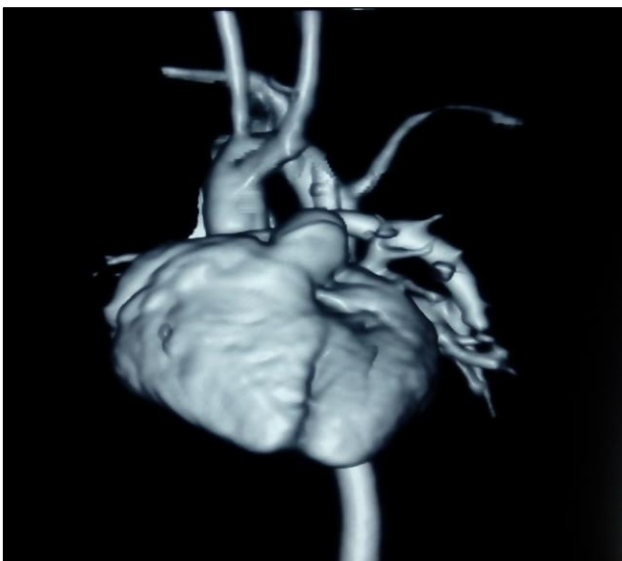
Baby was ventilated and started on antibiotics as septic screen was positive, blood culture and CSF analysis were normal excluding sepsis. Metabolic work up was normal.



**Figure 1: CT angiography showing right aortic arch and aberrant left subclavian artery.**

Chest x ray was done which showed right upper lobe collapse repeat x-ray after 3 days was normal. In view of oxygen dependency 2D Echo was done which was showing right aortic arch and was advised for CT angiography after stabilisation by cardiologist.

Baby was started on tube feeding gradually increased to full feed and CT angiography was done which showed right descending aorta with aberrant left subclavian artery figure 1 and figure 2, a diagnosis of vascular ring was made which was causing slight compression of the oesophagus and trachea.



**Figure 2: 3 dimensional CT of heart.**

An upper GI contrast swallow was done to rule out oesophageal obstruction. Case discussed with cardiothoracic surgeon and advised for conservative management till appropriate weight gain. Anti-reflux medication was started and gradually baby shifted to palladia feed, which baby tolerated well without vomiting, choking, apnea or respiratory distress.

Baby was discharged on life day 63 and weight 1.771 kg with maternal CPR instruction in case further episodes of apnea and cyanosis occur at home. Parents counselled regarding regular follow up and need for surgery in case of persistence of symptomatology.

## DISCUSSION

BRUE is defined as an event observed in infants younger than 1 year when an observer reports a sudden, brief (less than a minute), but then resolved episode of at least one of these: cyanosis or pale complexion; absent, decreased, or irregular breathing; marked change in muscle tone (hyper- or hypotonia); or altered responsiveness.<sup>2</sup>

The causes of BRUEs can be gastrointestinal (GI) (50%), neurological (30%), respiratory (20%), cardiovascular (5%), metabolic and endocrine (2-5%), and septicemia.<sup>3-5</sup> While rare, congenital anomalies such as vascular rings must be considered in an apparent well neonate who presents with an BRUE when other causes have been excluded.

Vascular rings are characterized by an anomalous branching pattern of the vessels originating from the aortic arches, abnormal positioning of the aortic arch itself, interrupted or supernumerary arches, or anomalous origin of the pulmonary artery from the contra lateral pulmonary artery or ascending aorta.<sup>6</sup> These anomalies may cause compression of the trachea, oesophagus or both.

These anomalies were classified by the society of thoracic surgeons International Congenital Heart Surgery Nomenclature and Database Committee into 2 main types.<sup>7</sup>

Complete Rings that include - the double aortic arch and right aortic arch with aberrant left subclavian artery. Incomplete ring: Pulmonary artery sling, Innominate artery compression syndrome, Left arch/aberrant right subclavian artery.

A double aortic arch result when both the right and left embryonic arches persist. They arise from the ascending aorta, pass around on both sides of the oesophagus and trachea, then join at the posterior aspect to form the descending aorta. This arrangement creates a ring around the oesophagus and trachea.

A right aortic arch with aberrant left subclavian artery occurs as a result of regression in the aortic arch segment

between the left common carotid and subclavian segments. This leaves the left subclavian arising as the last branch off the ascending aortic artery behind the oesophagus. Typically, the oesophagus and trachea are encircled and compressed by the ascending aorta and ligamentum arteriosus that arises just distal and adjacent to the left subclavian artery.

Vascular ring has varied clinical feature ranging from either being asymptomatic or more frequently may present with respiratory and/or gastrointestinal symptoms that depend on the degree of tightness of the ring and on subsequent tracheoesophageal compression to uncommon presentation of BRUE.<sup>8</sup>

Airway symptoms such as inspiratory stridor and wheezing are found more commonly when the trachea is compressed in a double aortic arch, while gastrointestinal symptoms such as dysphagia, reflux, and choking episodes are seen when the oesophagus is compressed posteriorly.<sup>9</sup>

Definitive diagnosis of vascular ring is made by Cross-sectional imaging with magnetic resonance angiography (MRA) or computed tomography angiography (CTA) of the chest.<sup>10</sup> Generally a clue is easily drawn from abnormalities found on chest X-ray, echocardiography, bronchoscopy, gastric emptying studies, or fluoroscopic studies such as a modified barium swallow or upper gastrointestinal series. In our case echocardiography showed a right aortic arch thus indicating further evaluation.

Surgical division of a vascular ring is indicated in all symptomatic patients such as-recurrent aspiration pneumonia, apneic episodes, apparent- life threatening events, bronchopulmonary dysplasia, severe vomiting, growth failure, esophagitis and oesophageal stricture. Individuals who have no symptoms from a vascular ring may not require surgical intervention.

## CONCLUSION

Vascular rings are rare, and diagnosis can be difficult hence a high index of suspicion is required, and clues have to be drawn from preliminary investigations such as chest x-ray, echocardiography and highlights the importance of CT with contrast to establish the diagnosis.

*Funding: No funding sources*

*Conflict of interest: None declared*

*Ethical approval: Not required*

## REFERENCES

1. Backer CL, Mongé MC, Popescu AR, Eltayeb OM, Rastatter JC, Rigsby CK. Vascular rings. *Semin Pediatr Surg.* 2016(3):165-75.
2. Tieder JS, Bonkowsky JL, Etzel RA. Brief resolved unexplained events (formerly apparent life-threatening events) and evaluation of lower-risk infants. *Pediatrics.* 2016;137(5):e20160590.
3. Kahn A. Recommended clinical evaluation of infants with an apparent life-threatening event. Consensus document of the European Society for the Study and Prevention of Infant Death, 2003. *Eur J Pediatr.* 2004;163:108-15.
4. Hall KL, Zalman B. Evaluation and management of apparent life-threatening events in children. *Am Fam Physician.* 2005;71:2301-8.
5. Shah S, Shariieff GQ. An update on the approach to apparent life-threatening events. *Curr Opin Pediatr.* 2007;19:288-94.
6. Song B, Xiao-feng L, Cai-xia L. Surgical treatment for vascular anomalies and tracheoesophageal compression. *Chin Med J.* 2012;125(8):1504-7.
7. Alsenaidi K, Gurofsky R, Karamlou T, Williams WG, McCrindle BW. Management and outcomes of double aortic arch in 81 patients. *Pediatrics.* 2006;118(5):e1336-41.
8. Osborne C, Blatt A, Bottar A. Vascular Ring: an uncommon presentation of BRUE and feeding intolerance in infancy. *J Hospital Med.* 2014;9(2).
9. Alsenaidi K, Gurofsky R, Karamlou T, Williams WG, McCrindle BW. Management and outcomes of double aortic arch in 81 patients. *Pediatrics.* 2006;118(5):e1336-41.
10. Etesami M, Ashwath R, Kanne J, Gilkeson RC, Rajiah P. Computed tomography in the evaluation of vascular rings and slings. *Insights into imaging.* 2014;5(4):507-21.

**Cite this article as:** Dhruw SS, Saini A, Singh S. Vascular ring, an uncommon presentation of BRUE in newborns. *Int J Contemp Pediatr* 2018;5:2341-3.