

Case Report

Intentional tremors: a rare complication of enteric fever in a child

Neetu Sharma*, Avadhesh Verma

Department of Pediatrics, Gajra Raja Medical College, Gwalior, Madhya Pradesh, India

Received: 28 May 2018

Accepted: 26 June 2018

*Correspondence:

Dr. Neetu Sharma,

E-mail: drneetuagarwal@gmail.com

Copyright: © the author(s), publisher and licensee Medip Academy. This is an open-access article distributed under the terms of the Creative Commons Attribution Non-Commercial License, which permits unrestricted non-commercial use, distribution, and reproduction in any medium, provided the original work is properly cited.

ABSTRACT

Enteric fever is a common infectious disease of the tropical world. Characteristic presenting features include fever, relative bradycardia, diarrhea or constipation and abdominal pain. Complications like clinically significant jaundice, hepatitis, splenic abscess, neurological complications relatively uncommon. However intentional tremors associated with enteric fever never have been reported. Here, we report a 14-year-old boy with enteric fever who presented with acute hepatitis, splenic abscess, acute cerebellar ataxia and intentional tremors. Following treatment with appropriate antibiotics, the patient showed complete recovery over the next 2 weeks.

Keywords: Enteric fever, Intentional tremors, Splenic abscess

INTRODUCTION

Enteric fever is caused by salmonella group organisms. It is a common infectious disease of the tropical world, with about 80% of cases occurring in Asian countries.¹ Fever, anorexia, headache are common symptoms of the disease. Abdominal pain, diarrhea, constipation and myalgia are other known symptoms.

Although altered liver function found in many patients with enteric fever, clinically significant hepatitis, jaundice, cholecystitis is relatively rare and may be associated with higher rate of adverse outcome. Intestinal hemorrhage (<1%) and perforation (0.5-1%) are infrequent among children. Rare complication includes toxic myocarditis (1-5%). Neurologic complications (3-35%) are also relatively uncommon among children; they include delirium, psychosis, increased intra cranial pressure, acute cerebellar ataxia, chora, deafness and Guillain-barre syndrome, however intentional tremors associated with enteric fever never have been reported.² Complications related to pulmonary system, bones and joint, genitourinary system, soft tissue infections,

hemorrhagic symptom also have been reported.³ In the literature isolated cerebellar ataxia (out of central nervous system related complications) has been reported in only a few case report.^{4,5} Here, we report a case of enteric fever who presented with complications like Acute hepatitis, splenic abscess, acute cerebellar ataxia and intentional tremors.

CASE REPORT

A 14 years old boy admitted to our hospital with a complaint of fever, pain abdomen, jaundice for 20 days before admission. After 5 days of hospital stay child had features of acute cerebellar ataxia and intentional tremor.

On his physical examination he had fever, vital signs, pulse rate, BP were normal. He had tenderness in left hypochondrium and right hypochondrium with bilateral cerebella sign in the form of ataxia, bilateral finger- nose incoordination, heel-knee incoordination and intentional tremors. The deep tendon reflexes were normal and plantar were flexor. Cranial nerve was intact and there were no signs of meningeal irritation. The remainder of

the physical and neurological examination was unremarkable. Following observations were made on laboratory examinations (on day of admission).

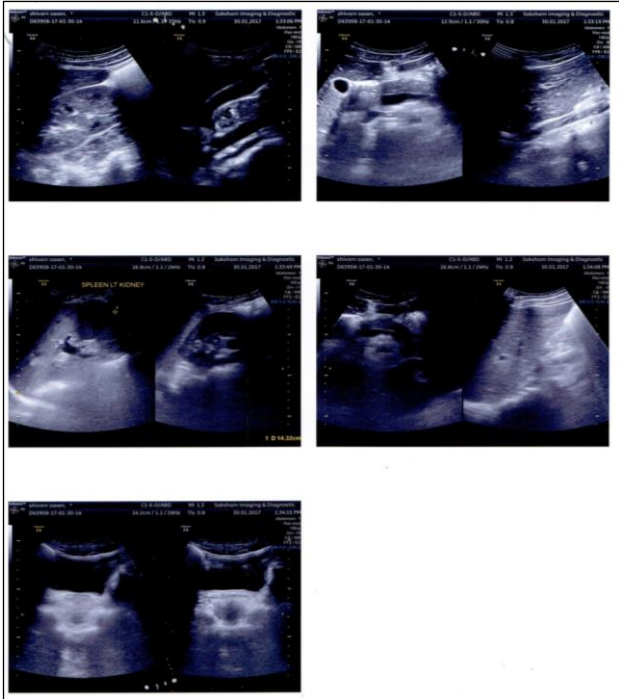


Figure 1: USG abdomen shows hypoechoic area of approx. volume 20 cc seen in inferior pole of spleen s/o splenic parenchyma.

Neuroimaging (CECT) done was found normal. USG abdomen study showed splenic abscess with mild hepatomegaly (enclosed).

Table 1: Complete blood count.

s.no	Observed value
Hemoglobin (Hb)	5.4 g/dL
Total leucocyte counts (TLC)	4800/mm ³
Differential leucocyte counts (DLC)	N52%, L44%, M02%, E02%
Platelet counts	1.5 lacs/mm ³

Table 2: Renal function test/liver function test.

	Observed value
Urea	38 mg%
Creatinine	0.64%
Total serum bilirubin (TSB)	0.95 mg% (direct fraction 0.46 mg%)
SGOT	156 IU/L
SGPT	70 IU/L
Alkaline phosphatase	151 IU/L
Total serum proteins	5.1 mg%
Serum albumin	2.8 mg%

Urine routine microscopy: Within normal limit; Urine culture sensitivity: Sterile; Blood culture sensitivity: Sterile

Table 3: Serum widal.

Serum widal	On 21/01/17 (on day of admission)	On 30/01/17	On 07/02/17	On 14/02/17 (on 25 th day of hospital stay)
O	1:80	1:60	1:80	1:120
H	1:80	1:60	-	1:120
AH	-	-	-	1:30
BH	-	-	-	-

Neuroimaging/CECT Brain was done and found normal while USG abdomen was suggestive of hepatomegaly and splenic abscess. The diagnosis of enteric fever complicated by hepatitis, splenic abscess, cerebellitis was made on the basis of clinical finding and laboratory studies. The patient was treated with intravenous ciprofloxacin (20 mg/kg/d) for 14 days twice a day. At the follow up patient showed complete neurological recovery.

DISCUSSION

Hepatobiliary, splenic, central nervous system involvement is not uncommon in patients with enteric fever. They have wide spectrum of presentation like cholecystitis, hepatitis, hepatic abscess, splenic abscess, peritonitis, paralytic ileus, encephalopathy, cerebral oedema, subdural empyema, cerebral abscess, meningitis, ventriculitis, transient parkinsonism, motor neuron disorders, ataxia, seizures, Guillain-Baire syndrome, psychosis.³ In various studies neurological complications acute cerebellar ataxia has been reported earlier with 2 weeks of illness.⁴ But in the present case developed 4 weeks of illness. Exact pathogenesis of these complication is unknown. Taxemia, pathogen itself directly invade reticuloendothelial septum in spleen and para or post infectious demyelinating process has been postulated as the mechanism for acute cerebellitis.^{6,7} Management of enteric fever these complications require only appropriate antibiotics.

However, 2 studies recommended use of intravenous high dose of dexamethasone with antibiotics.^{8,9} We use intravenous ciprofloxacin for 14 days and high dose intravenous dexamethasone only for 2 days and his symptoms recovered successfully. This case highlights the fact that complications always looked for any children we are suspecting enteric fever or child presenting with fever in enteric fever endemic region like in India.

Funding: No funding sources

Conflict of interest: None declared

Ethical approval: Not required

REFERENCES

1. Park K. Typhoid fever. In: Parks textbook of preventive and social medicine. 19th Ed. Jabalpur, India, Banaridas Bhanot; 2007:195-198.

2. Huang NDB, Dupont HL. Problem pathogens: extra intestinal complications of salmonella enterica typhi infection, *Lancet Infect Dis*. 2005;5:341-8.
3. Kliegman, Stanton, St Geme, Schor. In: *Nelson Textbook of Pediatrics*. First south asia edition. Elsevier; 2016:1391.
4. Kalra OP, Agarwal NK, Agrawal S. Acute reversible cerebellar ataxia in typhoid fever. *J Indian Acad Clin Med*. 2002;3:96-7.
5. Thapa R, Banerjee P, Akhtar N, Jain TS. Transient dysautonomia and cerebellitis in childhood enteric fever. *J Child Neurol*. 2008;23:1081-2.
6. Dewan P, Pooniya V, Kaushik JS, Gomber S, Singhal S. Isolated cerebellar ataxia: an early neurological complication of enteric fever. *Ann Trop Paediatr*. 2009;29:217-9.
7. Scragg J, Rubidge C, Wallace HL. Typhoid fever in African and Indian children in Durban. *Arch Dis Child*. 1969;44:18-28.
8. Girgis NI, Fand Z, Sultan Y, Hibb RG. Use of dexamethasone in treatment of enteric fever complicated by cerebellar involvement. *Trans Soc Trop Med Hyg*. 1993;87:690-1.
9. Kavy JK, Hwang YM, Le MC, Song JH, Lee YS. Two cases of suspected typhoid encephalitis treated with high dose dexamethasone. *J Korean Neurol Assoc*. 1993;11:229-34.

Cite this article as: Sharma N, Verma A. Intentional tremors: a rare complication of enteric fever in a child. *Int J Contemp Pediatr* 2018;5:2029-31.