

Case Report

Gingival enlargement in 10 years old: a case report

Nilofar B. Attar^{1*}, Rajesh P. Gaikwad¹, Shraddha C. Jugade²,
Akshaya B. Banodkar¹, Gulnar D. Sethna¹

¹Department of Periodontology, ²Department of Oral Pathology, Government Dental College and Hospital, Mumbai, Maharashtra, India

Received: 02 November 2016

Revised: 03 November 2016

Accepted: 30 November 2016

***Correspondence:**

Dr. Nilofar B. Attar,

E-mail: nilo_attar@yahoo.com

Copyright: © the author(s), publisher and licensee Medip Academy. This is an open-access article distributed under the terms of the Creative Commons Attribution Non-Commercial License, which permits unrestricted non-commercial use, distribution, and reproduction in any medium, provided the original work is properly cited.

ABSTRACT

Generalized gingival enlargement in children interferes with the eruption of teeth. It may lead to difficulty in mastication and phonetics. Very few cases of generalized gingival enlargement associated with eruption of teeth in as young as 10 year old child had been reported in literature. The pathophysiology for occurrence of gingival enlargement with eruption of teeth is not clearly established. Generalized gingival enlargement was present in a 10 year old girl since the eruption of permanent teeth. The gingival biopsy was done followed by full mouth gingivectomy of maxillary and mandibular arch. The histopathological picture showed hyperplastic tissue. The treatment of gingival enlargement at early stage leads to exposure of teeth. The treatment resulted in improvement in mastication and establishing the aesthetic smile of the 10 year old child. This case represents systematic evaluation of gingival enlargement followed by gingival biopsy and gingivectomy. The management of gingival enlargement in children is challenging and requires systematic follow-up.

Keywords: Gingival enlargement, 10 year, Gingivectomy

INTRODUCTION

Gingival enlargement when present can cause a worrisome situation, as there is major influence of systemic condition on its occurrence. Its management involves close association with the physician. The handling of such cases requires detail knowledge of symptoms and syndromes associated with gingival enlargement. The patient should be systemically evaluated by the specialists in the field of medicine, radiology, dermatology, hematology and orthopedics. The presence of gingival enlargement may or may not be associated with syndromes. Generalized gingival enlargement in children without association of syndromes had been reported in the literature. The development of gingival enlargement raise many question and it is frightening to the patient and family.

This case presents a 10 year old female patient with generalized gingival enlargement and mild hypertrichosis. There was no familial history. The child was mentally and physically healthy with no association of any syndromes. The gingival enlargement occurred with eruption of permanent teeth. There are cases which reported similar association in the past.¹⁻⁴

The eruption of teeth cause presence of gingival inflammation and thus it is called as eruption gingivitis. The presence of trauma during the eruption of teeth is considered to be the factor responsible for gingival enlargement. However, gingival enlargement to occur the gingival fibroblast should have a genetic predisposition. The presence of plaque is also considered a factor to induced gingival enlargement. Thus, there is still no clear

evidence to support the actual cause for gingival enlargement with the eruption of teeth.

CASE REPORT

A 10 year old girl reported to the Government Dental College and Hospital, Mumbai with the complaint of enlarged gingiva. On examination, the patient had incompetent lips and all the teeth were submerged deep into the gingiva (Figure 1). The gingival tissue appearance was of normal color of firm consistency with no evidence of inflammation. The patient was referred to the family physician who confirmed that child was mentally and physically healthy and not under any medication. The hematological profile of child was under normal limits with thyroid profile under marginally higher side.

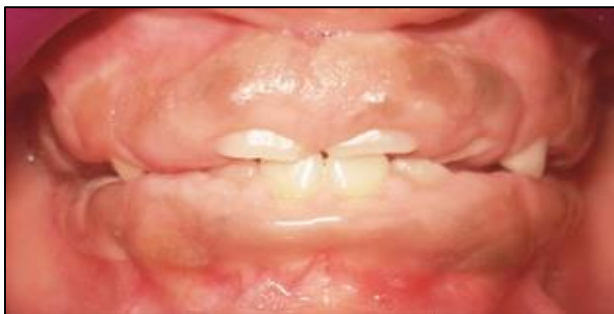

Figure 1: Pre-operative frontal view.

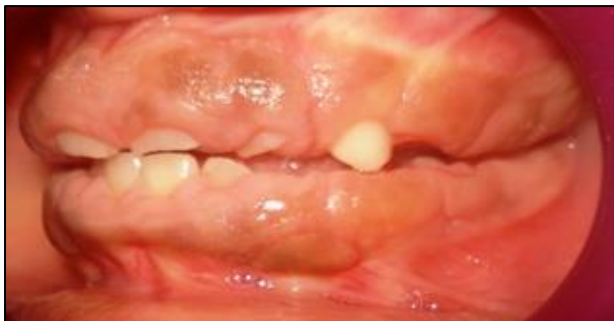

Figure 2: Pre-operative left lateral view.

Case management

The patient was evaluated in orthodontic department which confirmed normal skeletal growth. The patient was scheduled for incisional biopsy (Figure 3). The excised tissue was sent to pathology laboratory. The excised area was coagulated with diode laser to achieve hemostasis. On histopathologic examination, proliferative stratified squamous epithelium showed forking and arcing. The connective tissue showed dense collagen fiber bundles with numerous fibroblasts varying from plump to spindle shape (Figure 4). The patient was scheduled for gingivectomy procedure. Considering the non-hemorrhagic nature of the tissue, the gingivectomy was done by scalpel (Figure 5).

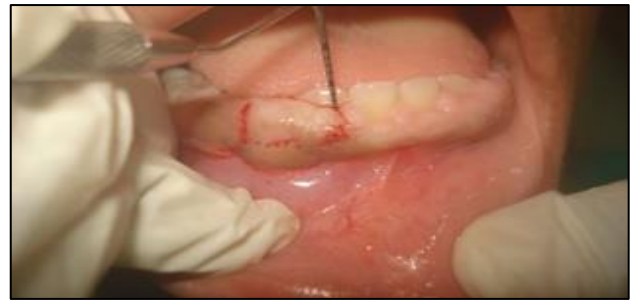

Figure 3: Excisional biopsy.

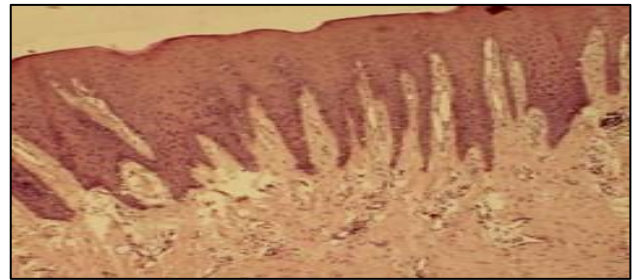


Figure 4: Histopathological picture.

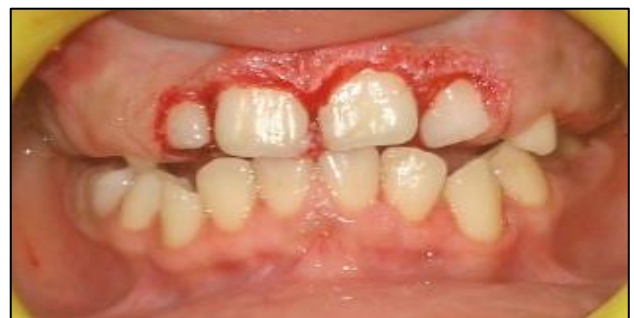

Figure 5: Gingivectomy performed.

Clinical outcome

There was evidence of coronal migration of gingival margin during healing of the tissue. However satisfactory tooth exposure was present during the recall visit of the patient (Figure 6 and Figure 7). The treatment procedure succeeded in establishing sufficient teeth exposure for mastication.

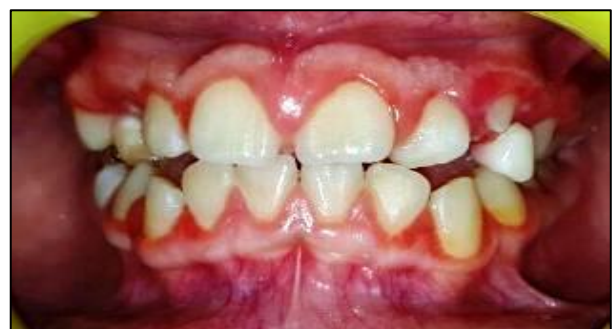

Figure 6: Post-operative frontal view.

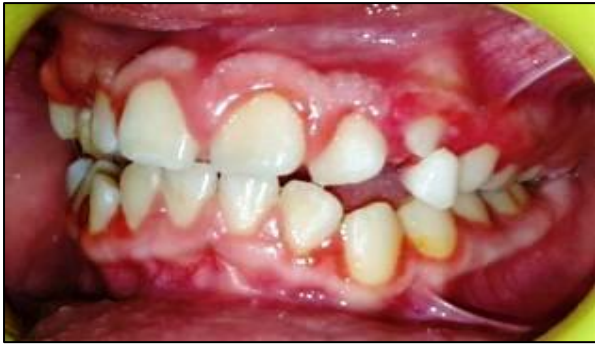

Figure 7: Post-operative left lateral view.

DISCUSSION

Gingivitis is a common occurrence in children due to the lack of importance and time given by children for maintaining the oral hygiene. However, gingival enlargement in children is not commonly found. Gingival enlargement in children can be localized or generalized. The gingival enlargement can be solely present or can be associated with some clinical manifestation.

Gingival enlargement is classified as⁵⁻⁷

- Isolated Hereditary GF
- Isolated Idiopathic GF
- GF with hypertrichosis
- GF with hypertrichosis and mental retardation and/or epilepsy
- GF with mental retardation and/or epilepsy
- GF associated with other diseases with formation of syndromes.

The syndromes associated with GF include

- Murray-Puretic Drescher syndrome (multiple hyaline fibromas)
- Rutherford's syndrome (corneal dystrophy)
- Laband syndrome (ear, nose, bone and nail defects with hepatosplenomegaly)
- Jones' syndrome (progressive deafness)
- Cross syndrome (microphthalmia, mental retardation, athetosis and hypopigmentation)
- Cornelia de Lange syndrome (primordial growth deficiency, severe mental retardation, anomalies of the extremities and a characteristic face)
- Ramon's syndrome (association with cherubism)
- A syndrome associated with hearing deficiencies, hypertelorism and supernumerary teeth
- Other associations include hypothyroidism, chondrodystrophia and diffuse osteofibromatosis (GF with osteofibrosis).

The patient reported with gingival enlargement with no one in family affected with this condition. The parents, grandparents and brothers of the patient were examined to find out any hereditary inheritance. This ruled out the

hereditary gingival enlargement. The patient was not under any drug therapy which was confirmed with the family physician. The child was mentally and physically normal and had adequate understanding suitable for that age. The oral examination revealed painless and non-inflammatory gingival enlargement. On the basis of clinical and histopathological examination a diagnosis of idiopathic gingival enlargement was made.

The child presented with mild hypertrichosis, however gingival enlargement is also associated with coarse hypertrichosis. Earlier case of 2 year old with excessive hair growth with gingival hyperplasia on the entire body has been reported in the past. The association between gingival enlargement and hypertrichosis is found to be very rare. It is considered as a genetic disorder with micro deletion on the 17q24.2–17q24.3 chromosome loci.^{8,9}

The time of treatment of gingival enlargement is debated. The early treatment will aid in eruption of teeth and maintaining proper occlusion. However, in mixed dentition period there is presence of deciduous teeth which might require proper judgment for extraction. Treating patients in early age before the eruption of permanent second molar should be taken into account. The relapse of gingival enlargement and the growth of the child should be closely monitored.

CONCLUSION

Gingival enlargement had been associated with eruption of permanent teeth. However, the reason behind its occurrence is not widely studied. The gingival enlargement in children with eruption of teeth should be investigated further. In order to prevent the initiation of gingival enlargement, the early phase of tooth eruption should be monitored. The parent and paediatrician should be aware of gingival enlargement as they play a vital role in the detection of this condition.

Funding: No funding sources

Conflict of interest: None declared

Ethical approval: Not required

REFERENCES

1. Gohil M, Padhiyar N, Gohil A. Idiopathic gingival fibromatosis. J Res Med Den Sci. 2013;1:23-6.
2. Kumar P, Sonowal S. Idiopathic gingival enlargement and its management. J Int Clin Dent Res Organ. 2015;7:146-50.
3. Shetty AK, Shah HJ, Patil MA, Jhota KN. Idiopathic gingival enlargement and its management. J Indian Soc Periodontol. 2010;14:263-5.
4. Siddeshappa ST, Deonani S, Nagdeve S, Yeltiwar RK. Whisking of ugly tissue. A surgical management of gingival fibromatosis in a 15-year-

- old girl: a rare case report. *Contemporary Clin Dent*. 2015;6(2):240-2.
5. Nayak P, Nayak U, Khandelwal V, Ninave N. Idiopathic gingival fibromatosis. *Int J Clinical Pediatric Dent*. 2011;4(1):77-81.
 6. Papachan B, Narayan J, Nayak A. Idiopathic gingival fibromatosis: a neglected case. *Indian J Radiol Imaging*. 2002;12:335-8.
 7. Doufexi A, Mina M, Ioannidou E. Gingival overgrowth in children: epidemiology, pathogenesis, and complications. A literature review. *J Periodontol*. 2005;76(1):3-10.
 8. Bubna AK, Veeraraghavan M, Anandan S, Rangarajan S. Congenital generalized hypertrichosis, gingival hyperplasia, a coarse facies with constriction bands: a rare association. *Int J Trichol*. 2015;7(2):67-71.
 9. Canún S, Guevara-Sanginés EG, Elvira-Morales A, Sierra-Romero Mdel C, Rodríguez-Asbun H. Hypertrichosis terminalis, gingival hyperplasia, and a characteristic face: a new distinct entity. *Am J Med Genet*. 2003;116:278-83.

Cite this article as: Attar NB, Gaikwad RP, Jugade SC, Banodkar AB, Sethna GD. Gingival enlargement in 10 years old: a case report. *Int J Contemp Pediatr* 2017;4:286-9.