

Original Research Article

Spectrum of magnetic resonance imaging abnormalities in neonatal seizures in a tertiary care hospital in India

Shafi Jan M. Shaik¹, Ezhilarasan Ratnavelu¹, Umamaheswari Balakrishnan^{1*},
Prakash Amboiram¹, Binu Ninan¹, Ashok Chandrasekharan¹,
Saravanan Ramaswamy¹, Rajeswaran Rangasami²

¹Department of Neonatology, ²Department of Radiology, Sri Ramachandra University, Porur, Chennai, India

Received: 22 August 2016

Revised: 25 August 2016

Accepted: 30 August 2016

*Correspondence:

Dr. Umamaheswari Balakrishnan,

E-mail: drumarajakumar@gmail.com

Copyright: © the author(s), publisher and licensee Medip Academy. This is an open-access article distributed under the terms of the Creative Commons Attribution Non-Commercial License, which permits unrestricted non-commercial use, distribution, and reproduction in any medium, provided the original work is properly cited.

ABSTRACT

Background: Seizure is the most common neurological presentation during the first month of life and can lead to adverse long term outcome. The aim of the study was to describe the spectrum of brain lesions identified by magnetic resonance imaging (MRI) in term babies presenting with neonatal seizures.

Methods: This retrospective descriptive study was done in a tertiary care hospital. The study subjects included term neonates presenting with neonatal seizures admitted in neonatal intensive care unit over a 5 year period, who underwent MRI brain. Data was collected from the medical records and radiology department.

Results: Out of 189 neonates presenting with seizures, 155 underwent MRI brain. Brain lesions were identified in 122 (79%) babies. The most common etiological diagnosis was hypoxic ischemic encephalopathy (HIE) which was noted in 43 (28%) neonates. The other findings in the decreasing order were encephalitis in 35 (23%), metabolic disorder in 16 (10%), haemorrhage in 15 (9.7%) vascular in 12 (8%) and cortical dysplasia in 1 (<1%) neonates.

Conclusions: MRI identified brain lesions in 79% of infants who presented with neonatal seizures. In accordance with the literature, our studies also revealed HIE as the commonest brain lesion. The diagnosis of neonatal stroke and encephalitis was made specifically with the aid of MRI. MRI showed changes consistent with diagnosis of encephalitis in a significant proportion of babies. We suggest that MRI should be considered as a standard investigation during the evaluation and management of neonatal seizures.

Keywords: Etiology, India, MRI abnormalities, Neonatal seizures, Term

INTRODUCTION

Seizure is the most common neurological presentation during the first month of life and can lead to adverse long term outcome.¹⁻⁴ A specific etiology for the seizure can be better detected in infants compared to children.⁵ However in 12-15% of newborns the etiology remains unknown.⁶⁻⁸ Magnetic resonance imaging (MRI) is a valuable tool for identifying structural abnormalities which may be the underlying etiology for neonatal

seizures and it is also more sensitive to detect subtle changes compared to neurosonogram or computed tomography.⁹ In developed countries, MRI of brain has become a standard investigation over a period of time but not yet in developing countries due to the lack of availability of equipment and expertise.^{7,10} MRI is not only helpful to detect the underlying brain etiology but also to prognosticate.¹¹

Data on MRI findings in neonatal seizures are sparse in developing countries. Hence the objective of this study is

to look at the spectrum of the brain lesions seen on MRI in term babies presenting with neonatal seizures.

METHODS

This retrospective descriptive study was undertaken after approval from Institutional Ethical Committee (IEC no-IEC-NI/15/AUG/48/48). The data was collected for the study period of 5 years (from January 1st, 2010 to December 31, 2014). The unique identification numbers of the babies who were diagnosed as neonatal seizures were retrieved from the medical records department using the ICD code P90. Among these babies whoever underwent MRI brain was included in the study. MRI reports were collected from the database of department of radiology. If reports were unavailable, they were excluded from the study.

The diagnosis of neonatal seizures was made by the duty neonatologist when the infants developed paroxysmal, sudden involuntary muscle contractions, abnormal tonic extensions or jerky movements with or without autonomic changes. EEG could not be done due to the limited availability of video EEG.

Neonates diagnosed with seizures were managed according to the unit protocol based on published guidelines.⁴ Infants who presented with neonatal seizures underwent MRI within 3-5 days once the condition stabilized. MRI was reported by a single senior radiologist with expertise in reporting neonatal MRI.

Neonates who underwent MRI were accompanied by a credentialed NICU doctor during the procedure. Oral choral hydrate and intranasal midazolam were used in selective cases where the images were distorted due to movement. General anaesthetics were not used in our study. All the images were obtained from a 1.5 T MRI scanner (Signa HDX, GE medical systems, Milwaukee) with a standard head coil.

The routine MR sequences obtained were axial and Sagittal spin echo T1 weighted images (TR/TE = 460/12; 4mm slice thickness / 1 mm gap), axial fast spin echo T2 weighted images (TR/TE = 5400/117: 4mm slice thickness/1mm gap), axial diffusion weighted images (TR/TE/b factor= 5075/84/1000) and gradient-echo (GRE) images (TR/TE/Flip angle = 700/30/30). MR angiography (MRA) and MR Venography (MRV) were done when there were changes suggestive of vascular events like hemorrhage and infarct.

Data on brain lesions seen on the MRI were collected. The findings in MRI were verified with the final diagnosis after clinico-radiological correlation by attending physician. The MRI findings were classified as hypoxic ischemic encephalopathy (HIE), infection, hemorrhage, metabolic, infarct and malformation.

The specific brain lesions

Hypoxic ischemic lesion when there were restricted diffusion involving the cortex or sub cortical white matter of bilateral frontal, parietal, temporal and right occipital lobes, corpus callosum, bilateral external capsule and the posterior limb of the internal capsule and in basal ganglia and thalamus. HIE findings were reclassified as BGT (basal ganglia thalamus) pattern, cortical and subcortical pattern and posterior limb of internal capsule (PLIC) pattern; encephalitis when areas of T2 flair hyper intensity with DWI restriction seen involving the entire corpus callosum, periventricular and subcortical white matter of the bilateral frontoparietal regions; hypoglycemic encephalopathy when there was abnormal signal intensities (T1 hypointense, T2 hyperintense) noted in bilateral occipital cortex regions and restricted diffusion in splenium of corpus callosum and no evidence of blooming on GRE; hemorrhage when there was T1/T2 hypointensity or hyperintensity with blooming effect in GRE sequence; Infarct when there was T1/T2 flair hyperintensity with DWI restriction noted in a specific region; multifactorial when there were more than one finding. When there were other findings, they were correlated with the clinical diagnosis.

Statistical analysis

Descriptive statistics were used for analysis of data. Categorical data were expressed as number and percentage.

RESULTS

During the 5 year period, there were a total 11362 admissions in the neonatal unit, out of which 189 (1.7%) term neonates presented with seizures. MRI of the brain was performed in 155 (82%) neonates. Specific brain lesions were seen in 122 (79%) babies (Table 1). The distribution of the various brain lesions are depicted in Figure 1. HIE is the most common lesion which accounted for 28% followed by CNS infection (23%).

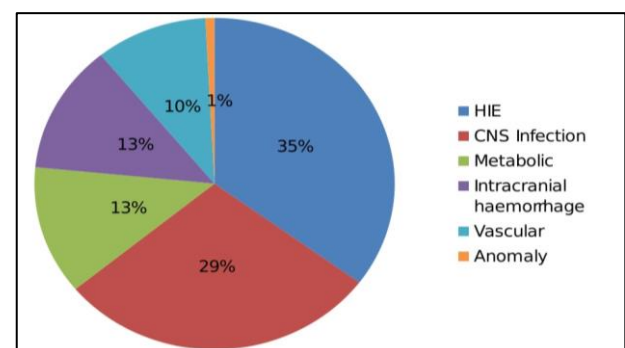


Figure 1: Distribution of various brain lesions.

Hypoxic ischaemic encephalopathy (HIE)

Out of 43 neonates with HIE, 30 (70%) had isolated HIE findings and 13 (30%) had other findings along with HIE changes. Isolated cortical and subcortical (Figure 2b, Figure 2c), posterior limb of internal capsule (PLIC) and basal ganglion and thalamus (BGT) patterns (Figure 2a) were noted in 16 (53.3%), 5 (16.7%) and 0 infants, respectively.

Table 1: Distribution of various brain lesions detected on MRI.

Type of lesion	Number (%)
Hypoxic ischemic encephalopathy (HIE)	43
HIE alone	30 (70)
HIE with other findings	13 (30)
Central nervous system infection	35
Encephalitis	33 (94)
TORCH	01 (3)
Multiple micro abscesses	01 (3)
Metabolic	16
Hypoglycemia	14 (88)
Propionic acidemia	01 (6)
Multiple carboxylase deficiency	01 (6)
Intracranial Hemorrhage	15
Parenchymal Haemorrhage	7 (47)
Intraventricular hemorrhage	5 (33)
Subdural and extradural haemorrhage	3 (20)
Vascular	12
Infarcts	09 (75)
Cystic changes (porencephalic cyst)	01 (8)
Vein of galen malformation	01 (8)
Superior Sagittal sinus thrombosis	01 (8)
Others (cortical dysplasia)	01

BGT patterns were found in association with PLIC and subcortical patterns in 7 (23.3%) infants. PLIC and cortical and subcortical patterns were noted in 2(6.7%) infants. HIE was associated with haemorrhage, infarcts and hypoglycemic changes in 6 (46%), 5 (39%) and 2(13%), respectively.

Central nervous system (CNS) infection

The spectrum of MRI abnormalities suggestive of CNS infection was encephalitis (Figure 2h) pattern (94%), TORCH infection (3%) and micro abscess (3%). The pattern of abnormality found in encephalitis was suggestive of parechoviral infection.

Metabolic causes

The characteristic features specific to hypoglycemia (Figure 2i) were found in 10% of the study cohort. Based

on the MRI findings, two babies were worked up and diagnosed to have propionic acidemia and multiple carboxylase deficiency.

Intracranial haemorrhage (ICH)

Bilateral intra parenchymal haemorrhage (Figure 2e) was seen in 3 (43%) infants. The common lobes affected were frontal and parietal lobes. Of the 5 babies with intraventricular haemorrhage (IVH), 3 had grade II IVH and 2 had grade III IVH with communication type of hydrocephalus. MRI has identified associated features such as subdural haemorrhage (Figure 2f), extradural haemorrhage (Figure 2g), posterior fossa haemorrhage; punctuate haemorrhages and cystic changes.

Vascular causes

MRI showing infarcts were classified as perinatal arterial ischemic stroke. Perinatal arterial ischaemic stroke (PAIS) (Figure 2d).

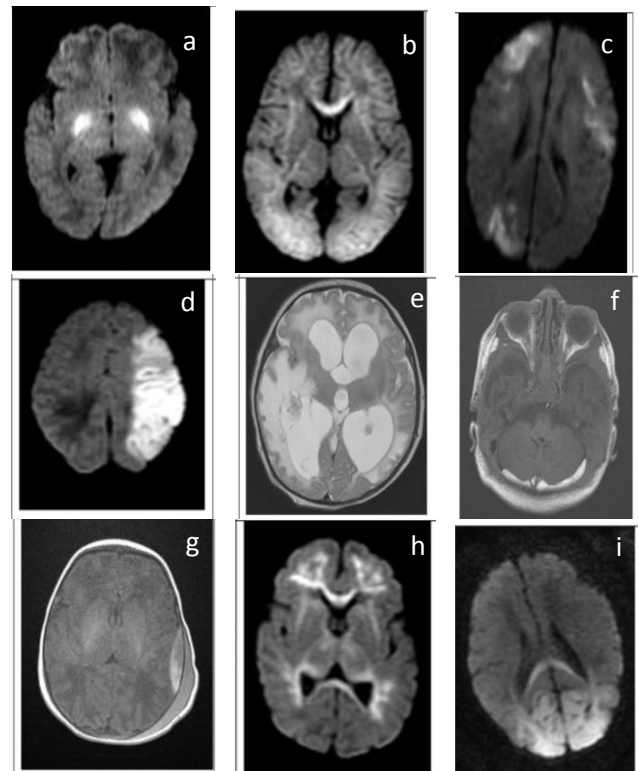


Figure 2: Various brain lesions; a) HIE-BGT pattern with PLIC, b) HIE- cortical and subcortical pattern, c) HIE- mild cortical subcortical pattern involving watershed areas, d) MCA territory infarct, e) Parenchymal haemorrhage, f) Subdural haemorrhage, g) Extradural haemorrhage, h) Viral encephalitis, i) Hypoglycemic MRI changes.

Among 9 (5.8%) babies who had PAIS, one had bilateral Middle cerebral artery (MCA) infarct and 6 had left MCA infarcts. Bilateral posterior cerebral artery and bilateral watershed infarcts were reported in one baby

each. MRI has also given additional information regarding the cerebral edema with midline shift, size of the infarct, second infarct on the contralateral side of MCA, subdural haemorrhages and punctate haemorrhages in the posterior fossa.

Porencephalic cyst was reported in 1 baby in the left frontoparietal lobe causing ex vacuo dilatation of left lateral ventricles and prominent sylvian fissure.

Other cerebral malformation

One baby was diagnosed with abnormal migration suggesting cortical dysplasia.

DISCUSSION

We observed an incidence of neonatal seizures in term infants to be 1.7% of the total neonatal unit admissions, which included both preterm and term infants, which is low compared to the reported incidence of 3.6% to 5.5%.^{12,13} According to International Vermont Oxford encephalopathy registry, 66% of infants presenting with encephalopathy underwent MRI.¹⁴ Other studies reported 30-82%.^{7,10,14} We could perform MRI on 82% of term infants with neonatal seizures. To the best of authors' knowledge, this is the largest series (155) of MRI done for evaluation of neonatal seizures in India. There are only few centers in India with MRI facility. In the year 2008, a survey in UK revealed that MRI brain had been performed in only 10% of the tertiary care neonatal units.¹⁵

In our study, majority (79%) of infants showed structural brain abnormalities in MRI which helped in identifying the underlying etiology for neonatal seizures. MRI abnormalities detected in decreasing order of frequency were HIE, encephalitis, metabolic, hemorrhagic and vascular lesions.

In the present study, HIE was the most common etiological diagnosis (28%) of neonatal seizures, and this conforms to the previous studies.^{3,7,13,16,17} Among the patterns of HIE, BGT pattern was observed less frequently and occurred only in association with PLIC pattern. As BGT pattern of injury is commonly seen following acute sentinel event, the occurrence of acute sentinel event could have been less in the cohort of babies in the present study.¹⁸ Cortical and subcortical pattern of injury is the most common HIE pattern in our study group, indicating involvement of watershed zones possibly secondary to partial prolonged asphyxia. Similar pattern could also occur in hypoglycemia. In the present study, HIE changes coexisted with hypoglycemia in 4% as reported earlier.¹³ None of the infants had severe involvement of cortical and subcortical white matter referred to as 'white cerebrum' which has been reported to be fatal.¹⁹ One third of the MRI showing HIE changes also had other associated findings such as hypoglycemia, infarct and hemorrhage. To point to the exact cause of

neonatal seizures becomes difficult, when there are multiple brain lesions which can independently cause seizures.

The second most common MRI abnormality reported in the present study was encephalitis (23%). None had bacterial meningitis. In literature, CNS infection as etiology was found in 3- 20%.^{7,9,16,20,21} Among the 35 neonates with CNS Infection, 33 had distinctive pattern of white matter involvement with extension into the subcortical white matter, corpus callosum, optic radiation or tracts suggestive of parechoviral encephalitis. This pattern had to be distinguished from MRI abnormality due to other viral etiology like HSV, as HSV encephalitis involve both white matter and grey matter.²² Confirmatory testing could not be done, as PCR for parechovirus was not available. MRI is a pertinent investigation in the diagnosis of encephalitis in neonates presenting with seizures, as CSF examination can be normal in viral encephalitis.²² Hence our study emphasizes the importance of MRI in the evaluation of neonatal seizures.

ICH occurred in 10% of infants which is comparable to 5-18% reported earlier.^{7,9,16,20,21} Intra-parenchymal bleed was the commonest and is a well-known cause for neonatal seizures. IVH was observed in 3% of infants presenting with neonatal seizures and may be an incidental finding.^{23,24}

The common cause for transient metabolic disorder with MRI abnormality was hypoglycemia (88%). The typical pattern involving the occipital region and splenium of corpus callosum has been the characteristic MRI change consistently observed in infants with hypoglycemic encephalopathy. Basal ganglia hyperintensity on MRI in one of our cases raised the possibility of either bilirubin encephalopathy or inborn errors of metabolism (IEM), which on further evaluation was found to be propionic acidemia. The other infant with suspected IEM, had MRI abnormality consistent with primary lactic acidosis which on evaluation turned out to be multiple carboxylase deficiency.

Perinatal arterial ischemic stroke occurred in 6% of the study cohort with majority occurring in unilateral MCA territory. MRI enables the diagnosis of stroke and without MRI these seizures might have been categorized as unknown etiology. This emphasizes the diagnostic utility of MRI in stroke. In the present study, performing MRV in all neonates presenting with seizures, helped us in confirming the diagnosis of cerebral venous sinus thrombosis (CVST). CVST formed only less than 1 percentage in the present study as against the reported 5-13% of occurrence as a chance finding in cranial ultrasound.^{25,26} We suggest performing MRA and MRV along with standard sequences in evaluation of neonatal seizures in order to detect vascular etiology.

In this study, MRI could also detect abnormalities such as cerebral dysgenesis, vein of galen malformation, porencephalic cyst, TORCH infection, and cerebral micro abscess.

In 33 (21%) babies, a known etiological cause for neonatal seizures could not be ascertained by MRI which is comparable to a study by Leth et al.⁸ Studies which included all the routine investigations could identify etiology in 88- 95%.²⁷ We could identify etiology for neonatal seizures in 79% based on MRI findings alone.

In summary, MRI identified brain lesions in 79% of infants who presented with neonatal seizures. In accordance with the literature, our study also revealed HIES as the commonest brain lesion among infants presenting with neonatal seizures. The diagnosis of neonatal stroke and encephalitis was made specifically with the aid of MRI. MRI showed changes consistent with diagnosis of encephalitis in a significant proportion of babies. Hence we suggest that MRI should be considered as a standard investigation during the evaluation of neonatal seizures.

ACKNOWLEDGEMENTS

We are highly obliged to the department of radiology for providing us the data and all the possible help during the study.

Funding: No funding sources

Conflict of interest: None declared

Ethical approval: The study was approved by the Institutional Ethics Committee

REFERENCES

1. Silverstein FS, Jensen FE. Neonatal seizures. *Ann Neurol*. 2007;62:112-20.
2. Clancy RR. Summary proceedings from neurology group on neonatal seizures. *Pediatrics*. 2006;117(3):23-7.
3. Talebian A, Jahangiri M, Masoudi AN, Akbari H, Sadat Z. The etiology and clinical evaluations of neonatal seizures in Kashan, Iran. *Iran J Child Neurol*. Spring. 2015;9(2):29-35.
4. Volpe JJ. Neonatal seizures. In: *Neurology of the Newborn*. Philadelphia, PA: WB Saunders. 2001:178-214.
5. Hallberg B, Blennow M. Investigations for neonatal seizures. *Semin Fetal Neonatal Med*. 2013;18:196-201.
6. Ronen GM, Buckley D, Penney S, Streiner DL. Long-term prognosis in children with neonatal seizures: a population-based study. *Neurology*. 2007;69:1816-22.
7. Tekgul H, Gauvreau K, Soul J, Murphy L, Robertson R. Stewart outcome of seizures in term newborn infants. *Pediatrics*. 2006;117:1270-80.
8. Leth H, Toft PB, Herning M, Peitersen B, Lou HC. Neonatal seizures associated with cerebral lesions shown by magnetic resonance imaging. *Archives Disease Childhood*. 1997;105-10.
9. Weeke LC, Groenendaal F, Toet MC, Benders MJ, Nivelstein RA, Rooij LG, et al. The aetiology of neonatal seizures and the diagnostic contribution of neonatal cerebral magnetic resonance imaging. *Dev Med Child Neurol*. 2015;57(3):248-56.
10. Garfinkle J, Shevell MI. Prognostic factors and development of a scoring system for outcome of neonatal seizures in term infants. *Eur J Paediatr Neurol*. 2011;15:222-9.
11. Ravindran M, Amborium P, Umamaheswari B, Ramani G, Ninan B. Does diffusion restriction changes in magnetic resonance imaging predict neurological outcome in neonatal seizures? *J Pediatr Neurosci*. 2015;10(4):326-30.
12. Afsaneh S, Maryam D. Neonatal seizures in a rural Iranian district hospital: etiologies, incidence and predicting factors. *Acta Medica Iranica*. 2012;50(11):760-4.
13. Anand V, Pilli SK, Jayakrishnan D, Nair PMC. Neonatal seizures: our experience of incidence, etiology and outcome in a tertiary care centre. *Indian J Child Health*. 2014;1(2):39-43.
14. Pfister RH, Bingham P, Edwards EM, Horbar JD, Kenny MJ, Inder T, et al. The Vermont Oxford Neonatal Encephalopathy Registry: rationale, methods, and initial results. *BMC Pediatr*. 2012;12:84.
15. Tsakmakis M, Tooley J. Managing seizures in the neonatal period is there a UK consensus? *Arch Dis Child Fetal Neonatal Ed*. 2008;93:21-5.
16. Yıldız EP, Tatlı B, Ekici B, Eraslan E, Aydın N, Çalışkan M, Özmen M. Evaluation of etiologic and prognostic factors in neonatal convulsion. *Pediatr Neurol*. 2012;47(3):186-92.
17. Loman AM, Horst HJ, Lambrechtsen FA, Lunsing RJ. Neonatal seizures: aetiology by means of a standardized work-up. *Eur J Paediatr Neurol*. 2014;18(3):360-7.
18. Weeke LC, Van Rooij LG, Toet MC, Groenendaal F, de Vries LS. Neuroimaging in neonatal seizures. *Epileptic Disord*. 2015;17(1):1-11.
19. Vermeulen RJ, Fetter WP, Hendriks L, Schie PE, Knaap MS, Barkhof F. Diffusion-weighted MRI in severe neonatal hypoxic ischaemia: the white cerebrum. *Neuropediatrics*. 2003;34(2):72-6.
20. Ronen GM, Buckley D, Penney S, Streiner DL. Long-term prognosis in children with neonatal seizures: a population-based study. *Neurology*. 2007;69:1816-22.
21. Mastrangelo M, Lierde AV, Bray M, Pastorino G, Marini A, Mosca F. Epileptic seizures, epilepsy and epileptic syndromes in newborns: a nosological approach to 94 new cases by the 2001 proposed diagnostics scheme for people with epileptic seizures and with epilepsy. *Seizure*. 2005;14:304-11.

22. Verboon-Maciolek MA, Groenendaal F, Hahn CD. Human parechovirus causes encephalitis with white matter injury in neonates. *Ann Neurol*. 2008;64:266-73.
23. Brouwer AJ, Groenendaal F, Koopman C, Nievelstein RJ, Han SK, Vries LS. Intracranial hemorrhage in full-term newborns: a hospital-based cohort study. *Neuroradiology*. 2010;52(6):567-76.
24. Whitby EH, Griffiths PD, Rutter S, Smith MF, Sprigg A, Ohadike P, et al. Frequency and natural history of subdural haemorrhages in babies and relation to obstetric factors. *Lancet*. 2004;363(9412):846-51.
25. Kersbergen KJ, Groenendaal F, Benders MJ, Vries LS. Neonatal cerebral sinovenous thrombosis: neuroimaging and long-term follow-up. *J Child Neurol*. 2011;26:1111-20.
26. Berfelo FJ, Kersbergen KJ, Ommen CH. Neonatal cerebral sinovenous thrombosis from symptom to outcome. *Stroke*. 2010;41:1382-8.
27. Osmond E, Billetope A. Neonatal seizures: magnetic resonance imaging adds value in the diagnosis and prediction of neurodisability. *Acta Paediatrica*. 2014;103:820-6.

Cite this article as: Shafi Jan MS, Ratnavelu E, Balakrishnan U, Amboiram P, Ninan B, Chandrasekharan A, et al. Spectrum of magnetic resonance imaging abnormalities in neonatal seizures in a tertiary care hospital in India. *Int J Contemp Pediatr* 2016;3:1150-5